



# International Journal of Medical Research & Health Sciences

[www.ijmrhs.com](http://www.ijmrhs.com) Volume 2 Issue 3 July - Sep Coden: IJMRHS Copyright ©2013 ISSN: 2319-5886

Received: 10<sup>th</sup> May 2013

Revised: 11<sup>th</sup> Jun 2013

Accepted: 14<sup>th</sup> Jun 2013

Research article

## ANATOMICAL STUDY OF SACRAL HIATUS FOR SUCCESSFUL CAUDAL EPIDURAL BLOCK

\*Ramamurthi KS<sup>1</sup>, Anil kumar Reddy Y<sup>2</sup>

<sup>1</sup> Assistant professor, <sup>2</sup>Tutor, Department of Anatomy, KFMS&R, Coimbatore, Tamilnadu, India.

\*Corresponding author email: kumarlucky48@gmail.com

### ABSTRACT

**Background:** Present study determined the landmarks for caudal epidural block (CEB) after morphometric measurements of the sacral hiatus on dry sacral bones. The CEB has been widely used procedure for the diagnosis and treatment of lumbar spinal disorders. Anatomical features of the sacral hiatus and the detailed knowledge about sacral hiatus. **Materials & Methods:** 116 sacral bones are used for the study. Anatomical measurements were measured by using vernier caliper accuracy to 0.1 mm. **Results:** Agenesis of sacral hiatus was detected in two sacral bones. Various shapes of sacral hiatus were observed which included inverted U (31%), inverted V (25.8%), irregular (20.6%), Elongated (17.2%) and dumbbell (5%). Apex of sacral hiatus was commonly found at the level of 4<sup>th</sup> sacral vertebra in 50.8%. The distance between the two supero lateral sacral crests and the distance between the apex of sacral hiatus and the right and left supero lateral crests were 69.5 (5.8) mm, 61.4 (11.2) mm, 57.4 (9.7) mm respectively, on average. The mean, mode, SD is calculated for all the measurements. **Conclusion:** The sacral hiatus has anatomic variations. Understanding of these variations may improve the reliability of CEB.

**Keywords:** Sacral vertebrae, Sacral hiatus, Caudal Epidural Block (CEB)

### INTRODUCTION

The incomplete fusion of the posterior elements of the 5<sup>th</sup> or 4<sup>th</sup> sacral vertebra, results in the formation of sacral hiatus<sup>1</sup>. This inverted U shaped sacral hiatus is covered by the sacrococcygeal membrane and forms an important landmark to perform caudal epidural block (CEB)<sup>2</sup>. Sacral hiatus has been widely utilized for administration of epidural anesthesia in obstetrics and surgery below the umbilicus such as Hernia repair, Lower limb surgery, Skin

grafting, GU procedures, procedures on the anus and rectum, orthopedic surgery on the pelvic girdle<sup>3</sup>. The success rate CEB is depends on anatomic variations of sacral hiatus as observed by various authors.

### MATERIALS AND METHODS

The present study was conducted in the department of anatomy, Karpagam Faculty of Medical Sciences & Research, Coimbatore,

Tamilnadu. 116 complete and undamaged adult Caucasian dry sacral bones obtained from the department of anatomy and department of Forensic medicine. The sex and age of the sacral bones were not known. Anatomical

measurements were performed on these specimens by using a vernier caliper (accuracy 0.1mm). Each sacrum was studied and below mentioned measurements was taken from each sacrum.

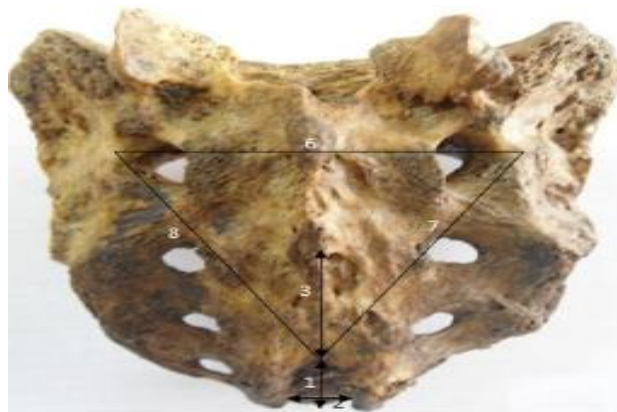


Fig 1: Morphometric measurements of sacrum

1. Length of sacral hiatus (mm)
2. Width of sacral hiatus (sacral cornua) (mm)
3. Distance from apex to the level of S<sub>2</sub> foramina (mm)
4. Distance from base to s2 foramina (1+3) (mm)
5. Depth of SH at the level of its apex (mm)
6. Distance between two superior lateral sacral crest (mm)
7. Distance between right superior lateral sacral crest & apex (mm)
8. Distance between left superior lateral sacral crest & apex (mm)

## RESULTS

Agnesis of the sacral hiatus was found in two sacrum's. Various shapes of sacral hiatus are observed, inverted U (31%) shaped sacral hiatus is most commonly observed (Table-1) (Fig-3). The level of the apex of the sacral hiatus in

relation to sacral vertebra is observed and percentages are given in Table – 2. The level of the base of the sacral hiatus in relation to sacral/coccygeal vertebra is observed and percentages are given in Table-3.

**Table.1:** Shape of Sacral hiatus (n=116)

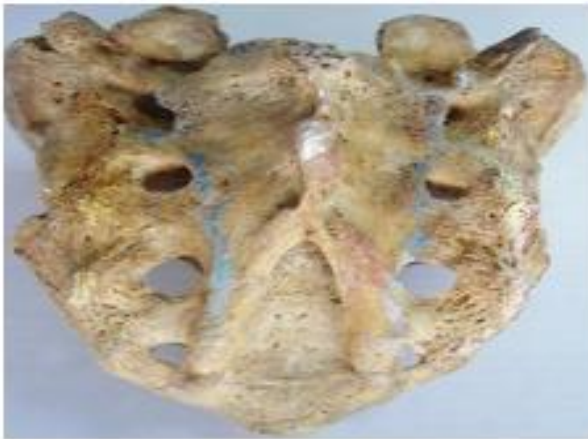| S.No | Shape      | No. | Percentage% |
|------|------------|-----|-------------|
| 1    | Inverted U | 36  | 31%         |
| 2    | Inverted V | 30  | 25.8%       |
| 3    | Irregular  | 24  | 20.6%       |
| 4    | Elongated  | 20  | 17.2%       |
| 5    | Dumbbell   | 6   | 5%          |

**Table.2:** Location of apex in relation to level of sacral vertebra (n=116)

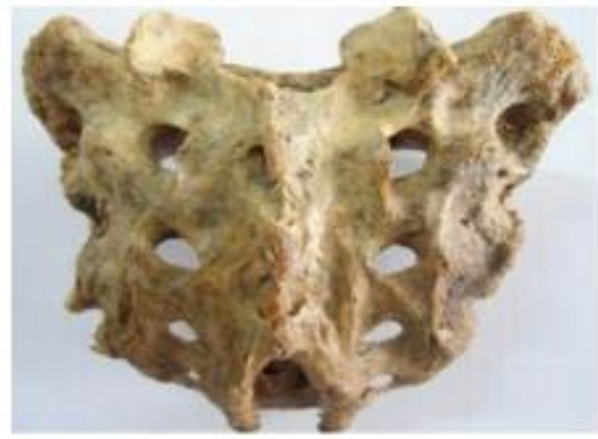| S.No | Location of Apex                | No. | Percentage% |
|------|---------------------------------|-----|-------------|
| 1    | 4 <sup>th</sup> sacral vertebra | 59  | 50.8%       |
| 2    | 3 <sup>th</sup> sacral vertebra | 48  | 41.3%       |
| 3    | 2 <sup>th</sup> sacral vertebra | 09  | 7.7%        |

**Table.3:** Location of base of hiatus in relation to level of sacral/coccygeal vertebra (n=116)

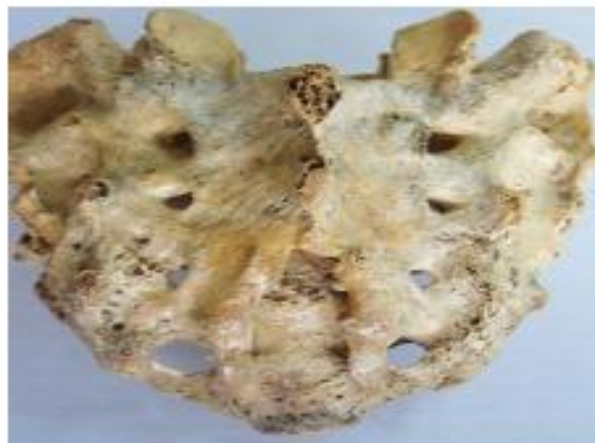| S.No | Location of Base                | No. | Percentage% |
|------|---------------------------------|-----|-------------|
| 1    | 5 <sup>th</sup> sacral vertebra | 84  | 72.4%       |
| 2    | 4 <sup>th</sup> sacral vertebra | 22  | 18.9%       |
| 3    | Coccyx                          | 10  | 8.6%        |



**Fig. 2:** inverted V shaped sacral hiatus



**Fig.3:** Inverted U shaped sacral hiatus



**Fig.4:** Irregular shaped sacral hiatus

The average length of sacral hiatus was 29.5(9.5) mm (range 17-49mm). The length of sacral hiatus mostly between 17-30 mm. The average width of sacral hiatus (sacral cornua) was 16.2 (2.7) mm (range 10-22 mm). The distance between the right superio lateral sacral crest and the sacral apex was 61.4(11.2) mm (range 36-88 mm). The distance between the left superio

lateral sacral crest and the sacral apex was 57.4(9.7) mm (range 35-73 mm). From the above mean values, it is important to know that the distance from the right and left sacral crests to the hiatus were similar in each sacrum. The anatomical measurements and statistical data are given in Table-4.

**Table.4:** Morphometry of sacrum

|  | Mean | Median | SD   | Max | Min |
|--|------|--------|------|-----|-----|
| Length of sacral hiatus (mm)                                   | 29.5 | 24     | 9.5  | 49  | 17  |
| Width of sacral hiatus (sacral cornua) (mm)                    | 16.2 | 13     | 27   | 22  | 10  |
| Distance from apex to the level of s2 foramina (mm)            | 30.2 | 27     | 10.5 | 53  | 12  |
| Distance from base to s2 foramina (1+3) (mm)                   | 59.5 | 51     | 8.8  | 74  | 42  |
| Depth of SH at the level of its apex (mm)                      | 05   | 07     | 1.4  | 07  | 02  |
| Distance between two supero lateral sacral crest (mm)          | 69.5 | 67     | 5.8  | 86  | 59  |
| Distance between right supero lateral sacral crest & apex (mm) | 61.4 | 58     | 11.2 | 88  | 36  |
| Distance between left supero lateral sacral crest & apex (mm)  | 57.4 | 57     | 9.7  | 73  | 35  |

## DISCUSSION

Study on the anthropometric measurements of sacral hiatus and its anatomical features are related to its clinical application in caudal epidural anaesthesia. Standard textbooks (peter L. William et al, 2000)<sup>4</sup> mentions the lower end of sacral canal is an arch shaped sacral hiatus. Many authors have been mentioned various shapes of sacral hiatus (vinod kumar et al 1995, Trotter et al 1946)<sup>5 6</sup>, most common being inverted V and inverted U. in the present study also the shapes of sacral hiatus were variable, most common inverted U (31%) and inverted V (25.8%). In 5% its outline was like a dumbbell while in 20.6% it was irregular.

In the present study complete agenesis of dorsal bony wall of sacral canal is observed in 1.7%. This is similar to that previous workers namely Trotter et al<sup>7</sup> (1947) 1.8% and vinod kumar et al (1992) 1.4%. The apex of sacral hiatus was seen most commonly (50.8%) at the level of 4<sup>th</sup> sacral vertebra. Standard textbooks (peter L. William et al 2000) states that the apex of sacral hiatus present at level of 4<sup>th</sup> sacral vertebra. Sekiguchi M et al<sup>8</sup> (2002) noted the apex of sacral hiatus at S4 level in 64% cases. Most of the authors including the present study noted that location of apex can vary from upper end of S2 to lower part of S5.

The base of sacral hiatus was seen at level of S5 vertebra in 72.4% sacra, similar to various authors namely vinod kumar et al (1992, 83.17%) and Nagar SK<sup>9</sup> (72.6%). It extended to coccyx in 8.6% cases. These sacra had coccygeal ankylosis.

Identification of the caudal epidural space is not always possible even for experienced clinicians, and anatomical variation may be an influence. The apex of the sacral hiatus is an important bony landmark in the success of CEB but it may be hard to palpate, particularly in obese patients. Hence other prominent anatomical landmark may be of use, such as the triangle formed between the posterior superior iliac spines and the apex of sacral hiatus. Present study measurements show this to be an equilateral triangle<sup>10</sup>. The given measurements are useful to identify the sacral hiatus easily and increase the success rate of CEB.

The length of sacral hiatus varied from 17-49mm average is 29.5(9.5). Sekiguchi and Colleagues found the distance between the sacral cornua (10.2 (0.35) (2.2-18.4 mm) lesser than and the depth of sacral hiatus (6.0 (1.9) (1.9-11.4) mm) slightly greater than those measurements in our study (16.2 (2.7) (10-22) and 5 (1.4) (2-7) mm respectively). The depth of sacral hiatus at apex is important as it should be sufficiently large to

accommodate the needle. In the present study the depth ranged from 2-7mm with mean of 5(1.4) mm. mean depth reported by various authors are similar (Trotter et al, Lanier et al, Trotter et al and Sekiguchi et al) to present study. The distance between the S2 foramen and the apex of the sacral hiatus was 30.2 (10.5) mm on average (range 12-53mm). The study by senoglu et al<sup>11</sup> and patil dhananjay<sup>12</sup> is similar to our studies. Additional measurements are distance between two supero lateral sacral crest (base of the triangle) (69.5 (5.8) 59-86mm), distance between right supero lateral sacral crest and sacral hiatus apex (61.4 (11.2) 36-88mm), distance between left supero lateral sacral crest and sacral hiatus apex (57.4 (9.7) 35-73mm) forming nearly an equilateral triangle between supero lateral sacral crest and sacral hiatus apex in most of the sacrums. This equilateral triangle can act as guide to the location of the apex of sacral hiatus during caudal epidural block and clinicians can avoid problem of failure in needle placement. Our study is similar to the studies by Anjali Aggarwal et al and patil dhananjay.

## CONCLUSION

In the present study, elongated, dumbbell shaped hiatus and narrow space of the sacral canal at apex of sacral hiatus was found in a significant percentage. The Anatomical study of sacral hiatus and knowing about anatomical variations of sacral hiatus is significant while administration of caudal epidural anaesthesia and measurements of sacral hiatus may improve its success rate.

## REFERENCES

1. Standring S (Ed). Gray's Anatomy. The Anatomical Basis of Clinical practice. Philadelphia, Elsevier Churchill Livingstone 2005.
2. Senoglu N, Senoglu M, Oksuz H, Gumusalan Y, Yuksel KZ, Zencirci Bet al., Landmarks

- of the sacral hiatus for caudal epidural block: an anatomical study. British journal of Anaesthesia 2005; 95 (5): 692-95.
3. Patil Dhannajay S, Jadav Hrishikesh R, Binodkumar, Mehta CD, Patel Vipul D. Anatomical study of Sacral Hiatus for Caudal Epidural Block. National Journal of Medical Research. Sept 2012;2(3) 1-6
4. Peter L William et al. Gray's anatomy 38<sup>th</sup> edition. Churchill Livingstone 2000;592-31, 673-74
5. Vinod kumar, Pandey SN, Bajpai RN, Jain PN, Longia GS. Morphometrical study of sacral hiatus. Journal of Anatomical Society of India 1992;41 (1):7-13.
6. Trotter M, Letterman GS. Variations of the female sacrum; their significance in continuous caudal analgesia. Surg. Gynaecol. Obstet. 1944;78(4):419 – 24.
7. Trotter M. Variations of the sacral canal; Their significance in the administration of caudal analgesia. Anesthesia and analgesia 1947; 26 (5); 192-202.
8. Sekiguchi M, Yabuki S, Saton K, Kikuchi S. An anatomical study of the sacral hiatus: a basis for successful caudal epidural bloc. Clin. J. Pain. 2004;20(1): 51-54.
9. Nagar SK. A study of sacral hiatus in dry human sacra. Journal of Anatomical Society of India 2004;53(2) 18-21.
10. Stitz MY, Sommer HM. Accuracy of blind versus fluoroscopically guided epidural injection. Spine 1999;24(13): 1371-76.
11. Senoglu N, Senoglu M, Oksuzl H, Gumusalan Y, Yuksel KZ, Zencirci B et al., Landmarks of the sacral hiatus for caudal epidural block; an anatomical study. British journal of Anaesthesia, September 2005; 53:1-4.
12. Anjali Aggarwal, Harjeet kaur, Yatindra K. Batra, Aditya K., Subramanyam Rajeev and Daisy Sahni, Anatomic Consideration of Caudal Epidural Space: A cadaver study. Clinical Anatomy.2009;22:730-37.