



International Journal of Medical Research & Health Sciences

www.ijmrhs.com Volume 2 Issue 3 July - Sep Coden: IJMRHS Copyright ©2013 ISSN: 2319-5886

Received: 3rd Apr 2013

Revised: 23rd Apr 2013

Accepted: 1st May 2013

Case report

STRONGYLOIDES STERCORALIS HYPERINFECTION IN AN IATROGENICALLY IMMUNOSUPPRESSED PATIENT: A CASE REPORT

Shafiq Syed¹, Ramathilakam B², Prakash, Geetha³, Devipriya G⁴

¹DM Resident, ²Professor and HOD, Department of Medical Gastroenterology,

³Professor and HOD, ⁴Postgraduate student, Department of Pathology, Meenakshi Medical College and Research Institute, Enathur, Kanchipuram

*Corresponding author email: syed.dr.s@gmail.com

ABSTRACT

We report a case of *Strongyloides stercoralis* infection of the stomach in an elderly male patient who was on corticosteroids for six months. The patient presented with epigastric pain associated loss of appetite and loss of weight. The patient underwent upper endoscopy, and his gastric antral biopsy showed superficial ulcerations of the gastric mucosa with adult worms of *Strongyloides stercoralis* in the crypts of the gastric antrum. Stool sample showed the larval forms of *Strongyloides*. The patient was treated with Ivermectin in a dose of 200µg/kg/day PO for two days, same treatment was repeated after two weeks. Prednisone was tapered and stopped.

Keywords: *Strongyloides stercoralis*, ivermectin, prednisone

INTRODUCTION

Strongyloides stercoralis is an intestinal nematode endemic in tropical and subtropical countries of Asia and Africa. It is estimated that 30 to 100 million people worldwide are infected with *Strongyloides stercoralis*.¹⁻³ It remains as an asymptomatic infection in a majority of those infected with it but is capable of producing hyperinfection with dissemination throughout the body when the host immunity is compromised. The *Strongyloides* life cycle is unique and more complex than that of other nematodes with its alternation between free-living and parasitic cycles and its potential for autoinfection and multiplication within the host. Hyperinfection or

disseminated infection occurs usually in immunocompromised patients, most often in patients on corticosteroid treatment. The diagnosis is based on a high index of suspicion – a diagnosis of *Strongyloides* can be made for certain by identifying the worm in stool samples. Eosinophilia can be helpful but it is most often absent in patients with disseminated disease. Ivermectin is a highly effective drug against strongyloidosis, but eradication of the worm is difficult to ascertain based on stool examination alone. Thiabendazole and albendazole are the other alternative drugs.

CASE REPORT

A 62 year old male patient was being seen in the department of Dermatology for eczema since two years. He was referred to Medical Gastroenterology for complaints of epigastric pain associated with loss of appetite since 3 months along and loss of weight with early satiety. According to the patient and his attenders, he had lost 6 Kgs over the last 3 months. There was no history of fever or cough. He denied melena or hematochezia. No history of altered bowel habits. No history of passing worms in stool.

The patient was on oral prednisone therapy on and off, and most recently he has been on steroids therapy for as long as six months for his skin condition, prescribed by his dermatologist. On examination, vital signs were normal. There was no pallor, clubbing, or palpable lymphadenopathy. Systemic examination was likewise normal except for skin showing some

dry scaly lesions, mainly over his extremities and neck.

His labs showed a Hb of 13.0 gm%, TC of 11,700 cells/cubic mm with differential showing eosinophils of 7%. HIV testing was negative. His random sugar was 75 mg/dl.

Patient was subjected to upper GI scopy which showed antral gastritis with duodenitis. Antral biopsies were taken and submitted for HPE. The pathology specimen was reported as gastric mucosa showing superficial ulcerations and adult worms of *Strongyloides stercoralis* were seen within the gastric crypts.

Patient's stool was sent for ova and parasite, and it showed rhabditiform larvae of *Strongyloides stercoralis*. The patient was treated with a course of ivermectin in a dose of 200 mcg/kg/day orally for 2 days, and this was repeated after 14 days. The patient's prednisone was tapered and stopped.

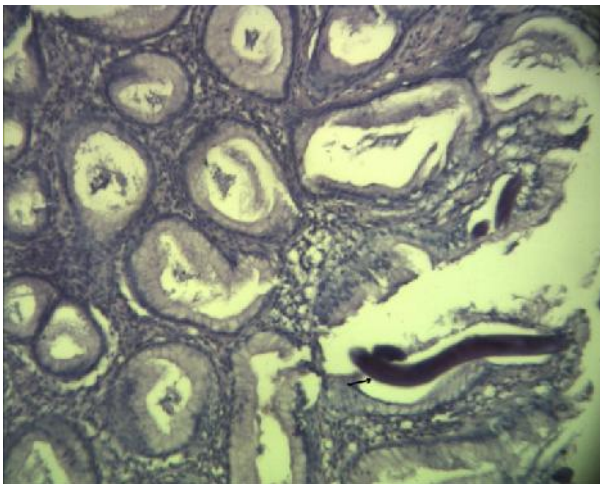


Fig.1: Gastric antral biopsy showing adult *Strongyloides stercoralis* worm in the gastric crypts

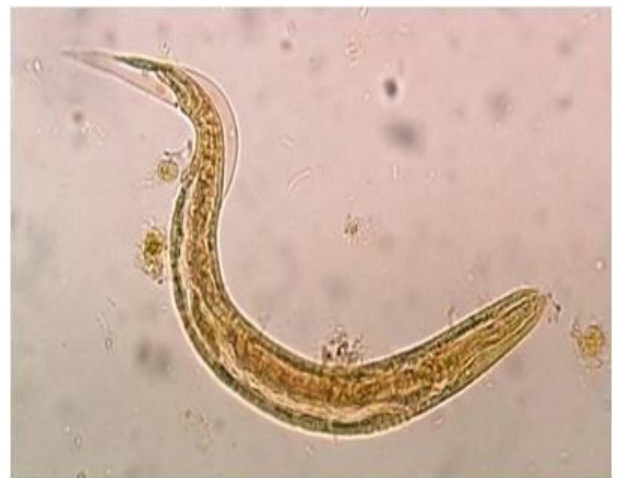

Fig.2: Stool specimen showing rhabditiform larva of *Strongyloides stercoralis*

DISCUSSION

Strongyloides stercoralis is a free-living nematode endemic in tropical and subtropical countries infecting more than 100 million people worldwide.¹ A distinctive feature of this parasite is its ability to persist and replicate within a host for decades producing minimal or no symptoms but being capable of causing life-threatening

infection by way of hyperinfection or dissemination in an immunocompromised host with a mortality rate as high as 80%.²

The life cycle of *Strongyloides stercoralis* is rather complex and unique among the intestinal nematodes. It has two types of life cycles - a free-living life cycle (rhabditiform larvae) and a

parasitic life cycle (filariform infective larvae) - with 3 developmental stages: adult, rhabditiform larva, and filariform larva.

The free-living life cycle allows for development of nonparasitic adults, both males and females, in the soil, which can indefinitely maintain infestation of the soil.

The second type of life cycle, which is the parasitic cycle, allows noninfective larvae to molt in the human host into infective filariform larvae. These infective larvae then penetrate the intestine and set up a new cycle, the hyperinfective or autoinfective cycle. Unlike other intestinal nematodes infecting humans, these larvae can increase in numbers without reinfection from outside.

The clinical manifestations of *Strongyloides* infection depends on the burden of worm infection and the host immune response. Majority of the infected patients remain asymptomatic and are only discovered as a serendipitous incidental finding. Risk factors for dissemination include patients who have suppressed cell mediated immunity with patients on high-dose corticosteroids and those infected with HTLV-I being the highest risk groups.^{3,4} It is postulated that corticosteroids act directly to promote development of infective filariform larvae. Fulminant infection can complicate patient with HIV and AIDS. The other at risk groups being patients who are on immunosuppressive drug therapy, patients with hematologic malignancies, renal and bone marrow transplant recipients.

Diagnosis is made with certainty by the presence of larva in the stool. Peripheral eosinophilia is found in half of those infected but is usually absent in hyperinfection. Patients with increased peripheral eosinophilia appear to have a better prognosis.⁵ There are several methods to identify larvae in stool with Baermann funnel technique being regarded at the gold standard. Other methods used for diagnosis are duodenal aspiration, immunodiagnostic tests (viz., IFA, IHA, ELISA, etc.), direct smear of feces in

saline-lugol iodine stain, and the use of these diagnostic tests depends on the local availability of resources and expertise.

Strongyloides infection can be successfully treated with ivermectin which is the drug of choice.^{6,7} Thiabendazole and albendazole can also be used as alternatives.⁸ A single dose of ivermectin 200 mcg/Kg body weight/day orally for two days is the drug of choice in uncomplicated strongyloidosis. This dose can be repeated after two weeks. Tribendimidine is an investigational drug showing promise in the treatment of strongyloidiasis.⁹ Patients with hyperinfection or dissemination are at risk of sepsis and meningitis with gram-negative organisms and hence also require a broad spectrum antibiotic along with the above antihelminthic treatment.

The diagnosis of strongyloidiasis requires the clinicians to have a high index of suspicion as patients with the infection present with no distinctive clinical features, and the laboratory, imaging, and endoscopic findings are often nonspecific. Immunocompromised patients are at high risk of dissemination with high mortality, and there have been multiple reports of fatal outcomes in patients being treated with steroids¹⁰ Hence the need of identifying patients at risk for strongyloidosis and performing appropriate diagnostic tests before beginning immunosuppressive therapy is of utmost importance.

REFERENCES

1. Albonico M, Crompton DWT, and Savioli L. Control strategies for human intestinal nematode infections. *Advances in Parasitology*. 1998;42:277–341
2. Asdamongkol N, Pornsuriyasak P, Sungkanuparph S. Risk factors for strongyloidiasis hyperinfection and clinical outcomes. *Southeast Asian J Trop Med Public Health*. Sep 2006;37(5):875-84

3. Fardet L, Généreau T, Poirot JL, Guidet B, Kettaneh A, Cabane J. Severe strongyloidiasis in corticosteroid-treated patients: case series and literature review. *J Infect.* Jan 2007;54(1):18-27.
4. Neefe LI, Pinilla O, Garagusi VF, and Bauer H. Disseminated strongyloidiasis with cerebral involvement: a complication of corticosteroid therapy. *The American Journal of Medicine.* 1973; 55(6): 832–38
5. Jamil SA and Hilton E. The *Strongyloides* hyperinfection syndrome. *N. Y. St. J. Med.* 1992; 92:67–68.
6. Gann PH, Neva FA, and Gam AA. A randomized trial of single and two-dose ivermectin versus thiabendazole for treatment of strongyloidiasis. *J. Infect. Dis.* 1994;169:1076–79.
7. Guzzo CA, Furtek CI, Porras AG. Safety, tolerability, and pharmacokinetics of escalating high doses of ivermectin in healthy adult subjects. *The Journal of Clinical Pharmacology.* 2002;42(10): 1122–33.
8. Datry A, Hilmarsdottir I, Mayorga-Sagastume R, Lyagoubi M, Gaxotte P, Biligui S, et al. Treatment of *Strongyloides stercoralis* infection with ivermectin compared with albendazole: results of an open study of 60 cases. *Trans R Soc Trop Med Hyg.* 1994;88(3):344-45.
9. Steinmann P, Zhou XN, Du ZW, Jiang JY, Xiao SH, Wu ZX, et al. Tribendimidine and albendazole for treating soil-transmitted helminths, *Strongyloides stercoralis* and *Taenia* spp: open-label randomized trial. *PLoS Negl Trop Dis.* 2008;2(10):322
10. Boulware DR, Stauffer WM, Hendel-Paterson BR, Rocha JL, Seet RC, Summer AP. Maltreatment of *Strongyloides* infection: case series and worldwide physicians-in-training survey. *Am J Med.* Jun 2007;120(6):545-8