

“Proliferating Trichilemmal Tumour : An interesting tumour case Report.”

*Dr Vinod V Prabhu , Dr . Aslam Shivani

Department of surgery, Bharati Medical College, Sangli. Maharashtra.

*Corresponding author: E- Mail : cghert@yahoo.co.in

Abstract: Proliferating Trichilemmal tumour (PTT) is a tumour arising from the head and neck region of elderly women. It was first described in 1966 by Wilson and Jones as 'proliferating epidermoid cyst'. It is a benign tumour that appears as a malignant tumour but histologically more often turns to be benign. Worldwide very few malignant PTT have been reported. It is a tumour which is often proved benign after histopathological exam. Features of malignant tumour include non-scalp locations, size >5 cm, recent rapid increase in size, infiltrative growth pattern on histology, palpable lymph nodes, fixity to deeper structures.

Keywords : trichilemmal, tumour, scalp PTT.

Background:

PTT is an interesting tumour that is usually seen in elderly females usually in the scalp. It presents as a proliferative cauliflower like growth over the scalp mimicking squamous cell carcinoma. PTT shows features of typical pilar cyst, but additionally exhibits extensive epithelial proliferation, with variable cytological atypia and mitotic activity. It is a tumour that presents as a large mass which makes a diagnosis of malignancy inevitable (Fig 1).

This case presented as a large tumour about 15 cms on left frontal region of scalp which was not fixed to frontal bone. This tumour was small in size to begin with and attained the present size in two years. Considering the slow nature of growth a provisional diagnosis of benign tumour was made and wide local excision done. Histology confirmed benign nature.

Case report : A sixty five year old female presented with a 15*15 cms tumour over the frontal area of scalp on left side. The tumour had a narrow base with no induration in skin surrounding the tumour. It was not fixed to frontal bone. No lymph nodes were palpable. It was foul smelling. The tumour did not

bleed on touch.

Considering the slow nature of the growth a wide local excision and primary skin grafting was done. The histopathology revealed tumour composed of clusters of well differentiated squamous cells exhibiting abrupt keratinization (Fig 2). A benign proliferating trichilemmal tumour was diagnosed.

Discussion: Trichilemmal (pilar) cysts are common skin lesions that usually occur on the scalp of elderly women. It is suspected to arise due to a complication of trauma and inflammation^[1], They differentiate towards the follicular outer root sheath epithelium and show trichilemmal keratinization. The progression of the cysts to PTT is a slow progression. As the oncological transformation of trichilemmal tumour occurs, Saida et al. defined three stages^[2], the adenomatous stage (trichilemmal cyst); the epitheliomatous stage (proliferating trichilemmal cyst); the carcinomatous stage (malignant PTT). Malignant transformation to squamous cell carcinoma or spindle cell carcinoma is a rare phenomenon. In addition to histological criteria like presence of a high mitotic rate, atypical mitosis, severe nuclear pleomorphism, and tumor invasion of the adjacent

tissues which are the essential histological features of malignancy, diagnosis of malignant PTT is done in tumours showing a combination of non-scalp location, recent rapid infiltrative growth, size greater than 5 cm^[3]. Loss of CD34 immunoreactivity is an important feature of potential malignant nature, though of limited value^[4]. In this case there was no loss of CD 34 immunoreactivity.

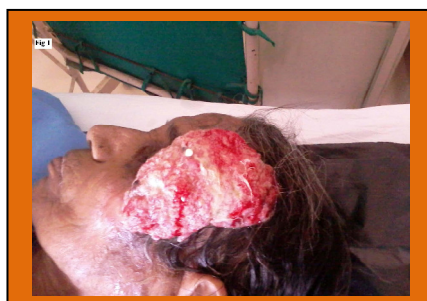The nucleolar organizer regions (NORs) have been used as an effective tool to assess progression and the degree of cell proliferation. The nucleolar count fairly predicted the behavior of tumours^[5]. One dot per nucleus in pilar cysts to 1.5-2 in benign pilar tumors. NORs in pilar tumors with atypia was 2.8, which was more than the benign pilar tumors but was definitely less than the malignant pilar tumors which was 3.5. Treatment entails surgery as the mainstay with wide local excision^[6] with or without reconstruction. In present case a wide local excision with skin grafting was done. Moh's surgery is preferable if facilities for the same are available.

Conflict of Interest: Nil

Acknowledgement: The authors are greatly indebted to Dr Sabera Tamboli and Dr Agashe, Department of Pathology who have helped us in getting good histological photographs and legends for the same.

Legends:

Fig 1 : Tumour on left frontal region..



References:

- 1) M H Brownstein, D J Arluk. Proliferating trichilemmal cyst: a simulant of squamous cell carcinoma. *Cancer* 10/1981; 48(5):1207-14.
- 2) Ilker Sengul ,Demet Sengul Posttraumatic proliferating trichilemmal tumour on the frontal region of the scalp: a case report. *Cases J.* 2010; 3: 80. doi: 10.1186/1757-1626-3-80 PMID: PMC2856536.
- 3) Folpe AL, Reisenauer AK, Mentzel T, Rütten A, Solomon AR. Proliferating trichilemmal tumors: clinicopathologic evaluation is a guide to biologic behavior. *J Cutan Pathol.* 2003 Sep;30(8):492-8.
- 4) Herrero J, Monteagudo C, Ruiz A, Llombart-Bosch A. Malignant proliferating trichilemmal tumours: an histopathological and immunohistochemical study of three cases with DNA ploidy and morphometric evaluation. *Histopathology.* 1998 Dec;33(6):542-6.
- 5) Shet T, Modi C. Nucleolar organizer regions (NORs) in simple and proliferating trichilemmal cysts (pilar cysts and pilar tumors). *Indian Journal of Pathology & Microbiology* [2004, 47(4):469-473]
- 6) Sethi S, Singh UR. Proliferating trichilemmal cyst: report of two cases, one benign and the other malignant. *J Dermatol.* 2002 Apr;29(4):214-20.

Fig 2 : Variable sized lobules surrounded by a vitreous layer and show palisading of the peripheral cell layer. Epithelium in the center of lobules show abrupt keratinization. (low power 10X).

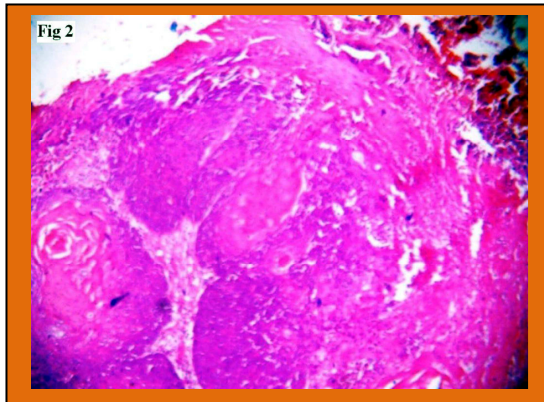
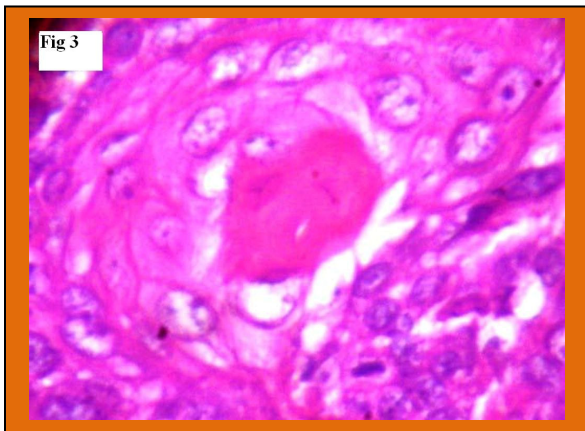


Fig 3 : Abrupt keratinization in the center of lobules without keratohyaline granules. Some degree of nuclear atypia of epithelial cells is noted. (high power40X) .



Date of Submission: 18 December 2012
Date of Provisional acceptance: 08 January 2013
Date of Final acceptance: 16 February 2013
Date of Publication: 05 March 2013
Source of Support: Nil Conflict of Interest: Nil