

Case Report:

Xanthogranulomatous oophoritis : Case Report

¹Date Shilpa* , ² Sulhyan Kalpana, ³ Badge Sachin , ⁴ Gosavi Alka , ⁵Ramteerthkar N.

¹Department of OBGY & ²⁻⁵ Department of Pathology, G.M.C. Miraj, Maharashtra, India

*Correspondence Mail: shrinkale@yahoo.co.in

Abstract:

Background: Xanthogranulomatous inflammation of female genital tract is extremely rare entity. Very few cases have been documented in literature.

Case Reporting : We presented a case of xanthogranulomatous affection of ovary in eighteen year girl youngest documented in literature without getting exposed to all known predisposing factors like pelvic inflammatory disease(PID), leiomyoma, endometriosis, intrauterine contraceptive devices(IUCD). Her clinical examination, radiological evaluation, tumor markers, surgical findings as well as microscopic picture was likely to get confused with malignancy if we would have missed xanthogranulomatous inflammation as one of differential diagnosis.

Conclusion: Xanthogranulomatous oophoritis should be discussed in detail as it is not a well-known pathology and likely to get confused with malignancy, especially while treating ovarian tumors.

Key words: Xanthogranulomatous inflammation, Xanthogranulomatous oophoritis, female genital tract

Introduction :

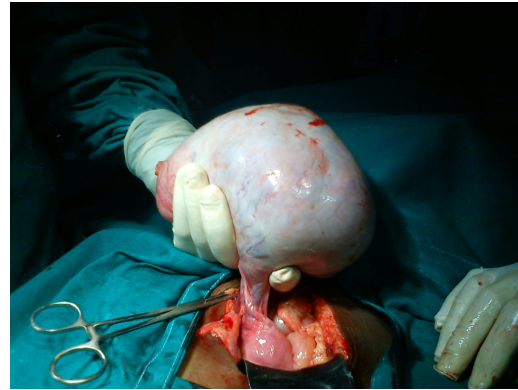Xanthogranulomatous inflammation is an uncommon, non-neoplastic, chronic process that is destructive to the normal tissue of the affected organs. It is characterized by the presence of a large number of lipid-containing macrophages with an admixture of lymphocytes, plasma cells and neutrophils ^[1, 2]. Most commonly affected organ is kidney followed by that the gall bladder ^[3, 4]. Other organs in which xanthogranulomatous inflammation has been reported are stomach, anorectal area, bone, urinary bladder, testis and epididymis. Female genital tract involvement is rare and is mostly confined to the endometrium; however, involvement of the vagina, cervix, fallopian tube and ovary has been

documented ^[1, 5-12]. Only a few cases involving the ovary have been reported up to date ^[5-12].

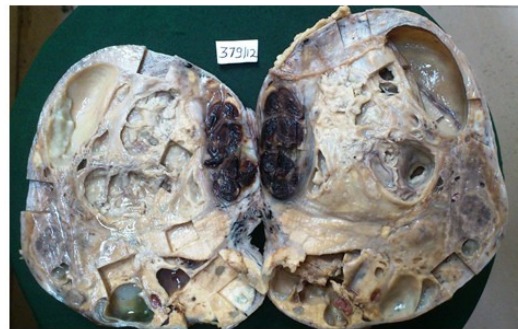
Case report :

18 year old newly married girl presented with pain in abdomen and fever since one week. On per abdominal examination there was a well defined mass with mixed consistency of 18 x 15 cm arising from the pelvis occupying whole of lower and mid abdomen more on right side and extending up to the right hypochondriac region. Pelvic ultrasound revealed large solid ovarian mass with necrotic areas and no free fluid in abdomen. A computerized tomography scan of the abdomen showed a large heterogeneous right ovarian mass with normal left ovary, no free fluid, no omental deposits or lymphadenopathy. All hematological investigations

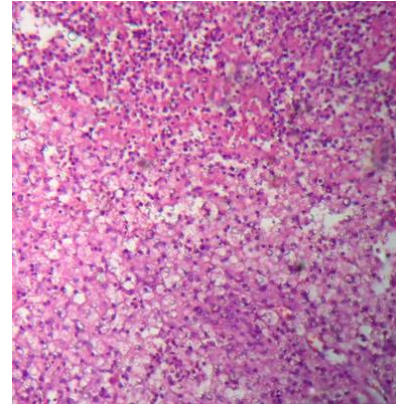
including tumor markers were done. Hematological investigations showed Hemoglobin - 9.5Gm% , Total Leucocyte Count -7500/mm³ with Polymorphs 80%, Lymphocytes 20% and Platelet count of 160,000/mm³ and ESR - 20mm/hr. Renal function test, liver function test, urine routine and microscopy were within normal limits. CA125 level was slightly raised (68.01U/ml). Patient was posted for exploratory laparotomy. During surgery we came across right ovarian complex mass of 17x15x5 cms (Photograph 1) with normal left ovary. There was no ascites, omental deposits or liver involvement. Right salphingo-oophorectomy was done. The specimen was sent for histopathological examination. Grossly, the external surface was smooth and cut section showed multiple cystic and solid areas. Cysts varied from 0.5 to 2.5 cm in size and contained yellowish serous fluid, mucoid material and blood clots. Solid areas showed yellowish appearance and areas of necrosis (Photograph 2). Microscopic examination revealed diffuse and dense infiltration of ovarian tissue by sheets of foamy histiocytes, lymphocytes, plasma cells and polymorphs (Photograph 3). Multiple micro abscesses with extensive areas of hemorrhagic and infarctoid necrosis, collections of hemosiderophages, dilated lymphatics, congested and thrombosed blood vessels and areas of marked fibrosis separated by hyalinised stroma were noted. Special stains like Acid fast stain, PAS and GMNS stain were negative for microorganisms. Diagnosis of xanthogranulomatous oophoritis was confirmed. Postoperative course was uneventful. Patient was discharged on seventh postoperative day.



Photograph 1



Photograph 2



Photograph 3

Discussion :

Kunakemakorn was the first to describe xanthogranulomatous inflammation of serosa of uterus, left fallopian tube and ovary in his report of inflammatory pseudotumor in the pelvis in 1976 [13]. To date, very few cases of xanthogranulomatous

oophoritis have been reported [14-22]. The etiopathogenesis of xanthogranulomatous oophoritis is not yet clear. Many theories have been proposed, such as theory of infection, leiomyoma, endometriosis, use of IUCD, inefficient or inappropriate drugs (antibiotics) and abnormalities of lipid metabolism etc [23]. The most accepted theory is of infection, which is supported by clinical evidence of infection and growth of bacteria such as *Escherichia coli*, *Bacteroides fragilis*, *Proteus vulgaris*, and *Salmonella typhi* from the affected tissue by culture [16]. Singh UR et al described xanthogranulomatous oophoritis as a complication of typhoid [19].

The average age is 38.5 years (range 23-72) and the youngest case reported was of 18 years [22]. The clinical presentations include fever, abdominal mass, pain in the abdomen, menorrhagia, anemia and anorexia. Gynecological examination reveals adnexal mass with tenderness. Laboratory tests show elevated ESR and raised white blood cell count [23]. Radiological findings of xanthogranulomatous oophoritis may simulate malignant ovarian neoplasm. Contrast-enhanced CT shows complex solid-cystic lesions with thick enhancing walls and variably enhancing solid intramural nodules. Solid intramural nodules appear hypo intense on T1 weighted MRI or may appear T1 hyper intense, and may show enhancing solid areas [24, 25].

Grossly the affected ovary is usually enlarged and the size varies from 3-17 cm [14-22]. Ovary is replaced by tumor like solid yellow, nodular mass that occasionally is cystic due to liquefactive necrosis. The inflammation may extend beyond the ovary and

involves the neighboring organs as well as adjacent pelvic peritoneum resulting in adhesions [21]. Thus these features may arouse the suspicion of malignancy. Microscopically the lesion is characterized by lipid laden histiocytes. The proliferation of foamy histiocytes and fibrous organization of the chronic inflammatory process are responsible for the pseudotumoral appearance on gross examination [21]. Differential diagnosis includes both non-neoplastic and neoplastic conditions. Non-neoplastic conditions include infections like tuberculosis and fungal infections which can be ruled out by performing special stains. In malakoplakia, the cytoplasmic concentric calcific bodies (Michaelis-Gutmann bodies) are found which were not seen in our case. Neoplastic conditions include lymphoma or leukemia, malignant small cell tumor and sclerosing stromal tumor. Thus clinically, radiologically and pathologically xanthogranulomatous oophoritis can be confused with ovarian malignancy.

Treatment of choice for xanthogranulomatous oophoritis is oophorectomy. Antibiotic therapy has been attempted but it has not succeeded in reducing ovarian mass [13].

Conclusion:

Patients with PID, endometriosis, leiomyomas and IUCD etc. should be followed up because of their close association with xanthogranulomatous oophoritis. Xanthogranulomatous oophoritis should be kept in mind while dealing with cases of ovarian tumors to prevent misdiagnosis of malignancy and to avoid radical surgeries.

Acknowledgements:

Special thanks to Dr Shriniketan Kale, Mch (surgical oncology) for guidance and expert advice in making of manuscript and review work.

References:

1. Davis M, Whitley ME, Haque AK, Fenoglio-Preiser C, Waterman R. Xanthogranulomatous abscess of a mullerian duct remnant: a rare lesion of the rectum and anus. *Dis Colon Rectum*. 1986; 29: 755–759.
2. Franco V, Florena AM, Guarneri G, Gargano G. Xanthogranulomatous salpingitis: case report and review of the literature. *Acta Eur Fertil*. 1990; 21: 197–199.
3. Mittal B V, Badhe B P. Xanthogranulomatous pyelonephritis—(a clinicopathological study of 15 cases): *Journal of Postgraduate Medicine*. 1989; 35(4): 209–214.
4. Guzmán G-Valdivia. Xanthogranulomatous cholecystitis: 15 years' experience. *World Journal of Surgery*. 2004; 28 (3): 254–257.
5. Guarino M, Reale D, Micoli G, Tricomi P, Cristofori E. Xanthogranulomatous gastritis: association with xanthogranulomatous cholecystitis. *J Clin Pathol*. 1993; 46: 88–90.
6. Cozzutto C. Xanthogranulomatous osteomyelitis. *Arch Pathol Lab Med*. 1984; 108: 973–976.
7. Usamentiaga E, Val-Bernal JF, Alonso-Bartolome P, Lopez-Rasines G, del Valle JI, Calabia A. Xanthogranulomatous orchitis. *Urology*. 1998; 52: 891–892.
8. Wiener LB, Riehl PA, Baum N. Xanthogranulomatous epididymitis: a case report. *J Urol*. 1987; 138: 621–622.
9. Russack V, Lammers RJ. Xanthogranulomatous endometritis: report of six cases and a proposed mechanism of development. *Arch Pathol Lab Med*. 1990; 114: 929–932.
10. Pace EH, Voet RL, Melancon JT. Xanthogranulomatous oophoritis: an inflammatory pseudotumor of the ovary. *Int J Gynecol Pathol*. 1984; 3: 398–402.
11. Ladefoged C, Lorentzen M. Xanthogranulomatous inflammation of the female genital tract. *Histopathology*. 1988; 13: 541–551.
12. Strate SM, Taylor WE, Forney PJ, Silva FD. Xanthogranulomatous pseudotumor of the vagina: evidence of a local response to an unusual bacterium (mucoid *Escherichia coli*). *Am J Clin Pathol*. 1983; 79: 637–643.
13. Kunakemakorn P, Ontai H. Pelvic inflammatory pseudotumor: A case report. *Am J Obstet Gynecol*. 1976; 26: 286–287.
14. Shalev E, Zuckerman H, Rizescu I. Pelvic inflammatory pseudotumor (Xanthogranuloma). *Acta Obstet Gynecol Scand*. 1982; 61: 285–286.
15. Ladetoged C, Loretzen M. Xanthogranulomatous inflammation of the female genital tract. *Histopathology*. 1988; 13: 541–551.
16. Gray Y, Libbey NP. Xanthogranulomatous salpingitis and oophoritis: A case report and review of the literature. *Arch Pathol Lab Med*. 2001; 125: 260–263.
17. Maheshkumar U, Potekar RM, Yelikar BR, Pankaj Pande. Xanthogranulomatous oophoritis masquerading as ovarian neoplasm. *ajphs* 2012: 308–309.

18. Shailaja Shukla, Mukta Pujani, Sanjeet Kumar Singh, Meenu Pujani. Xanthogranulomatous oophoritis associated with primary infertility and endometriosis. *Indian J Pathol Microbiol.*2010; 53 (1): 197-8.
19. Singh UR, Revathi G, Gita R. Xanthogranulomatous oophoritis: an unusual complication of typhoid. *J Obstet Gynaecol (Tokyo 1995).* 1995 Oct; 21(5): 433-6.
20. Punia RS, Aggarwal R, Amanjit, Mohan H. Xanthogranulomatous oophoritis and salpingitis: late sequelae of inadequately treated staphylococcal PID. *Indian J Pathol Microbiol.* 2003 Jan; 46(1): 80-1.
21. Naik M, Madiwale C, Vaideeswar P. Xanthogranulomatous oophoritis--a case report. *Indian J Pathol Microbiol.* 1999 Jan; 42(1): 89-91.
22. Hemalatha AL, Rao S, Deepak KB, Gayathri MN, Manjunath BS, Rathna S. Xanthogranulomatous salpingo-oophoritis: a rare entity at an exceptional site. *Indian J Pathol Microbiol.* 2007 Jul; 50(3): 607-9.
23. Zhang XS, Dong HY, Zhang LL, Desouki MM, Zhao C. Xanthogranulomatous Inflammation of the Female Genital Tract: Report of Three Cases. *J Cancer.* 2012; 3: 100-106.
24. Jung SE, Lee JM, Lee KY, Han KT, Hahn ST. Xanthogranulomatous oophoritis: MR imaging findings with pathologic correlation. *AJR Am J Roentgenol.* 2002; 178: 749–51.
25. Kim SH, Yang DM, Kim KA. Unusual causes of tuboovarian abscess: CT and MR imaging findings. *Radiographics.* 2004; 24: 1575–89.

Date of submission: 23 February 2013

Date of Provisional acceptance: 17 March 2013

Date of Final acceptance: 28 April 2013

Date of Publication: 03 June 2013

Source of Support: Nil ; Conflict of Interest: Nil