

## PARASPINAL MUSCLE ABSCESS DUE TO METHICILLIN-RESISTANT STAPHYLOCOCCUS AUREUS (MRSA) IN A PATIENT WITH CHRONIC RENAL FAILURE

### KRONİK BÖBREK YETMEZLİKLİ BİR HASTADA METİSİLİN DİRENÇLİ STAPHYLOCOCCUS AUREUS (MRSA) İNFEKSİYONUNA BAĞLI PARASPİNAL KAS ABSESİ

Caner Çavdar , Tuğba Gün , Sait Naderi , Yavuz Yeniçerioğlu , Rifki Ersoy , Taner Çamsan\*

Department of Nephrology, Dokuz Eylül University, İZMİR  
Department of Neurosurgery, Dokuz Eylül University , İZMİR

#### ABSTRACT

*A patient with diabetic nephropathy admitted with complaints of fever and severe back pain. Lumbar computerized tomography and magnetic resonance imaging disclosed paraspinal muscle abscess. Inoculation of the aspirate yielded growth of methicillin-resistant Staphylococcus aureus. Therapy involved surgical evacuation and appropriate antibiotic resulted in a favorable outcome.*

*Because of suppressed immune system, patients with chronic renal failure and diabetes are susceptible to infections. Pyomyositis is a primary infection of skeletal muscle that rapidly leads to abscess formation. Staphylococcus aureus is the most common pathogen. Pyomyositis is relatively uncommon in temperate climates. In temperate climates it is seen especially in immunocompromised patients.*

*Here we report a case of paraspinal pyomyositis with abscess formation in an immunocompromised patient demonstrating typical aspects of diagnosis and treatment.*

**Key words:** Paraspinal muscle abscess, chronic renal failure, diabetes mellitus, paraspinal pyomyositis

#### Introduction

Infectious complications are common causes of morbidity and mortality in patients with both chronic renal failure (CRF) and diabetes.

Well-known abnormalities of cellular and humoral immunity contribute to the increased susceptibility to the serious infections in these patients. *S. aureus*, being a member of flora, is generally located in the mucous membranes of anterior nasopharynx. Whereas the

#### ÖZET

*Diabetik nefropatili bir hasta ateş ve bel ağrısı yakınmalarıyla başvurdu. Lumbar bilgisayarlı tomografi ve magnetic rezonans görüntüleme ile paraspinal kas apsesi saptandı. Aspirasyon materyalinde metisilin dirençli Staphylococcus aureus üredi. Cerrahi yöntemle apse boşaltıldı. Hasta uygun antibiyotik ile başarılı bir şekilde tedavi edildi.*

*Kronik böbrek yetmezliği ve diabet hastaları baskılanmış bağışıklık sistemi nedeniyle infeksiyonlara daha duyarlıdır. Pyomyozit, iskelet kasının primer infeksiyonudur. Hızlı bir şekilde apse oluşumuna yol açar. En sık etkeni Staphylococcus aureus'tur. Pyomyozit ılıman iklimlerde nadiren görülür. Bu hastalık ılıman iklimlerde özellikle immün yetmezlikli hastalarda ortaya çıkar.*

*Burada immün yetmezlikli bir hastada apse oluşumu ile seyreden paraspinal pyomyozit olgusu sunuyoruz.*

**Anahtar kelimeler:** Paraspinal kas apsesi, kronik böbrek yetmezliği, diabetes mellitus, paraspinal pyomyozitis

axillae, the vaginae, the perineum, and occasionally the gastrointestinal tract are the other habitation sites for the microorganism (1).

*Staphylococci* can not break through intact epithelial surfaces in general. Disruption or dysfunction of epithelial-mucosal barriers facilitates the invasion of the bacteria. It is known that mucosal barriers in CRF patients is defective and give rise to decreased resistance to bacterial invasion. Following invasion of

*Staphylococci* through mucosal or epithelial barriers, the host's immune response normally eliminates the microorganism preventing from infection. However, in case of disturbed immune system as in CRF, invading microorganisms might escape from immune surveillance and cause serious infections of skin and soft tissue, respiratory tract, central nervous system, urinary tract, musculoskeletal and endovascular structures (2).

Here, we report a case of paraspinal muscle abscess due to *S. aureus* in CRF patients with diabetes.

### Case

A 40-year-old male with diabetic nephropathy (creatinine clearance: 15 mL/min) for five years was admitted with complaints of fever, backache, and left leg pain. On physical examination, palpation of the area over the 4th lumbar vertebrae was painful. Apart from restricted straight leg raising (<70 degrees) on the left, his neurological examination was within normal limits. On admission, his axillary fever was 38.5 °C. In laboratory examinations, blood cell count (WBC) was 29,000<sup>^</sup>L with neutrophilic predominance, erythrocyte sedimentation rate (ESR) was found as 134 mm/ hr. Blood, urine, and throat inoculations were sterile. Chest X-ray was normal. Superficial ultrasonography (USG) of lower back revealed hypoechoic heterogeneous area on the left side, 50 x 30 x 25 mm in dimensions with distinct boundary. Lumbar computerized tomography (CT) disclosed asymmetry of paravertebral muscles (**Fig. 1A**). On magnetic resonance imaging (MRI), left paraspinal muscle was highly edematous and was increased in volume with necrotic areas inside (**Fig. 1B**). With a preliminary diagnosis of abscess, fine needle aspiration was performed yielding purulent aspirate. On microscopic examination, gram-positive coccus and 15-20 leukocytes were observed in each high power field. **Ziehl-Neelsen** staining was negative for **acidoresistant** bacilli. Inoculations of the aspirate disclosed growth of methicillin-resistant *Staphylococcus aureus* (MRSA). Whereas anaerobic inoculations and **Lowenstein-Jensen** inoculation for 6 weeks for mycobacteria did not yield any growth. On diagnosis, he was begun on vancomycin treatment immediately and the treatment is carried out for 2 weeks; meanwhile paraspinal muscle abscess extending to the neural foramen was evacuated surgically. Postoperative MRI showed the postoperative changes and resolution of paraspinal abscess (**Fig. 2**). Following treatment, his fever and pain diminished within days and he improved clinically. His WBC count and ESR decreased to normal limits.

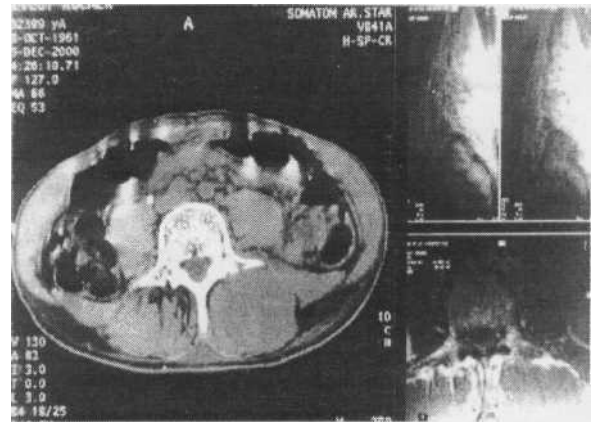


Fig. 1A. Lumbar computerized tomography showing asymmetry of paravertebral muscles. Fig. 1B. Lumbar MR imaging shows the paraspinal edematous mass extending to neural foramen.

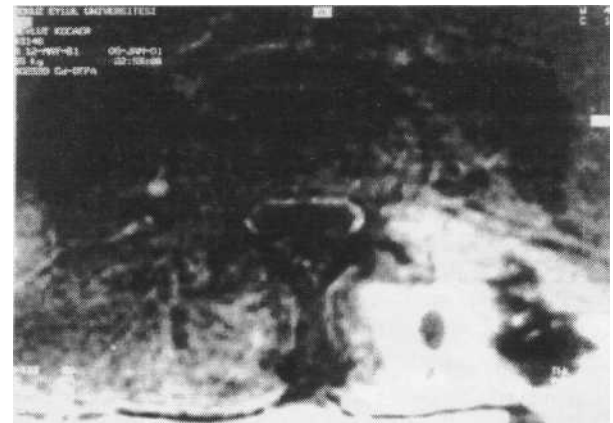

Fig. 2: Postoperative MR images shows postoperative changes.

### DISCUSSION

The paraspinal muscle is seeded by either hematogenously or direct extension from the infectious focus of vertebrae (3).

In the present case, there was no contagious spread of the infection. Bone survey, CT and MRI of lumbar vertebrae failed to document any finding compatible with osteomyelitis or other local destructive vertebral lesion.

Local injection, penetrating wounds and trauma may cause paraspinal muscle infection by direct contamination (4, 5). Herein, there was no history of local injection, trauma, foreign body or wound history.

So, after elimination the probability of contagious spread, we searched for the hematogenous spread that

might cause abscess formation in the paraspinal muscle. Blood cultures performed regarding hematogenous spread did not yield any growth. Transthoracic echocardiography was not compatible with infective endocarditis. Leukocyte scintigraphy, to be able to document another focus of infection if present, revealed leukocyte accumulation only at the site of paraspinal muscle abscess.

Pyomyositis is a primary infection of skeletal muscle that rapidly leads to abscess formation (6). It does not originate by contiguous spread from infection in nearby tissues, and it is relatively uncommon in temperate climates (7)

In temperate climates, pyomyositis is seen most often in patients with underlying conditions such as diabetes mellitus, alcoholism, CRF, immunosuppressive therapy, hematological malignancy, AIDS and intravenous drug addiction (2, 8).

Hemodialysis patients are often at increased risk of complications of bacteremia and *S. aureus* bacteremia is frequent in these patients (9).

Primary foci of infection include vascular-peritoneal access catheters or infected arteriovenous fistula (9). In hemodialysis patients, by hematogenous spread, pyomyositis can occur in temperate climates (10). In the present case, he was not on maintenance dialysis yet and the port of entry for *S. aureus* bacteremia was absent. The only probable cause of paraspinal muscle abscess in this patient was the history of gingival abscess two weeks before the admission. By subclinical bacteremic seeding, the patient developed paraspinal muscle infection and abscess because of his suppressed immune system (2).

In a previously reported case of non-tropical pyomyositis, involved muscles were deltoid, quadriceps, gluteus and psoas (8).

As a rare cause of severe back pain, a case of paraspinal pyomyositis was also reported (11). Maslen et al published a case series describing 14 of 854 patients with spinal epidural abscess caused by paraspinal abscess (12).

Herein, we report a case of non-tropical paraspinal pyomyositis with abscess formation in a diabetic CRF patient.

In this paper, we suggest that if a CRF patient is admitted with complaints of fever, lower back pain and local tenderness, paraspinal muscle abscess should be

considered. Delayed diagnosis may cause increased morbidity and mortality. Therefore, external drainage as well as antimicrobial treatment according to growth of the pathogen in aspiration specimen should be commenced immediately.

## REFERENCES

1. Deresiewicz RL, Parsonnet J. Staphylococcal infections. In: Fauci S A (ed), Harrison's Principles of Internal Medicine 14<sup>th</sup> Edition. The Mc-Graw-Hill Companies, New York 1998, vol11.pp 875-885.
2. Lazarus JM, Brenner BM. Chronic renal failure. In: Fauci SA (ed), Harrison's Principles of Internal Medicine 14<sup>th</sup> Edition. The Mc-Graw-Hill Companies, New York 1998, vol 2, pp 1513-1520.
3. Jimenez-Mejias ME, Lozano de Leon F, Alfaro-Garcia MJ, Fernandez-Lopez A, Jimenez-Ocana C, Canas Garcia-Otero E, Pachon-Diaz J. Pyomyositis caused by *Staphylococcus aureus*. *Med Clin (Bare)* 1992; 99(6): 201-5.
4. Silva J, Mason DH. Current therapy of infections involving the central nervous system. In: Schneider RC, Kahn EA, Crosby EC, Taren JA (eds), *Correlative Neurosurgery* 3<sup>rd</sup> Edition. Charles C Thomas Publisher, Springfield Illinois 1982, vol 1,pp 429-448.
5. Cook NJ, Hanrahan P, Song S. Paraspinal abscess following facet joint injection. *Clin. Rheumatol* 1999; 18 (1): 52-3.
6. Swartz MN. Myositis. In: Mandell GL, Dolin R, Bennett JE (eds), *Principles and Practice of Infectious Diseases* 4<sup>th</sup> Edition. Churchill Livingstone Company, New York 1995, vol 1, pp 929-930.
7. Loveless MO. Pyomyositis. In: Hoeprich PD, Jordan MC, Ronald AR (eds), *Infectious Diseases* 5<sup>th</sup> Edition. J.B. Lippincott Company, Philadelphia. 1994, pp 1374-1377.
8. Hossain A, Reis ED, Soundararajan K, Kerstein MD, Hollier LH. Nontropical pyomyositis: Analysis of eight patients in an urban center. *Am Surg* 2000; 66(11): 1064-6.
9. Korzets A, Weinstein T, On Y, Goren M, Chagnac A, Hermann M, Zevin D, Gafer U. Back pain and Staphylococcal bacteremia in hemodialysed patients-beware!. *Nephrol Dial Transplant* 1999; 14:483-486.
10. Rodriguez Jomet A, Fort J, Bartoleme J, Olmos A. Non-tropical pyomyositis in hemodialysis. *Med Clin (Bare)* 1984; 21; 82(15): 692-3.
11. Cecil M, Dimar JR. Paraspinal pyomyositis, a rare cause of severe back pain . *Am J Orthop* 1997; 26(11): 785-7.
12. Reihnsaus E, Waldbaur H, Seeling W: Spinal epidural abscess: a meta-analysis of 915 patients. *Neurosurg Rev* 2000; 232: 175-204.