

RADIOGRAPHIC EVALUATION OF A FLORID CEMENTO-OSSEOUS DYSPLASIA LESION SEEN IN A CAUCASIAN WITH PANORAMIC RADIOGRAPHY, CONE BEAM CT AND 3D RECONSTRUCTION

BEYAZ IRKTA GÖRÜLEN BİR FLORİD SEMENTO-OSSEÖZ DİSPLAZİ LEZYONUNUN PANORAMİK RADYOGRAFİ, KONİK IŞINLI BT VE 3B REKONSTRÜKSİYON İLE RADYOGRAFİK OLARAK İNCELENMESİ

Dr. Dt. Zühre ZAFERSOY AKARSLAN* Dr. Dt. Sevil ALTUNDAĞ KAHRAMAN**

Makale Kodu/Article code: 167
Makale Gönderilme tarihi: 08.06.2009
Kabul Tarihi: 29.06.2009

ABSTRACT

Florid cemento-osseous dysplasia (FCOD) is a rare jaw bones lesion seen among Caucasians. Radiographic examination plays an important role in the diagnosis of FCOD, especially in asymptomatic cases as biopsy increases the risk of infection and fracture. In this case report, a 48 year old Caucasian female patient who had FCOD in the jaws is reported and the usefulness of panoramic radiography, cone-beam CT and 3D reconstruction for radiographic evaluation is discussed.

Key words: Florid cemento osseous dysplasia, panoramic radiography, cone-beam computed tomography

ÖZET

Florid semento-osseöz displazi (FSÖD), beyaz ırkta çene kemiklerinde nadir olarak görülen bir lezyondur. FSÖD'nin teşhisinde radyografik muayene, özellikle asemptomatik olan vakalarda biyopsi işleminin fraktür ve enfeksiyon riskini artırmasından dolayı önemli bir yer tutmaktadır. Sunulan vaka raporunda, çene kemiklerinde FSÖD teşhis edilen 48 yaşındaki beyaz, bayan hasta ve teşhisin konulmasında panoramik radyografi, konik ışınli BT ve 3B rekonstrüksiyonun'un önemi tartışılmaktadır.

Anahtar kelimeler: Florid semento osseöz displazi, panoramik radyografi, konik ışınli bilgisayarlı tomografi

INTRODUCTION

Florid cemento-osseous dysplasia (FCOD) is an uncommon, benign fibro-osseous lesion of the jaw bones. In the nature of the lesion, mature bone is replaced with woven bone or cementum like round basophilic acellular structures in a matrix of connective tissue.^{1,2} FCOD is generally seen among middle aged black females. The occurrence rate of the lesion among Caucasians is very low.²⁻⁴ In most cases, the lesions do not have a hereditary basis though few familial cases have been documented in the literature.⁵

FCOD lesions could be asymptomatic and diagnosed during routine radiographic examination or reveal symptoms, such as expansion of the alveolar bone, pain and suppuration.^{1,2,4,6,7} Biopsy increases the risk of infection and fracture in asymptomatic cases, thereby radiographic examination plays an important role in the diagnosis of FCOD.

The radiographic appearance of the FCOD is related to the maturation degree of the lesion and could be as multiple radiolucent, mixed or lobulated dense radiopaque masses surrounded with a radiolucent halo. The lesions are generally located at tooth bearing areas and are quite symmetrical in shape and location.^{3,8-10}

* PhD, Department of Oral Diagnosis and Radiology, Gazi University, Faculty of Dentistry, Ankara, TURKEY.

** PhD, Department of Oral and Maxillofacial Surgery, Gazi University, Faculty of Dentistry, Ankara, TURKEY.



The aim of this case report is to present a 48 year old female Caucasian patient who had FCOD lesions of the jaws and to discuss the usefulness of panoramic radiography, cone-beam CT (CBCT) and 3D reconstruction for radiographic diagnosis.

CASE REPORT

A 48 year old female Caucasian patient attended the Oral Diagnosis clinic with a chief complaint of pain in the right mandibular premolar and molar region. The pain was dull, increasing with the use of her partial prosthesis and has been occurring for about 1 month. The patient had no systemic diseases, was non-medicated and did not smoke or consume alcohol.

On extra-oral examination, there was no facial asymmetry, temporomandibular joint or sinus pathology. A painful, firm mass was felt on palpation of the right side of the body of the mandible. The appearance and color of the overlying skin in this area was normal, but the right submandibular lymph node was tested tender.

Intra-oral examination revealed bony expansion at the mandibular right posterior region and a mucosal sore related to the use of the partial prosthesis at this site (Figure 1). A panoramic radiograph was taken for radiographic examination. The panoramic radiograph displayed a multiple mix of dense radiopaque masses with radiolucent borders, differing in size, located at the maxillary and mandibular arches (Figure 2). A skull radiograph was also taken for the evaluation of any lesion in the skull and no lesion was detected. Patient's serum alkaline phosphatase level was investigated and was found normal. According to these findings, the lesions were assumed to be FCOD. However, further investigation with CBCT was performed to support the initial diagnosis and to determine the relation of the lesions with the teeth roots and significant anatomical structures. Axial, coronal, sagittal and cross-sectional scans were made with the ILUMA ultra CBCT system (IMTEC Imaging, Ardmore, OK) at 120 kVp, 3.8 mA with an exposure time of 40 seconds. 3D reconstructions were created by reformatting the CBCT scans on a local workstation using the ILUMA dental imaging software according to the

manufacturer's instructions. The relationship of the lesions with the teeth roots, bucco-lingual cortical plates, significant anatomical structures and the perforation of the buccal cortical plate at the mandibular right posterior region was clearly assessed from the CBCT images (Figure 3). The 3D reconstruction views demonstrated the morphologic condition of bone in detail (Figure 4).

Clinical and radiographic examinations were performed for the patient's children because FCOD could represent familial occurrence. No sign of FCOD was present in those children who were advised for regular checkups as the disease may occur with advanced age.

The margin of the mandibular partial denture was ill-fitting. Hence, the prosthesis was remade after the sore healed up. The patient reported decrease in pain after this procedure. No surgical treatment was performed as no lesion was in contact with the oral cavity. The patient was informed about the disease and its complications and is undergoing regular dental checkups.

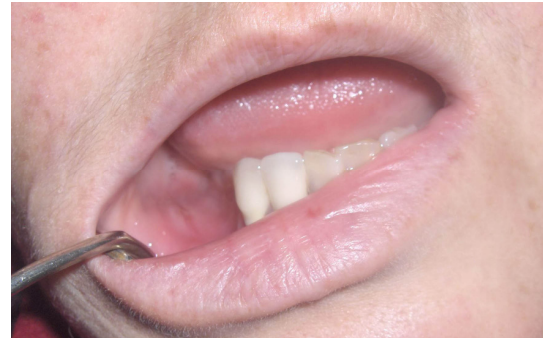

Figure 1: Intra-oral appearance of the patient

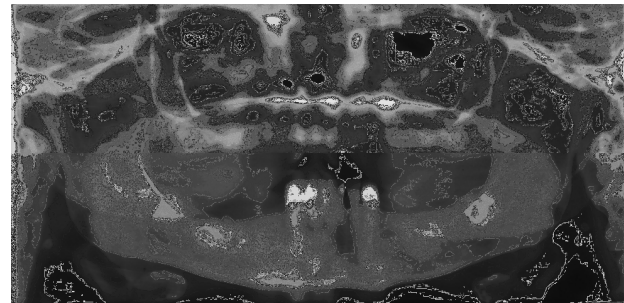


Figure 2: Panoramic radiograph of the patient

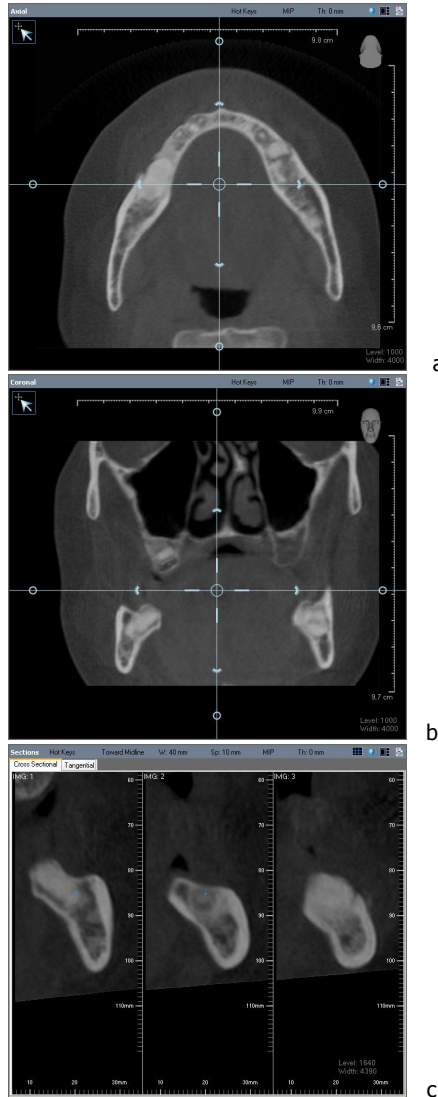


Figure 3: a) axial, b) coronal and c) cross sectional scans of the patient made with CBCT

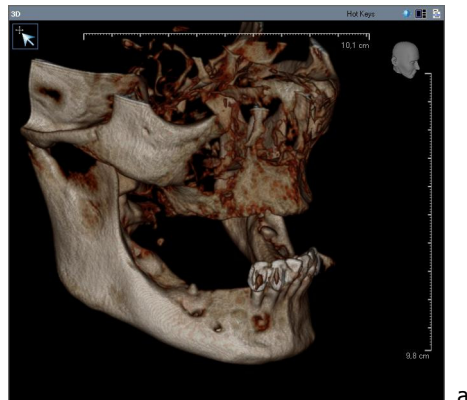

Figure 4: a) 3D reconstruction of right side

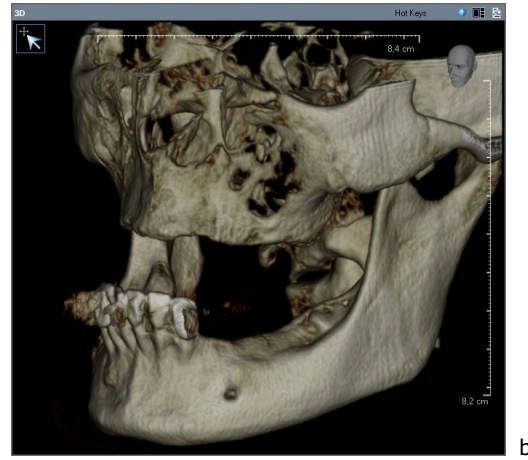


Figure 4: b) 3D reconstruction of left side made with CBCT

DISCUSSION

According to our knowledge there are 8 published FCOD cases affecting patients in Turkey. All patients affected were females with an age range of 16-51.^{4,11-14} Our case report adds a new female patient with FCOD lesion. The true prevalence of these lesions could not be established as the lesion could be either undiagnosed or misdiagnosed in many individuals.^{14, 15}

In this case report, there were multiple lesions in the four quadrants with only one located at the right quadrant of the posterior region of the mandible that led to expansion of the alveolar bone and ill-fitting of the prosthesis. Neither biopsy, nor surgical excision was performed as there was no exposed lesion into the oral cavity. It has been reported that surgical attempt should not be performed to asymptomatic lesions as this procedure could give rise to unfavorable results, such as infection and fracture.

According to the findings obtained from the panoramic radiograph, the lesions were assumed to be FCOD, but further investigation with CBCT was decided to support the initial diagnosis and to determine the extension and relation of the lesions with the teeth roots and significant anatomical structures.

While the usefulness of multidetector CT and 3D reconstruction for the radiographic evaluation of FCOD lesions were documented in the literature^{16,17}, to our knowledge the usefulness of CBCT, which is a

recent technology, in the evaluation of such lesions was not yet reported. Compared to the conventional CT technique, CBCT has several advantages for the radiographic imaging of the hard tissues in the oral and maxillofacial region such as, the smaller size, lower cost of the equipment and decrease in the scan time of the region of interest, patient radiation dose and metal artifacts. In addition, the sub millimeter resolution makes it possible for the coronal and subsequent multiplanar reconstructed images having the same resolution with the axial data and interactive analysis of the images could be made with a personal computer without the need of a local workstation. On the other hand, the system has some limitations including, greater image noise resulting from scattered radiation and variations in the homogeneity in the incident x-ray beam and added noise due to the detector system. The soft tissue contrast is poorer in this technique due to the decrease in contrast resulting from scatter radiation and artifacts.¹⁸ In our reported case, CBCT added valuable radiographic information regarding the relationship of lesions with significant anatomical structure, cortical plates and teeth roots. In addition, the 3D reconstruction images were highly demonstrative for the examination of the bone surface.

Differential diagnosis of FCOD should be made with enostosis/exostosis, cementoblastoma, cemento-ossifying fibroma, fibrous dysplasia, chronic diffuse osteomyelitis and Paget's disease as they have similar sclerotic appearance on radiographs. Enostosis/exostosis lesions are continuous with the cortical plates and are more clearly visualized as high density masses on axial CT scans compared to occlusal radiographs.^{16,17} Cementoblastoma is fused to the apices of teeth while FCOD lesions are not. Cemento-ossifying fibroma exhibits more bucco-lingual expansion, compared to FCOD.^{17,19} Trabeculation pattern of fibrous dysplasia differs from FCOD as being peculiar in shape and smaller in size. In addition, the borders of fibrous dysplasia tend to be diffuse; blending in with the adjacent sound bone structure.¹ Chronic diffuse osteomyelitis is unilateral and frequently located in the body, following the angle and the ramus of the mandible.¹ On the other hand, FCOD lesions are usually symmetric bilateral lesions. Paget's disease may have a cotton-wool appearance,

but differential diagnosis is made with loss of lamina dura, presence of lesions in other bones and elevation in serum alkaline phosphatase level.⁴ A radiograph taken from the skull did not demonstrate any lesions and no biochemical changes were found in the reported case; therefore differential diagnosis was made from Paget's disease.

CONCLUSION

This case adds information to the literature about the occurrence of FCOD among Caucasians and emphasizes the role of panoramic radiography, CBCT and 3D reconstruction images in the radiographic diagnosis of the lesion.

REFERENCES

- 1-Singer SR, Mupparapu M, Rinaggio J. Florid cemento-osseous dysplasia and diffuse osteomyelitis. J Am Dent Assoc 2005; 136(7):927-31.
- 2-Mangala M, Ramesh DN, Surekha PS, Santosh P. Florid cement-osseous dysplasia. Review and report of two cases. Indian J Dent Res 2006; 17(3):131-34.
- 3-MacDonald-Jankowski DS. Florid cement-osseous dysplasia: a systematic review. Dentomaxillofac Radiol 2003; 32(3):141-49.
- 4-Dağistan S, Tozoğlu U, Göregen M, Cakur B. Florid cemento-osseous dysplasia: A case report. Med Oral Pathol Oral Cir Buccal 2007; 12(5): E348-50.
- 5-Coleman H, Altini M, Kieser J, Nissenbaum M. Familial florid cemento-osseous dysplasia-a case report and review of the literature. J Dent Assoc S Afr 1996; 51(12):766-70.
- 6-Waldron CA. Fibrous lesions of the jaws. J Oral Maxillofac Surg 1985; 43(4):249-62.
- 7-Musella AE, Slater LJ. Familial florid osseous dysplasia: a case report J Oral Maxillofac Surg 1989; 47(6):636-40.
- 8-Oikarinen K, Altonen M, Happonen RP. Gigantiform cementoma affecting a Caucasian family. Br J Maxillofac Surg 1991; 29(3):194-97.
- 9-Waldron CA. Fibro-osseous-lesions of the jaws. J Oral Maxillofac Surg 1993; 51(8): 828-35.



- 10-Miyauchi M, Ogawa I, Takata T, Ito H, Nikai H, Ijuhin N et al. Florid cemento-osseous dysplasia with concomitant simple bone cysts: a case in a Japanese woman. J Oral Pathol Med 1995; 24(6): 285-87.
- 11-Dağistan S, Göregen M, Çakur B, Miloğlu Ö. Cemento-osseous dysplasias. Rev Clin Pesq Odontol 2007; 3(1):43-9.
- 12-Özen Sandıkçı E, Zengin Z, Sümer P, Günhan Ö. Semento-osseöz displazi: Dört olgu raporu. [Cemento-osseous dysplasia: Report of four cases] . Hacettepe Dişhekimliği Fakültesi Dergisi 2007; 31(2):38-42.
- 13-Akkaya N, Avcu N, Kansu Ö, Er N, Kansu H. Florid semento osseöz displazi: Olgu raporu [Florid cemento-osseous dysplasia: A case report]. Hacettepe Dişhekimliği Fakültesi Dergisi 2005; 29(1) 52-5.
- 14-Meral G, Çakacı M, Er N. Florid cemento-osseous dysplasia. A case report. Hacettepe Dişhekimliği Fakültesi Dergisi 2005; 29(4):104-7.
- 15-Gündüz K, Çelenk P, Metin M, Günhan Ö. Florid semento-osseöz displazi[Florid cemento-osseous dysplasia]. GÜ Dişhek Fak Derg 2005; 22(3): 181-4.
- 16- Arijı Y, Arijı E, Higuchi Y, Kubo S, Nakayama E, Kanda S. Florid cemento-osseous dysplasia. Radiographic study with special emphasis on computed tomography. Oral Surg Oral Med Oral Pathol 1994; 78(3): 391-96.
- 17- Beylouni I, Farge P, Mazoyer JF, Coudert JL. Florid cement-osseous dysplasia. Report of a case documented with computed tomography and 3D imaging. Oral Surg Oral Med Oral 1998; 85(6): 707-11.
- 18- White SC, Pharoah MJ. Oral Radiology Principles and Interpretation. 6th ed, St. Louis; CV Mosby: 2009. pp 225-43.
- 19-DelBalso AM, Werning JT. The role of computed tomography in the evaluation of cemento-osseous lesions. Oral Surg Oral Med Oral Pathol 1986; 62(3): 354-57.

Yazışma Adresi:

Dr. Dt. Zühre ZAFERSOY AKARSLAN
Gazi University Faculty of Dentistry
Department of Oral Diagnosis and Radiology
Emek / Ankara 06510 TURKEY
Phone: +90 312 203 41 56
Fax: +90 312 223 92 26
e-mail: dtzuhre@yahoo.com

