



Giant Odontogenic Myxoma of the Upper Jaw: A Case Report

Alberto Benedetti¹, Vladimir Popovski¹, Danica Popovich-Monevska¹, Antonio Kirkov¹, Goran Pancevski¹, Suzana Bozovic¹, Aleksandar Iliev¹, Azem Ismani¹ and Aleksandar Stamatovski^{2*}

¹ University Clinic for Maxillofacial Surgery, Skopje, Macedonia

² Trainee in Maxillofacial Surgery, Clinic for Maxillofacial Surgery, Skopje, Macedonia

*Corresponding e-mail: alexandar.stamatovski@gmail.com

ABSTRACT

Odontogenic myxoma is rare benign neoplasm of jaw bones which is locally aggressive and non-metastasizing. A 23-year-old male sought medical attention with complaint of progressively increasing of asymptomatic swelling to the right side of maxilla causing serious facial asymmetry. Radiological examination, CT with 3D reconstruction was performed and it was shown well-defined unusual large radiolucent mass associated with impacted teeth within the right maxillary sinus extending into the nasal cavity with expansion of both buccal and palatal cortical plate of right maxilla. The treatment of choice was a surgical tumoral radical resection under general anaesthesia with surgical extraoral approach and preservation of the nearby structures. Odontogenic fibromyxoma was the definitive histopathological diagnosis. The postoperative period was uneventful, and the patient fully recovered. Long-term surveillance is required due to the high rate of local recurrence.

Keywords: Myxoma, Odontogenic fibromyxoma, Odontogenic tumours, Maxilla

INTRODUCTION

Odontogenic myxomas (OM) are relatively rare but locally invasive benign tumours originating from odontogenic ectomesenchyme origin with or without odontogenic epithelium which do not metastasise [1-6].

OMs are most commonly found in the posterior region of the jaws, and may not be diagnosed until an extensive lesion produces swelling or the lesion is discovered in radiographs. Maxillary myxomas may infiltrate into and occupy the maxillary sinus and cause nasal obstruction and even exophthalmos. They have variable clinical, radiological and histological features.

Their size varies and if neglected it can exhibit voluminous more than 5 cm. The literature presents different sizes and shapes of odontogenic myxomas, but giant OMs (>6 cm) are rarely reported. The treatment of choice for OM is surgical excision by enucleation, curettage, or block resection.

CASE PRESENTATION

A 23-year-old male sought medical attention presented with a mass on the right side of the face, which had persisted for four months, causing serious facial asymmetry of the right nasomaxillary groove.

The initial swelling was asymptomatic by no pain and sensation, and he never noticed any discharge from the affected region. On systemic examination, the patient was found to be healthy, and routine haematological investigations were normal.

Extra-oral examination revealed a diffuse, tender, non-fluctuant, bony hard swelling over the right body of maxillary bone involving the right cheek (Figure 1).

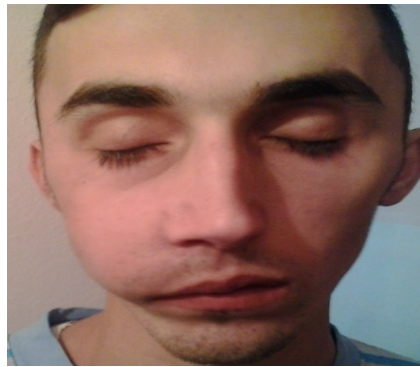

Figure 1 Pre-operative findings showing swelling in the right-side of mid face

The skin over the lesion appears as normal and there was no cervical lymphadenopathy or trismus. The lateral canthus and right oral commissure was pushed downward.

Intra-oral examination, revealed an erythematous ulceroproliferative growth on right maxillary alveolus with an expansion of buccal and palatal cortex. Intraorally, teeth 11 to 16 were missing.

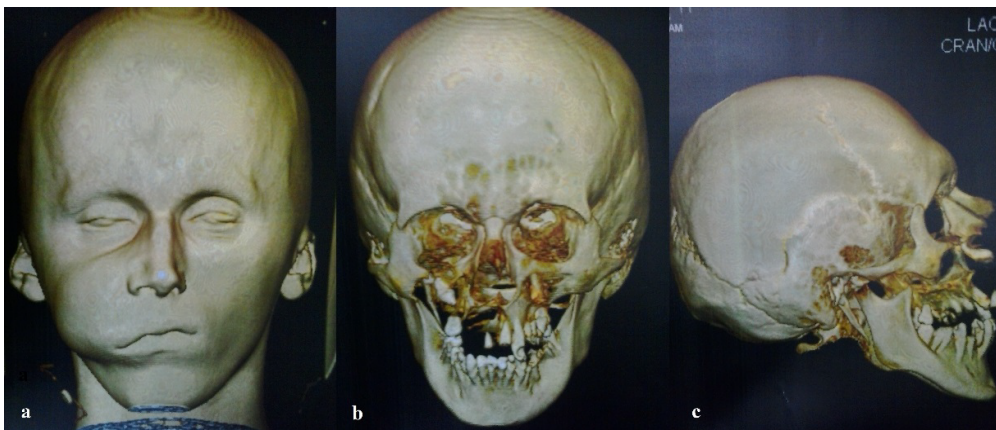


Figure 2 (a, b and c) 3D reconstruction of the computed tomogram

Computed tomography (CT) scans of both axial and coronal views with 3D reconstruction (Figure 2) showed a well-defined unilocular homogeneous mass encroaching onto right maxillary antrum as well as the right side of the nasal cavity compressing the lateral nasal wall presented with deviated septum, invading the inferior and middle nasal meatus (Figure 3). The patient had unilateral nasal obstruction with hyper-nasal speech. Superiorly it was seen abutting of the floor of orbit. Radiolucency and radio opacity was associated with impacted teeth.

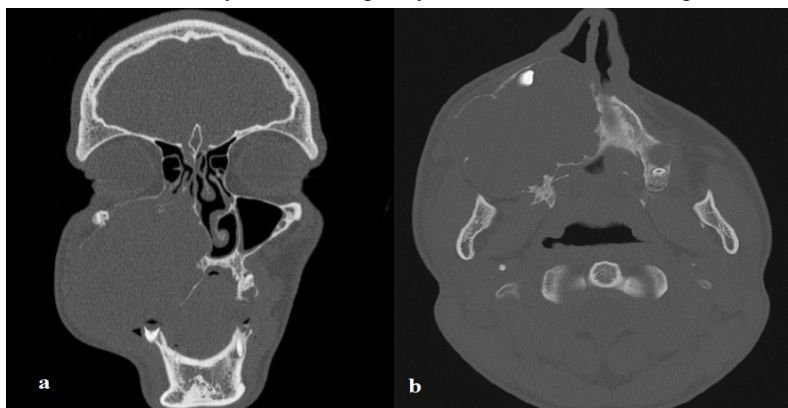


Figure 3 (a and b) Coronal and axial view of computed tomography showing expansile invasion

An incisional biopsy was performed, and a suggestive histopathological diagnosis of the chronic ulcerative inflammation was proposed.

Minimally invasive endovascular angiography and embolization of the right internal maxillary artery was performed 3 days before surgery for immediate control of bleeding.

Under general anaesthesia the tumour was exposed through a Weber Ferguson incision with light intra-oral upper vestibular incision using electrosurgical scalpel (Figure 4). Right radical maxillectomy was done and haemostasis achieved. The tumour was totally excised measured $80 \times 67 \times 44$ mm and 125 g in weight and appeared as a completely encapsulated whitish-grey hard mass, round to oval in shape with well-defined borders and lobulated surface (Figure 4). The postoperative period was uneventful, and the patient fully recovered.

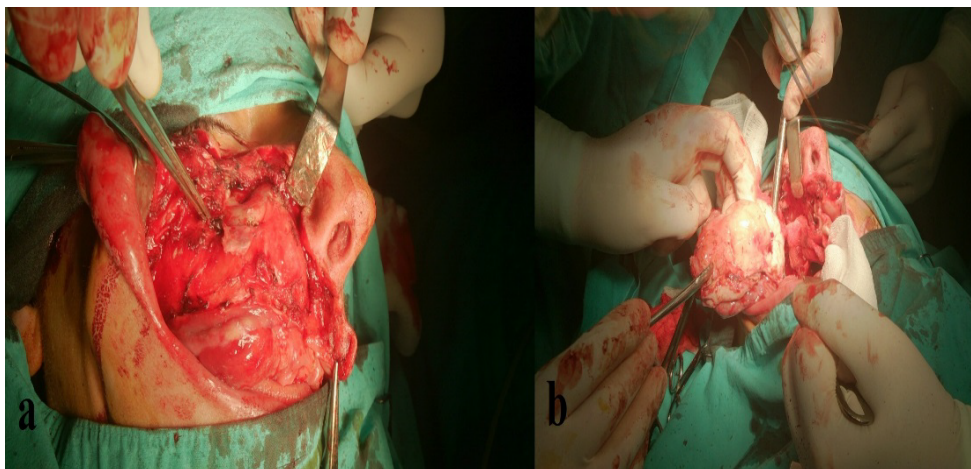


Figure 4 (a) Intra-operative findings (b) Surgical specimen of the right maxillary bone

Histopathological examination showed hypocellular and hypovascular lesion with myxoid component of stellate-shaped and spindle fibroblast like-cells typical for odontogenic fibromyxoma. Islands of calcification and foci of bony trabeculae were visible and found.

The follow-up period after 12 months showed no recurrence of the lesion. There were no surgical complications or intracranial infections.

DISCUSSION

OMs have a silent locally destructive nature which is related to the accumulation of myxoid ground substance in the tumour [1].

Ying, et al., present study who describes a large case of odontogenic myxoma of the bilateral maxillae, which caused a defect in the right skull base bone [2].

Mariana, et al., explain that the locally aggressive nature is associated with containing the capsule of this tumour [3,4].

Haroon Rashid and Atif Bashir also performed an extended resection of the upper jaw in 22-year-old female patient presented with OM complaining of an aching pain in the upper right quadrant [3].

The degree of vascularisation of the tumour is variable and in the most of cases they have very poor blood supply. Radiographically, OMs have several interpretations such as unilocular, multilocular, pericoronal (less often) and radiolucent/radiopaque (rare) patterns. The radiographic image is not pathognomonic and may simulate a number of diverse lesions.

The most common appearances of giant odontogenic myxomas/fibromyxomas are unilocular (in children) and multilocular “soap bubble” “honeycomb” or “tennis racket” radiolucency with well-defined and corticated margins [5-7].

In some occasions myxoma may be associated with impacted teeth, and cause root resorption or missing teeth,

malocclusion. In the present case, the growth of the mass had accelerated for 4 months prior to surgery containing impacted teeth.

Surgical treatment with a radical resection is the best treatment of choice for aggressive maxillary OMs. Adjuvant radiotherapy is a rational option but shouldn't be considered as a standard therapy and is of no value in the management of these tumours because they are classified as benign [2,6].

Histopathological and microscopical characteristics of the myxoma/fibromyxoma are hypocellular stromas, stellate, spindle-shaped cells, fusiforms and round cells in an abundant loose myxoid stroma, higher or few amounts of collagen fibrils with loci of calcification or ossification [6]. Immunohistochemical and ultrastructural analysis are proposed to detect the histogenesis of the OMs and should be performed to clarify the diagnosis.

High recurrence rate about 15-20% is presented in these tumours after subtherapeutic removal or simple enucleation with curettage, but in spite of this the prognosis is good [2,4,6,8-10].

CONCLUSION

Due to its unspecific nature, clinical and histopathologic examination followed by diagnostic methods will lead to the correct diagnosis of odontogenic fibromyxomas which lack the characteristic appearance. The location and dimension of odontogenic fibromyxomas determinate the management modalities but radical surgical resection with long-term follow-up period during first 2 years is necessary because of the recurrent nature of this disease.

REFERENCES

- [1] Gupta, Suchitra, et al. "Odontogenic myxoma." *National Journal of Maxillofacial Surgery* Vol. 4, No. 1, 2013, p. 81.
- [2] Liu, Ying, et al. "A large odontogenic myxoma of the bilateral maxillae: A case report." *Oncology Letters* Vol. 8, No. 3, 2014, pp. 1328-32.
- [3] Rashid, Haroon, and Atif Bashir. "Surgical and prosthetic management of maxillary odontogenic myxoma." *European Journal of Dentistry* Vol. 9, No. 2, 2015, p. 277.
- [4] Dalbo Contrera Toro, Mariana, et al. "Odontogenic Myxoma in Children: A Case Report and Literature Review." *Case Reports in Oncological Medicine* Vol. 2016, 2016.
- [5] Singaraju, Sasidhar, Sangeetha P. Wanjari, and Rajkumar N. Parwani. "Odontogenic myxoma of the maxilla: A report of a rare case and review of the literature." *Journal of Oral and Maxillofacial Pathology* Vol. 14, No. 1, 2010, p. 19.
- [6] Dietrich, Eva-Maria, et al. "Odontogenic fibromyxoma of the maxilla: a case report and review of the literature." *Case Reports in Medicine* Vol. 2011, 2011.
- [7] Chaudhary, Zainab, et al. "Odontogenic myxoma: Report of three cases and retrospective review of literature in Indian population." *Contemporary Clinical Dentistry* Vol. 6, No. 4, 2015, p. 522.
- [8] Subramaiam, Ramkumar, et al. "Odontogenic Myxoma of the Maxilla-A Rare case Report." *Journal of Clinical and Diagnostic Research* Vol. 9, No. 5, 2015, p. ZD29.
- [9] Dalbo Contrera Toro, Mariana, et al. "Odontogenic Myxoma in Children: A Case Report and Literature Review." *Case Reports in Oncological Medicine* Vol. 2016, 2016.
- [10] Friedrich, Reinhard E., Hanna A. Scheuer, and Wolf Hoeltje. "Recurrent Maxillary Odontogenic Myxoma Following Partial Maxillary Resection and Consecutive Osseous Reconstruction Including Tooth Transplantation." *Anticancer Research* Vol. 36, No. 6, 2016, pp. 3155-60.