



Annual Screening Mammogram and its Relation to Breast Density

Sabek EAS*, Saleh GM and Salem HT

Health Radiation Research Department, National Center of Radiation Research and Technology,
Atomic Energy Authority, Ahmed El-Zomor Street, Nasr City, Egypt

*Corresponding e-mail: hi_eman2308@yahoo.com

ABSTRACT

Background: Current national screening programs totally depend on mammographic evaluation. After increased incidence of breast cancer in women under the age of 35, mammography sensitivity is now a question. Several factors added to decrease sensitivity of mammography, such as increased density in older age groups and increased aggressiveness of tumour biology. All these factors will change the reliability of the screening program. The study is a retrospective study conducted at Ain Shams University. **Method:** 138 patients diagnosed with cancer breast underwent both mammography and sonography to determine percentage of patient with more than one focus, age and density distribution breast cancer in the affected patient and accuracy of both mammography and US. **Results:** By studying this population, we found that around 61,44% have areas of density ranging from dense breast, heterogenous density or scattered density. These areas of density render the mammography a less sensitive tool as its sensitivity fall to 34.09%, while that of US was 77.27%. **Conclusion:** As breast cancer is prevalent in younger population, also with increased density in older population who are relatively insensitive to mammography, we recommended the use of Automated Breast Ultrasound (ABUS) in the national screening program.

Keywords: Breast density, Breast cancer, Screening mammogram

INTRODUCTION

Early and accurate diagnosis of the extent of disease has a deep impact on extent of surgical approach, surgical resection and hence disease-free interval. Approximately 7% of all breast cancers are diagnosed in women <40 years of age and less than 4% in women below the age of 35 [1]. Although breast cancer is uncommon in young women, it is the most frequent cancer in women <40, accounting for 30-40% of all incidents of female cancer [1].

Multiple expression is used to describe the presence of more than one focus in synchronous way, multifocal (MF) refers to the presence of more than one focus in the same breast quadrant with intervening normal tissue, multicentric (MC) refers to the presence of more than one focus in multiple quadrants in the same breast whereas bilateral (B) is the affection of both breasts. Historically, the gold standard for routine breast cancer screening involved radiographic mammography technology but imaging limitations for those patients with dense breast tissue was an issue; dense breast tissue makes mammography interpretation difficult as radiographic images of dense breast tissue appear similar to cancer.

Despite favourable research, mammography alone has not been effective in all populations of women and is most notably ineffective in women who have dense breast tissue. Although the sensitivity of mammography alone in women with fatty breast tissue can be as high as 97 percent, this dramatically decreases in women with dense breasts, falling to as low as 48 percent [2]. It has been reported that mammography alone can miss between 37 and 70 percent of breast cancers within this population [3]. Dense breast tissue obscures tumours on mammograms, making it difficult for radiologists to read and interpret the exams. This inaccuracy has resulted in an increased number of missed cancers with subsequent increase in healthcare expenses and patient anxiety [2].

The hazard ratio for breast cancer death for multifocal and/or diffuse tumours versus unifocal ones was 1.96 [4]. There are two major factors explaining the worse prognosis in young women: late presentation [5]. and a smaller, but highly significant component of more aggressive tumour biology. The former underlines the need strong screening program that can deal with the change in tumour biology and the younger age of prevalence.

Aim of work

- To study the distribution of breast density in Egyptian multiple focal breast cancer.
- To determine the accuracy of mammography in diagnosing multifocal, multicentric and bilateral breast cancer and hence the efficacy of current screening program.
- Determine the efficacy of US in evaluating this disease entity and whether it can be used for management.

MATERIAL AND METHODS

All patients in our study were subjected to history taking for relevant data, clinical examination in surgery department, both mammography and ultrasound examination in radiology department with biopsy taking under guidance of US if needed. Mammography was done using (Selenia, Hologic 2D Digital Mammography). Film processing optimized for mammography was used (Kodak, Rochester, NY). Both craniocaudal and mediolateral views were done in all patients, magnification view was restricted to some cases. Ultrasound examination was done, using a real time, dynamic equipment (GE Voluson 730 pro, GE Healthcare, USA), which has a high resolution, phased- array transducer and a frequency that ranges from 7.0 to 12.0 MHz, Colour and Power Doppler are available in the equipment. Patients are divided according to the ACR (American College of Radiology) classification; grade 1 is fatty breast, grade 2 is scattered fibro glandular tissue, grade 3 heterogeneous density. (Grade 2 and 3 are combined in one group in this study) and grade 4 is dense breast.

Mammography

Evaluation of mammogram was done to assess the density, mass lesion, calcification, skin thickening, and areas of distortion. Spot compression and lateral view were done if recommended.

All US examinations were done by an experienced radiologist in women imaging (more than 6 years of experience), with patients in the supine position, examination starts with the suspected lesion area followed by the surrounding area then the remainder of the breast and finally the axilla. The contralateral breast was examined in the classical way if there were no suspected lesions, and with the same previously mentioned way if there was index lesion followed by the axilla. All examinations are carried in radial and antiradial as well as longitudinal and transverse orientation. Masses were analyzed regarding the site, size, borders, orientation, additional foci, calcification, duct dilatation, then the BIRADS scoring is written as follows, BIRADS 1 normal study, BIRADS 2 benign findings, BIRADS 3 query benign follow up is recommended, BIRADS 4 query malignant biopsy is recommended, BIRADS 5 highly suspicious of malignancy, BIRADS 6 sure malignant mass. BIRADS 4 and 5 are subjected to US guided biopsy to ensure pathological diagnosis. This study consists of patients proved to have cancer breast.

In case of additional masses not detected in mammogram, retrospective analysis of the mammogram was carried out to determine the cause of missed diagnosis. There were four causes for such error; poor technique, interpretation error, area not included in routine mammogram and the presence of obscuring dense tissue. In this study, obscuring the mass by dense tissue is the most prevalent we only included cases with obscuring dense tissue to illuminate other factors. Extra lesion in US will consider the mammography result as false negative.

Biopsy and surgery

Masses with suspected malignancy are subjected to ultrasound guided biopsy for confirmation of malignancy, then cases followed by mastectomy. The excised specimen was evaluated by pathology to determine the number of lesions, the presence of extra foci by pathology will render the US false negative and the mammogram considered false negative as well.

Statistical analysis

Data were analyzed using Statistical Package for Social Science (SPSS) version 21.0. Quantitative data were expressed as mean \pm standard deviation (SD). Qualitative data were expressed as frequency and percentage. Sensitivity and their confidence intervals were measured using the software Confidence Interval Analysis (CIA) for windows, developed using Borland Delphi V-4.0 (Inprise Corporation) and For Help (ForeFront Technologies). $P < 0.05$ was considered significant and $P < 0.01$ was considered highly significant.

Differences in accuracy between mammography and US were assessed by using the McNemar test. One-way ANOVA

was used to find if there's a significant difference between mean ages of patients classified according to their breast density. Chi-square test was used to explain the relationship between categorical variables (breast densities and lymph nodes infiltration).

RESULTS

Total 138 patients previously diagnosed as having cancer breast were included in the study, of whom 44 (31.88%) have more than one focus of breast cancer and 94 patients (68.12%) have only one disease focus. The mean age of patients with more than one focus is 44.6 ± 8.2 while the mean age of patients with only one focus of breast cancer is 47 ± 11.8 . Also, the mean age differs between patients when classified according to their breast density; patients with dense breast have a mean age of 40.5 years which is significantly less than that of patients with heterogenous and fatty breast (Figure 1).

Of the 44 patients, 14 have bilateral lesions, 26 have multifocal and 30 patients have multicentric lesions as shown in Table 1. Lymph node infiltration was found in half of the patients with more than one focus while only 26% of patients with unifocal lesion have lymph node infiltration; a difference which is statistically significant $\chi^2(1)=7.37$ and $p=0.007$.

The accuracy of ultrasound was 77.27% while that of mammography was 34.09%. An exact McNemar's test determined that the difference in accuracy between the US and mammography was highly statistically significant at p-value of 0.0005.

Table 1 Descriptive data of tumour characteristics

Variables	Frequency	Percentage
Site	14/19/11	31.8/43.2/25.0
Multifocal	26/18	59.1/40.9
Multicentric	30/14	68.2/31.8
Breast density	17/17/10	38.6/38.6/22.7
Lymph node infiltration	22/22	50/50

Site (bilateral/right/left); Multifocal, Multicentric & LN infiltration (yes/no); Breast density (Fatty/heterogenous/dense)

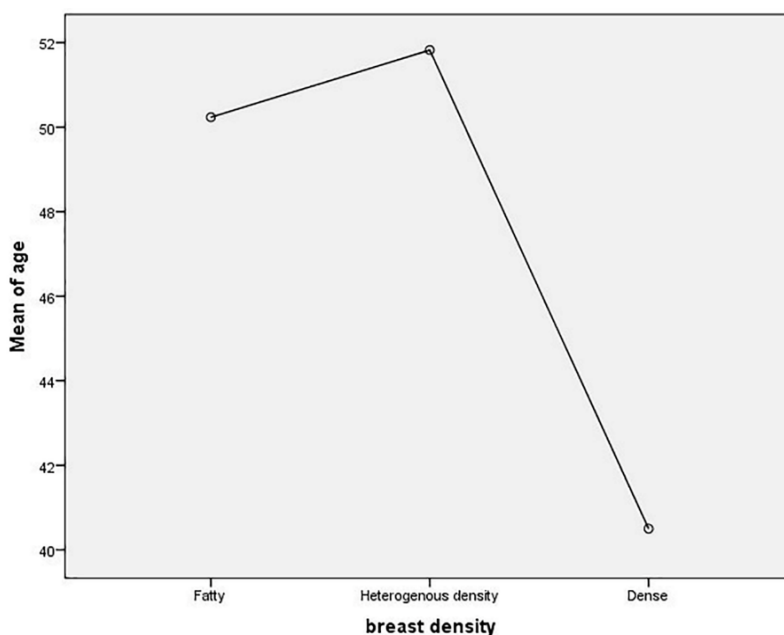


Figure 1 Mean age of each breast density

DISCUSSION

The role and indication of breast US in the diagnosis and management of breast disease have been expanded in the past 2 decades, not only due to marked advances in computing capabilities, with subsequent increase in spatial and contrast resolution, but also due to change in disease pathological behaviour and age of prevalence of breast cancer. Recent years showed that US can play a role in the detection of mammography and clinically occult carcinoma in dense breast.

Breast density is not discernible by palpation but rather relates to the fact that x-rays permeate different types of breast tissue differently. Women with dense breasts have been shown to have a four- to six-folds increased risk of developing breast cancer [6]. Moreover, breast cancer is more likely to be missed in areas with increased density. Up till now researchers do not agree on what causes some women's breasts to be denser than others, but many factors may attribute to increased breast density; genetic is one of them [7], this may explain the increased incidence of breast cancer in some nations [7], also the increased dependence on hormone replacement therapy and contraceptive pills through increasing level of estrogen may be another important factor. Some studies have shown that women who are more physically active have a lower absolute mammographic density compared with less active women [8-10], this may be attributed to decreased estrogen level through decrease in body fat which is a major source of estrogen [10-12]. In recent years with increased sedentary life style that resulted in increased body mass index in many populations, together with the increased usage of exogenous estrogen medication may explain the increase in breast density and hence the incidence of breast cancer. In our country, all factors that increase breast density are prevalent, resulted in increased incidence of cancer breast in younger population. In this study, the mean age of studied population was 47 ± 11.8 years while the mean age of patients with more than one focus of breast cancer is 44.6 ± 8.2 years. This means that breast cancer, not only became prevalent in younger population [5], but also increased in aggressiveness. In this study, around 61.4% (total patients with dense and heterogeneous density breast) of the affected patients with more than one focus show areas of density that may hinder diagnosis of breast cancer by mammography (Table 1). This means that the use of US is a very crucial part of any breast examination. In general, there is an inverse relationship between patient age and mammographic breast density. However, there were outliers at the extremes of age [13]. This study shows that the mean age of patients with fatty breast is 50.2 years while those with heterogeneous density is 51.8 years and patients with dense breast have a mean age of 40.5 years (Figure 2). In a study by Pisano, et al., done on a sample from the general population, women with breast densities in the scattered and heterogeneously dense categories were 43% and 39%, respectively, whereas 10% have fatty breast. In this study, the prevalence of fatty breast reached 38.6%, heterogeneous-density 38.6% and dense breast 22.7%, taking in consideration that our study contains women having cancer breast. This means that over 60% of these patients show areas of density that may render mammography a less sensitive tool for early detection, accurate diagnosis, and hence proper management (Table 2) [13,14].

Table 2 The sensitivity and specificity of US and mammogram

Variables	US	95% CI	Mammography	95%CI
Sensitivity	0.714	0.500, 0.862	0.381	0.208, 0.591
Specificity	0.217	0.097, 0.419	0.217	0.097, 0.419

Bilateral breast tumour is the affection of both breasts, whereas MF and MC were defined as more than one lesion in the same quadrant or in separate quadrants, respectively [15] on the same side. As advances in preoperative imaging continue, the number of bilateral, MF and MC tumours identified increase [16]. In the literature, the incidence of bilateral breast cancer is 4-20% [17], whereas the incidence of MF and MC tumours in the literature ranges from 6% to 60% [18], our study showed that breast cancer with more than one focus including B, MF and MC reaches 31.88% of the total cancers detected.

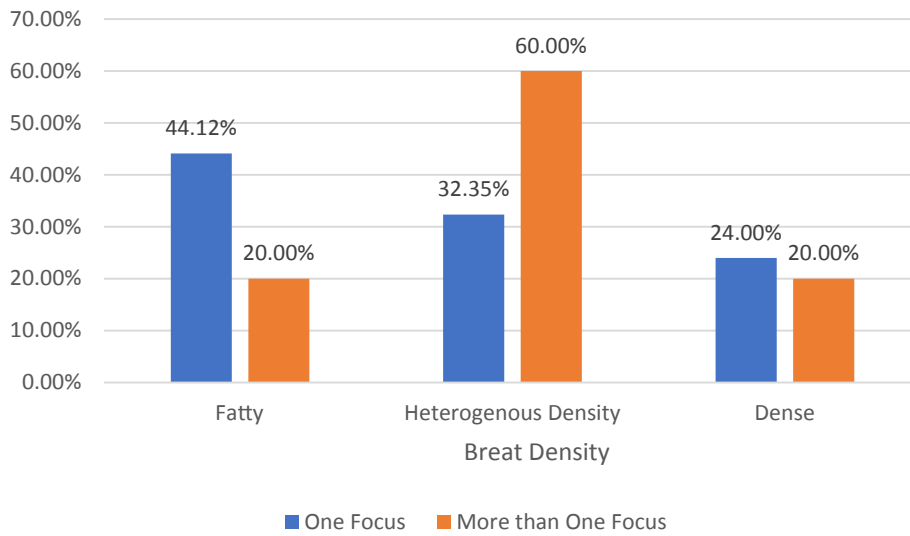


Figure 2 Percentage of unifocal and multifocal disease in each breast density

The presence of more than one focus of synchronous tumour would signify a worse prognosis when compared with their unifocal (UF) counterparts [18,19]. Several reports showed a correlation between multifocality and multicentricity and the rate and extent of lymph node metastases [20]. In the study by Lynch, et al. [15], lymph node infiltration reaches 43.1% versus 27.3% for multiple focus and unifocal disease respectively. In our study, the presence of lymph nodes infiltration reaches 50% in breast cancer with more than one focus, and 26.4% in the unifocal disease. This may have correlation to the bad prognosis seen in this entity (Figure 3).

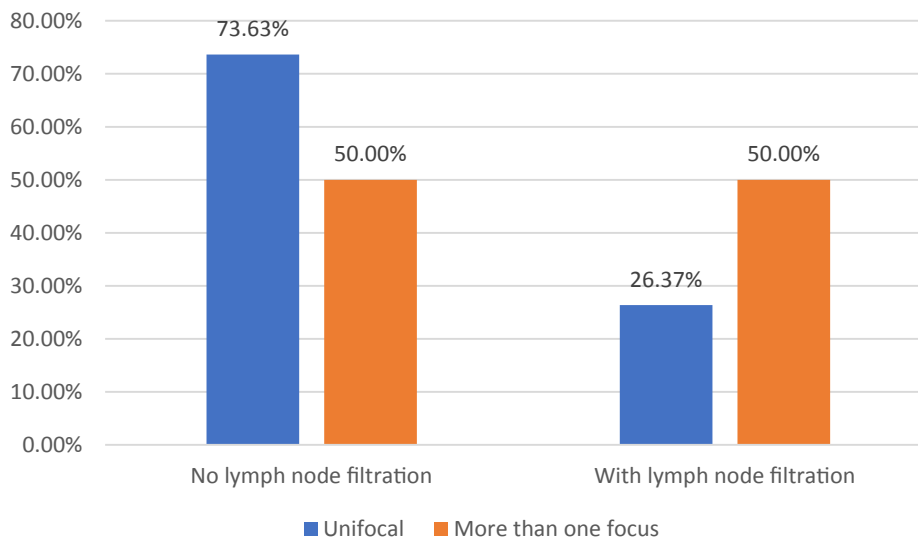


Figure 3 Percentage of lymph nodes infiltration in unifocal and more than one focus disease

The sensitivity of the mammography has been questioned a lot, and shows great difference from study to another, as Chae, et al., shows a sensitivity of 54.55% [21], in the study of Zhao, et al. it reaches 88.5% [22]. Also, the sensitivity varies according to the composition of the breast; extremely dense breasts show significantly lower sensitivity of screening mammography in women than in those with almost entirely fatty breasts (62.2% vs. 88.2%, respectively) [23]. In this study, we considered the exam that determine the number of breast cancer focusses correct and the exam failed to determine the actual number as detected by pathology incorrect, according to that the accuracy of mammography was 34.09%, while sonography has a sensitivity of 77.27% (Figures 4 and 5), these numbers should not be compared to the screened general population but it can give a clue about the lower accuracy of mammography

in the breast cancer with more than one focus especially with increased density of the breast [24]. Also, it seems that the accuracy will vary according to the size and numbers of the focuses. All the former results, with increased percentage of dense breast and hence breast cancer especially that contain more than one focus with its bad prognostic outcome, all these factors necessitate a strong screening program that assures a prompt diagnosis as early as possible with subsequent better prognosis.

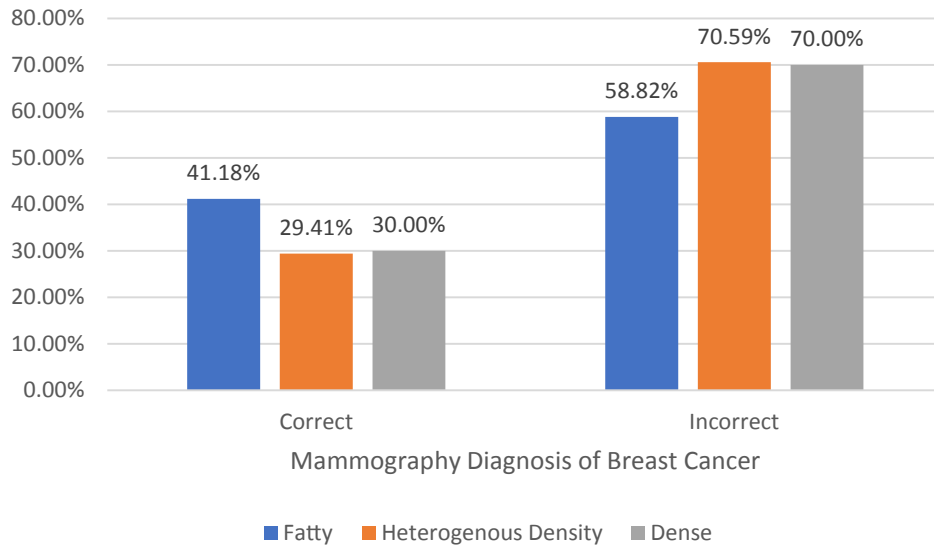


Figure 4 Accuracy of mammography among different types of breast densities

As annual mammography remains the standard of care for breast cancer screening and with increased incidence of dense breast, some authors suggest alternating the two modalities at 6-month intervals [25], instead of having both examinations simultaneously [25]. However, using traditional hand-held US in screening program has many limitations, as it is a time-consuming exam, takes up to 30 minutes to be complete, and is operator dependent that depends on the skills and expertise of the operator. Recently the Automated Breast Ultrasound (ABUS) has been introduced to the medical field, this in part reduces the need for radiologist and decreases the time consumed during the study. It allows scanning of the whole breast. Then the picture is transferred to a work station to be read by the radiologist [26]. Taking former information into account, ABUS can allow US to be a part of the national screening programs especially in those who have dense breasts without all the disadvantages of traditional US. The ability to scan the entire breast, large number can be done making it suitable to screening programme.

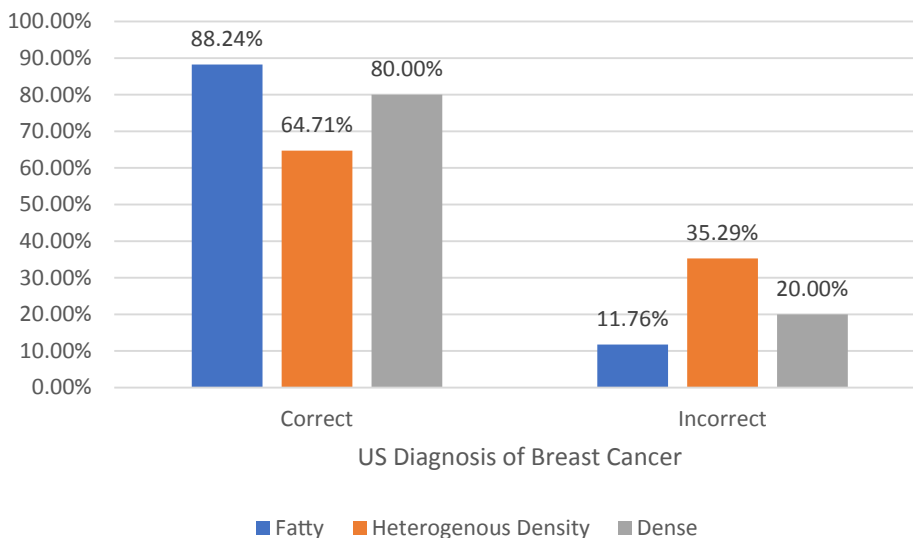


Figure 5 Accuracy of US among different types of breast densities

As the overall accuracy of US fails to reach very high levels (77.27%) (Figure 6) in this disease entity we recommend the use of MRI in the management of patients with more than one focus.

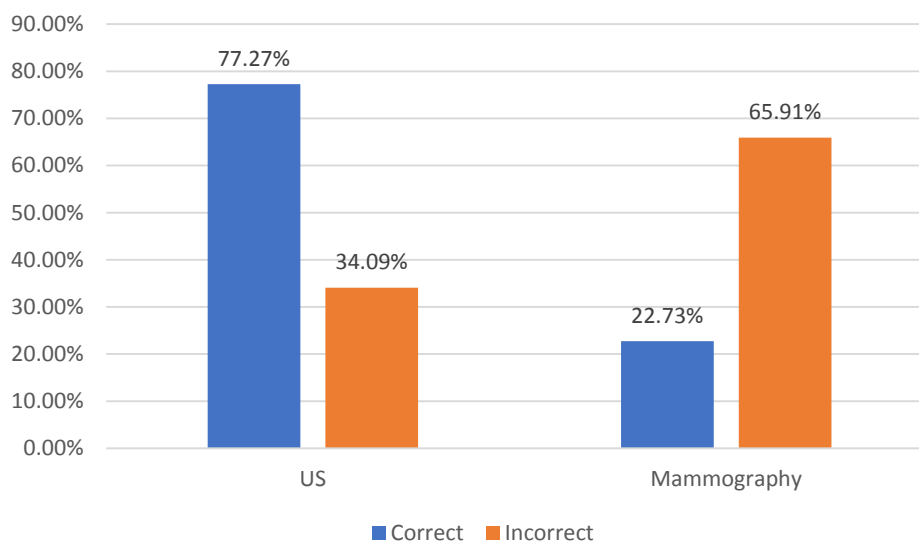


Figure 6 Overall accuracy of US and mammography in diagnosing more than one focus breast cancer

CONCLUSION

Around two thirds of the cases with bilateral, multifocal and/or multicentric cancers have areas of density that increases the need for ultrasound to accurately exclude the presence of mammography occult focus. Since this disease entity is prevalent in young age with dense breast, and breast density is increasing due to many factors, we recommend the use of ABUS in the national screening programs for early detection and hence better prognosis with longer disease-free interval.

As the US itself doesn't reach very high level of efficacy in evaluation of breast cancer with more than one focus, MRI has to be considered in management of these patients for better diagnosis, management and hence prognosis.

DECLARATIONS

Conflict of Interest

The authors and planners have disclosed no potential conflicts of interest, financial or otherwise.

REFERENCES

- [1] Fredholm, Hanna, et al. "Breast cancer in young women: poor survival despite intensive treatment." *PloS one* Vol. 4, No. 11, 2009, p. e7695.
- [2] Inciardi, M. M. D. "Breast Ultrasound: What's New in 2013." *Imaging Technology News* Vol. 10, 2012, pp. 39-41.
- [3] Jacob J. "Dense breast tissue: Supplemental screening." *Imaging Technology News* Vol. 11, 2012, pp. 46-49.
- [4] Tot, Tibor, et al. "Breast cancer multifocality, disease extent, and survival." *Human Pathology* Vol. 42, No. 11, 2011, pp. 1761-69.
- [5] Weissenbacher, Tobias M., et al. "Multicentric and multifocal versus unifocal breast cancer: is the tumor-node-metastasis classification justified?" *Breast Cancer Research and Treatment* Vol. 122, No. 1, 2010, pp. 27-34.
- [6] White, Judith. "Breast density and cancer risk: What is the relationship?" *Journal of the National Cancer Institute* Vol. 92, No. 6, 2000, p. 443.
- [7] Ziv, Elad, et al. "Mammographic breast density and family history of breast cancer." *Journal of the National Cancer Institute* Vol. 95, No. 7, 2003, pp. 556-58.

-
- [8] Qureshi, Samera Azeem, et al. "Physical activity and mammographic density in a cohort of postmenopausal Norwegian women; a cross-sectional study." *SpringerPlus* Vol. 1, No. 1, 2012, p. 75.
- [9] Irwin, Melinda L., et al. "Physical activity, body mass index, and mammographic density in postmenopausal breast cancer survivors." *Journal of Clinical Oncology* Vol. 25, No. 9, 2007, pp. 1061-66.
- [10] Trinh, Thang, et al. "Background risk of breast cancer and the association between physical activity and mammographic density." *Breast Cancer Research* Vol. 17, No. 1, 2015, p. 50.
- [11] Clemons, Mark, and Paul Goss. "Estrogen and the risk of breast cancer." *New England Journal of Medicine* Vol. 344, No. 4, 2001, pp. 276-85.
- [12] Friedenreich, Christine M., and Anne E. Cust. "Physical activity and breast cancer risk: impact of timing, type and dose of activity and population subgroup effects." *British Journal of Sports Medicine* Vol. 42, No. 8, 2008, pp. 636-47.
- [13] Checka, Cristina M., et al. "The relationship of mammographic density and age: implications for breast cancer screening." *American Journal of Roentgenology* Vol. 198, No. 3, 2012, pp. W292-W295.
- [14] Pisano, Etta D., et al. "Diagnostic performance of digital versus film mammography for breast-cancer screening." *New England Journal of Medicine* Vol. 2005, No. 353, 2005, pp. 1773-83.
- [15] Lynch, S. P., et al. "Multifocality and multicentricity in breast cancer and survival outcomes." *Annals of Oncology* Vol. 23, No. 12, 2012, pp. 3063-69.
- [16] Houssami, Nehmat, et al. "Accuracy and surgical impact of magnetic resonance imaging in breast cancer staging: systematic review and meta-analysis in detection of multifocal and multicentric cancer." *Journal of Clinical Oncology* Vol. 26, No. 19, 2008, pp. 3248-58.
- [17] Dawson, L.A., E. Chow, and P.E. Goss. "Evolving perspectives in contralateral breast cancer." *European Journal of Cancer* Vol. 34, No. 13, 1998, pp. 2000-09.
- [18] Yerushalmi, Rinat, et al. "Does multicentric/multifocal breast cancer differ from unifocal breast cancer? An analysis of survival and contralateral breast cancer incidence." *Breast Cancer Research and Treatment* Vol. 117, No. 2, 2009, pp. 365-70.
- [19] Weissenbacher, Tobias M., et al. "Multicentric and multifocal versus unifocal breast cancer: is the tumor-node-metastasis classification justified?" *Breast Cancer Research and Treatment* Vol. 122, No. 1, 2010, pp. 27-34.
- [20] Takahashi, Hiromasa, et al. "The impact of bilateral breast cancer on the prognosis of breast cancer: a comparative study with unilateral breast cancer." *Breast Cancer* Vol. 12, No. 3, 2005, pp. 196-202.
- [21] Chae, Eun Young, et al. "Evaluation of Screening Whole-Breast Sonography as a Supplemental Tool in Conjunction with Mammography in Women with Dense Breasts." *Journal of Ultrasound in Medicine* Vol. 32, No. 9, 2013, pp. 1573-78.
- [22] Zhao, Hong, et al. "Limitations of mammography in the diagnosis of breast diseases compared with ultrasonography: a single-center retrospective analysis of 274 cases." *European Journal of Medical Research* Vol. 20, No. 1, 2015, p. 49.
- [23] Carney, Patricia A., et al. "Individual and combined effects of age, breast density, and hormone replacement therapy use on the accuracy of screening mammography." *Annals of Internal Medicine* Vol. 138, No. 3, 2003, pp. 168-75.
- [24] Kelly, Kevin M., et al. "Breast cancer detection using automated whole breast ultrasound and mammography in radiographically dense breasts." *European Radiology* Vol. 20, No. 3, 2010, pp. 734-42.
- [25] Gordon, Paula B. "Ultrasound for breast cancer screening and staging." *Radiologic Clinics* Vol. 40, No. 3, 2002, pp. 431-41.
- [26] Brem, Rachel F., et al. "Screening breast ultrasound: past, present, and future." *American Journal of Roentgenology* Vol. 204, No. 2, 2015, pp. 234-40.