



## A Rare Case of Second Trimester Uterine Rupture in Unscarred Uterus

Poonam Kashyap<sup>1\*</sup>, Sudha Prasad<sup>2</sup> and Chandra Bhushan Singh<sup>3</sup>

<sup>1</sup> Specialist, Obstetrics and Gynecology, Lok Nayak Hospital, New Delhi, India

<sup>2</sup> Professor, Obstetrics and Gynecology, Maulana Azad Medical College and Lok Nayak Hospital, New Delhi, India

<sup>3</sup> Professor of Surgery, Maulana Azad Medical College & Lok Nayak Hospital, New Delhi, India

\*Corresponding e-mail: [drpoonamkashyap@gmail.com](mailto:drpoonamkashyap@gmail.com)

### ABSTRACT

Second trimester uterine rupture is rare and presents with life threatening emergency. Few cases have been reported in literature. Most of the cases which have been reported are with the use of labor-induction agents in late termination of pregnancy. Others are involving any surgical procedures in placenta percreta or scarred uterus. The main contributory factors were scarred uterus and abnormal placentation. In this study, uterine rupture had occurred in unscarred uterus in non-laboring women in second trimester without any intervention which is very rare to found. The lack of index of high suspicion diverts attention to search for other non-gynecological causes. Our aim is to create awareness through this case study to avoid delay in diagnosis and timely management of such cases.

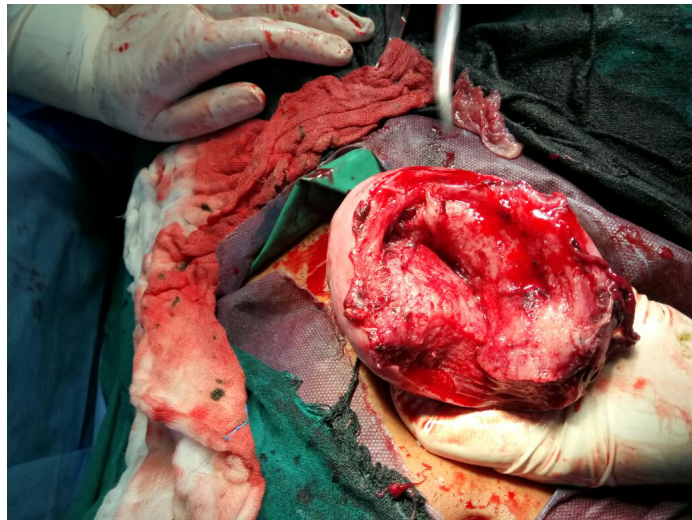
**Keywords:** Placenta increta, Acute abdomen, Hemoperitoneum, Pregnancy

### INTRODUCTION

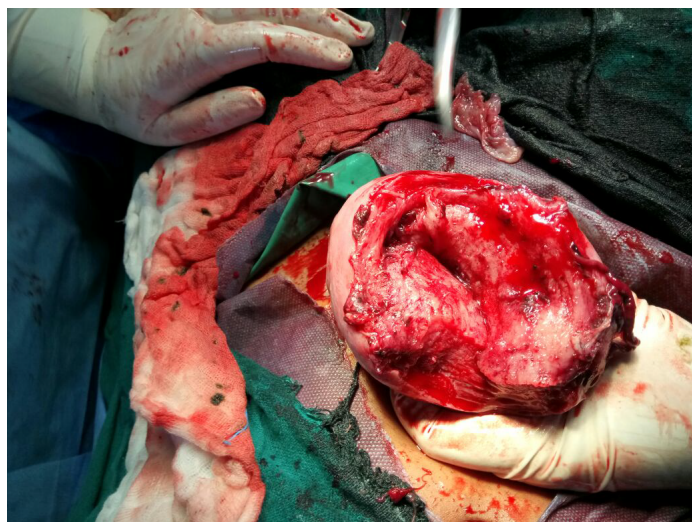Uterine rupture is a rare life-threatening complication. It mainly occurs in the third trimester of pregnancy and is rarely seen during the first or second trimesters or in unscarred uterus. Advanced maternal age, multiparity, placenta increta, macrosomia, shoulder dystocia and medical termination of pregnancy are some other important contributing factors to this condition. The overall incidence of rupture uterus in unscarred uterus and scarred uterus varies from 0.7 and 5.1 per 10,000 deliveries respectively [1]. In this study, the patient had gastroenterological symptoms leading to delay in diagnosis. The clinical symptoms of rupture uterus may vary. The ultrasonological finding of intrauterine pregnancy with free fluid in abdominal cavity do not exclude uterine rupture or ectopic pregnancy [2]. Crucial time may be lost in searching for other non-obstetric causes.

### CASE PRESENTATION

This patient is G3P2L2A1 with 26 weeks of pregnancy, presented with complaints of acute pain abdomen in casualty. She had no complaints of discharge or bleeding per vaginum. Her pulse rate was 100/min, BP was 100/60 mm of Hg. Respiratory rate was 24/min. SPO<sub>2</sub> was 100%. She was given intravenous I.V. fluids and injection ranitidine were given but her symptoms did not improve. Her ultrasound was done and referral from surgery was taken to rule out surgical cause. Her vitals deteriorated, and patient was unstable. Patient had become pale, there was evidence of free fluid in abdomen in ultrasound. Patient was taken for laparotomy. On opening the abdomen, there was hemoperitoneum, and 12 cm transfundal rupture of the uterus was found (Figures 1 and 2). The foetus was outside the uterus and placenta was seen lying inside the uterine cavity. There was hemoperitoneum of 1.5 liters. Uterine repair was done with two layers using No.1 vicryl. Bilateral tubes and ovaries were healthy. The abdomen was closed with an intraperitoneal drainage tube. The total blood loss was estimated to be about 2.5 L, and she was given adequate packed cells.



**Figure 1** Laparotomy showing rupture of the uterine fundus



**Figure 2** Uterine ruptured at fundus

The patient recovered well with no postoperative complications. She was discharged, and was asked to be regular for a follow-up. The patient's current condition was explained to her. As she was willing for tubal ligation, her ligation was done.

### **DISCUSSION**

The various causes of rupture uterus in second trimester are scarred uterus, morbidly adherent placenta, grand multipara, medical induction. Uterine rupture is extremely rare in second trimester of pregnancy in unscarred uterus and is usually diagnosed intra-operatively [3,4]. This study aimed to highlight various presentations and course of events that subsequently result in diagnostic and decision-making difficulties. The various misleading factors such as severe epigastric pain leading to delay in diagnosis and management. On laparotomy, there was transfundal rupture of the uterus in unscarred uterus. This probably was due to dilatation and curettage in first trimester of pregnancy damaging the endometrium. This highlights the importance of evaluating complete medical history of the patient and history of any procedures or surgery done in the past. The complete record of any procedures or surgery should also be preserved.

The usual site of rupture in second trimester is fundal region unlike lower uterine segment in third trimester [5]. Ultrasound diagnosis of intrauterine pregnancy along with fluid collection does not necessarily mean intact uterus [6].

Other non-gynecological and non-obstetric causes such as perforation of bowel, acute appendicitis, acute pancreatitis, rupture aortic aneurysm should also be considered and ruled out before making a definitive diagnosis [7]. This study emphasizes the difficulties in early diagnosis and management in cases of rupture uterus in unscarred uterus in non-laboring women. This study also highlights the reliability on clinical suspicion and ultrasound finding for making a diagnosis.

#### CONCLUSION

Spontaneous uterine rupture in second trimester of pregnancy are very rare and is an obstetric emergency which is difficult to diagnose. The maternal and fetal prognosis depends on awareness of risk factors, recognition of clinical signs and symptoms, availability of ultrasound for making a diagnosis and prompt surgical management.

#### DECLARATIONS

##### Conflict of interest

The authors have disclosed no potential conflicts of interest, financial or otherwise.

##### Consent

Written informed consent was obtained from the patient for publication of this case report and accompanying images.

#### REFERENCES

- [1] Abdulwahab, Dalia F., Hamizah Ismail, and Zalina Nusee. "Second-trimester uterine rupture: lessons learnt." *The Malaysian Journal of Medical Sciences: MJMS* Vol. 21, No. 4, 2014, p. 61.
- [2] Smith, J. F., and J. R. Wax. "Rupture of the unscarred uterus". UpToDate. 2013."
- [3] Park, Young-Joon, et al. "Spontaneous uterine rupture in the first trimester: A case report." *Journal of Korean Medical Science* Vol. 20, No. 6, 2005, pp. 1079-81.
- [4] Schrimsky, Daniel C., and Ralph C. Benson. "Rupture of the pregnant uterus: A review." *Obstetrical & Gynecological Survey* Vol. 33, No. 4, 1978, pp. 217-32.
- [5] Vaknin, Zvi, et al. "Clinical, sonographic, and epidemiologic features of second-and early third-trimester spontaneous antepartum uterine rupture: a cohort study." *Prenatal Diagnosis* Vol. 28, No. 6, 2008, pp. 478-84.
- [6] Acton, Christine, Vanessa King, and Julie Whitehead. "Sonographic diagnosis of uterine rupture with a successful outcome." *Australian and New Zealand Journal of Obstetrics and Gynaecology* Vol. 44, No. 5, 2004, pp. 473-74.
- [7] Hill, Christina C., and Jennifer Pickinpaugh. "Trauma and surgical emergencies in the obstetric patient." *Surgical Clinics of North America* Vol. 88, No. 2, 2008, pp. 421-40.