

“Case report: variant popliteal artery found in routine dissection in K.J.Somaiya Medical College,Mumbai.”

Dr. Sharadkumar Pralhad Sawant¹, Dr. Shaguphta T. Shaikh², Dr. Rakhi M. More³

^{1,2,3}Department of Anatomy, K. J. Somaiya Medical College,
Eastern Express Highway, Sion, Mumbai-400 022.

Corresponding author : Dr.Sharadkumar Sawant E-mail: dr.sharadsawant@yahoo.com

ABSTRACT:

During routine dissection for first MBBS students on 65 years donated embalmed male cadaver in the Department of Anatomy, K.J.Somaiya Medical College, we observed the high origin of anterior tibial artery from the popliteal artery proximal to the popliteus muscle. The anterior tibial artery ran downward on the posterior surface of the popliteus muscle. The posterior peroneotibial trunk distal to the tendinous arch of soleus muscle divides into the posterior tibial and the peroneal arteries. The further course of anterior, posterior tibial and peroneal arteries was normal. The photographs of the variations were taken for proper documentation and ready reference. There were no associated neuromuscular variations found in same specimen. The right lower limb of the same cadaver was normal.

Key words: Popliteal Artery, Anterior Tibial Artery.

Introduction:

The popliteal artery is the continuation of the femoral artery (1).The popliteal artery may divide proximal to the lower border of popliteal muscle. This is called as 'high division of the popliteal artery'. In high division, the anterior or posterior branch may arise at or above the articular surface of the tibial plateau (2). When the popliteal artery divides any where proximal to the lower border of the muscle, it is termed as 'high division of the popliteal artery' (3). The anterior tibial artery runs downwards on the posterior surface of the popliteus muscle and then it enters in to the anterior compartment of the leg through the oval space located at the superior border of the interosseous membrane of the leg. The variations in the branching pattern of the popliteal artery increase the risk of vascular trauma and unnecessary haemorrhage during arthroscopic surgery of knee joint. Preoperative diagnosis of variations in the branching pattern of the popliteal artery may help to avoid excessive unwanted haemorrhage and

unnecessary complications during surgery (5). The knowledge of variations in the branching patten of the limb arteries are important for the success of the arthroscopic surgeries.

Case Report:

During routine dissection for first MBBS students on 65 years donated embalmed male cadaver in the Department of Anatomy, K.J.Somaiya Medical College, we observed the origin of anterior tibial artery from the popliteal artery proximal to the popliteus muscle. The popliteal artery immediately below the adductor hiatus terminated into anterior tibial artery and perineotibial trunk. The termination level of the popliteal artery was proximal to the upper border of the popliteus muscle. The anterior tibial artery ran downwards on the posterior surface of the popliteus muscle and then it entered in to the anterior compartment of the leg through the oval space located at the superior border of the interosseous membrane of leg. There it traveled downwards on the anterior surface of the interosseous membrane along with the deep peroneal nerve. The posterior peroneotibial

trunk distal to the tendinous arch of soleus muscle divided into the posterior tibial and the peroneal arteries. The rest of the course of anterior, posterior tibial and peroneal arteries was normal. The photographs of the variations were taken for proper documentation and ready reference. There were no associated neuromuscular variations found in same specimen. The right lower limb of the same cadaver was normal.

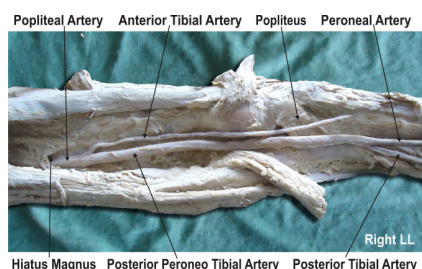


Figure : The photographic presentation of the variant popliteal artery terminated immediately below the adductor hiatus into anterior tibial artery and peroneotibial trunk.

Discussion:

The variations in the branching pattern of the popliteal artery are very common. The high level termination of the popliteal artery in relation to the upper border of the popliteus muscle was grouped into 3 types by Adachi. In type I the popliteal artery descended on the posterior surface of the popliteus muscle. The popliteal artery divides into the posterior peroneotibial trunk and the anterior tibial artery. The posterior peroneotibial trunk further divides into the peroneal artery and the posterior tibial artery. The diameter of the anterior tibial artery was equal to the popliteal artery or smaller than the posterior peroneotibial trunk. In type II the popliteal artery descended on the posterior surface of the popliteus muscle. It was divided into the posterior tibial artery and the anterior peroneotibial trunk. The diameter of the anterior peroneotibial trunk was

observed to be larger. The anterior peroneotibial trunk divided into the peroneal artery and anterior tibial artery at the lower border of the popliteus muscle. In type III the popliteal artery terminated into the anterior tibial artery and posterior peroneotibial trunk at the upper border of the popliteus muscle. The anterior tibial artery ran downward in between the anterior surface of the popliteus muscle and the posterior surface of the tibia. The posterior peroneotibial trunk ran on the posterior surface of the popliteus muscle. The posterior peroneotibial trunk divided into the peroneal artery and posterior tibial artery distal to the tendinous arch of soleus muscle (2). The variation in the termination of popliteal artery observed in the present case is of Adachi's type III. The high origin of anterior tibial artery at or above the level of the articular surface of the tibial plateau is documented in literature (6, 7, 8, and 9). Another radiological study of the femoral angiograms on 495 lower extremities was performed to view the tibial arterial anatomy, and found that 7.8% of the cases revealed variations (4). Normally the diameter of the posterior tibial artery is more than the diameter of the peroneal artery, but in present case the diameter of the peroneal artery was more than the diameter of the posterior tibial artery which is similar to the study of Ozgur et al (8). It was reported in previous studies that the course of anterior tibial artery could either be from the anterior or posterior surface of the popliteus muscle (6, 7, and 10). The course of anterior tibial artery on the anterior surface of the popliteus muscle was observed in 1-2.1% of the cases (2, 3, 5, 7, 9, and 10). The course of anterior tibial artery on the posterior surface of the popliteus muscle was observed in 40% of the cases. In present case the course of anterior tibial artery on the posterior surface of the popliteus muscle was observed. Clinicians and radiologists have defined a different terminology of the popliteal artery and its main branches in

popliteal surgery. The anterior tibial artery was defined as the tibial-fibular trunk as soon as it branched from the popliteal artery (6). The tibial arteries were referred to as anterior or posterior peroneotibial trunk depending upon the origin of the peroneal artery (2). In the present case the peroneal artery arises from the posterior tibial artery and hence the posterior tibial artery is defined as the tibial – fibular trunk.

Conclusion: The knowledge of branching pattern of the popliteal artery is important for surgical interventions in the popliteal region in order to minimize the surgical complications due to anatomical variations.

Acknowledgement:

All the authors wish to convey thanks to Dr. Arif A. Faruqui for his valuable support. We are also thankful to Mr. M. Murugan.

References:

1. Standring S, ed. Gray's Anatomy. 40th Ed., London, Churchill Livingstone. 2008; 1408, 1424.
2. Adachi B. Das Arteriensystem der Japaner, band 2. Kyoto, Kenkyusha. 1928; 198–201.
3. Lippert H, Pabst R. Arterial variations in man: classification and frequency. Munchen, J. F. Bergman Verlag. 1985; 62.
4. Kim D, Orron DE, Skillman JJ. Surgical significance of popliteal arterial variants. A unified angiographic classification. *Ann. Surg.* 1989; 210: 776–781.
5. Klecker RJ, Winalski CS, Aliabadi P, Minas T. The aberrant anterior tibial artery: magnetic resonance appearance, prevalence, and surgical implications. *Am J Sports Med.* 2008; 36: 720–727.
6. Day CP, Orme R. Popliteal artery branching patterns -- an angiographic study. *Clin Radiol.* 2006; 61: 696–699.
7. Kil SW, Jung GS. Anatomical variations of the popliteal artery and its tibial branches: analysis in 1242 extremities. *Cardiovasc Intervent Radiol.* 2009; 32: 233–240.
8. Ozgur Z, Ucerler H, Aktan Ikiz ZA. Branching patterns of the popliteal artery and its clinical importance. *Surg Radiol Anat.* 2009; 31: 357–362.
9. Tindall AJ, Shetty AA, James KD, Middleton A, Fernando KW. Prevalence and surgical significance of a high-origin anterior tibial artery. *J Orthop Surg (Hong Kong).* 2006; 14: 13–16.
10. Trotter M. The level of termination of the popliteal artery in the white and the Negro. *Am J Phys Anthropol.* 1940; 27: 109–118.

Source of support: Nil; Conflict of Interest: Nil

Date of submission: 11 Oct 2012

Date of Provisional Acceptance: 24 Oct 2012

Date of Peer review approval: 28 Nov 2012

Date of final drafting: 29 November 2012

Date of Publication: 2 December 2012