

“Review: Characterization of Denture Bases -Redefining Complete Denture Esthetics”

Dr.Sanjay Lagdive¹,Dr.Abhishek Darekar², Dr.Sushma Lagdive³

¹ Professor , Dept. of Prosthodontics,, Govt. Dental College & Hospital., Ahmedabad.(Gujarat) ,India

² Senior Lecturer,Dept. of Prosthodontics,, M.G.V. Dental College &Hospital, Nashik(Maharashtra),India

Corresponding author: Dr.Sanjay Lagdive ,Email: lagdive_san@yahoo.co.in, Mobile: 09978713061

Abstract:

Esthetics plays a vital role in rehabilitation of complete dentures to achieve a pleasant smile. Denture esthetics is the effect produced , which improves beauty and attractiveness of a person. In the era of implants and ceramics, the conventional denture needs to be updated. denture characterization is must in avoiding denture look and giving natural look. Only changes in tooth arrangement is not sufficient this article is an attempt to highlight various methods of denture base characterization in order to improve one’s personality. Present review outlines methods of improving the aesthetics of complete dentures with the aim of constructing dentures which are both functional and have a natural appearance. This will require very close collaborative teamwork involving the dentist, technician and the patient. With practice, the techniques described can be incorporated into treatment procedures with relative ease and, results in better acceptance of the denture by the patient.

Key words: denture characterization, denture look, denture esthetics

Introduction:

A *pleasant smile* is an expression of joy. A smile is a uniquely human gesture that is unlike the grimace of lower primates.It is the dentist’s responsibility to preserve, enhance or create a pleasing smile through dental treatment without impairing function. The dentition and how it influences the formation of a pleasing smile is extremely important in the *emotional development* of the individual. Characterized dentures plays a vital role in improving one’s confidence and there by allowing them to smile freely. ^[1]

Dentogenics and dynaesthetic principles are the mile stones of complete denture esthetics. Though the complete denture esthetics remarkably improved in last 15 years but further improvement is necessary.

Denture characterization is simply defined as the

Modification of the form and color of denture base and or teeth to produce more life like appearance.(Fig.1)

Characterization by contouring the denture base:

Festooning -The papillae and marginal gingiva are smooth, as is the alveolar mucosa; but the band of attached gingiva in between is described as having a stippled or orange-peel appearance. The contour of the gingiva presents a festooned appearance with intermittent elongated prominences corresponding to the root contours.(**Fig. 2**) It is recommended that casts from patients with natural teeth be used as guides for gingival waxing and festooning, rather than simply making grooves in the wax between each tooth. Without festooning and stippling, light is not randomly reflected and dispersed and the denture becomes a smooth, pink mirror announcing itself as an impostor.^[2]

Stippling-Stippling of the areas representing the attached gingiva may be accomplished in a variety of ways, The result is natural looking, positive stippling which seems to collect less debris and calculus, and is easier to clean than the indentations made by negative stippling techniques. If the positive stippling is to be preserved in the finished denture, care must be taken in waxing the denture to the proper thickness and finishing and polishing the denture after processing^[2]

(**Fig. 3**) various methods are used popular methods are^[3]

- 1) toothbrush technique.
- 2) offset bur technique.
- 3) blow wax technique.

toothbrush technique.

- press the bristles of toothbrush against the surface of wax denture pattern prior to it's investment.
- This produces a large number of holes in the wax. The wax is then lightly flamed so the holes become less pronounced and form dimples.
- controlling the depth of holes and the size and shape of dimples is difficult.

Limitations-

- Investment material may trapped within the pits, and this is difficult to clean out.
- The most difficult problem with a toothbrush technique is polishing to the depth of dimples, which is practically impossible.
- As a result, it is difficult for the patient to keep the dentures completely clean. Plaque and calculus form rapidly, giving the dentures an odor.

Offset bur technique-

This technique utilizes a bur (**Fig. 4**) which has been offset bending the shank of the round bur (size Nos. 4 to 8), placing it in a handpiece, and wiping the bur over the denture in somewhat circular movement while the handpiece is running.

Limitations-

- It is difficult to control the depth of the bur cuts.
- The dimples are usually linear in shape, rather than rounded.
- The bur tends to scratch the surface of the denture base making it difficult to polish.
- This technique results in the same kind of problems for the patient as produced in the toothbrush technique.
- These technique do produce an esthetic result, however short-lived.

Blow wax technique

- Contour the denture base in the usual manner, with simulated root eminences, accurately placed gingival margins, and the removal of all wax from the teeth. Smooth the wax, and polish it to free it of all defects.
- Paint the teeth with die lubricant to prevent the wax from adhering to them. Care should be taken to cover the entire tooth surface, including the gingival crevice and the surface.
- Heat the large end of the No. 7 spatula, and place it in a pink wax, and allow the wax to "pool" on the spatula.
- Reheat the spatula carrying the wax to make the certain the wax is in a very molten state.
- Hold the spatula 6 to 8 inches from the wax of the denture base, and with your mouth, blow heavily on the molten wax to move it toward the denture base pattern.

Custom denture tinting

Previous color characterization techniques have generally involved applying gingival stains to the gingival surfaces in the flask after boil-out^[4,5]. In the present technique, color characterization may be done by the dentist or technician after the denture has been processed. **(Fig. 5)** Custom staining can be done quickly and requires the following armamentarium^[6]:

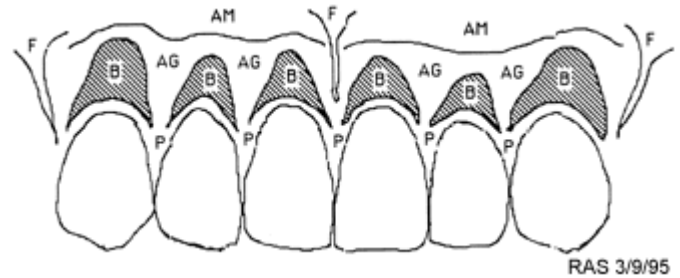
- Denture tinting chart.
- Soft tissue shade guide.
- #6 camel hair brush.
- Acrylic resin stains or shade modifiers in a variety of colors including red, brown and black.
- Dappen dishes
- Pressure pot or a light curing unit for curing the stains.

Newer, autopolymerizing and light-cured shade modifiers are cadmium-free and are preferred^[8]. When the the denture has been processed in the appropriate shade of denture base material, it is contoured and smoothed with an acrylic bur but not polished. Custom tinting is done at this time. An example of a typical procedure for a Caucasian is as follows^[9]:

1. Place monomer and colored powders in different dappen dishes.
2. Brush monomer on surfaces to be tinted.
3. Wet brush and pick up increments of pale pink powder (or gingival toner) and apply to the blanching areas over root prominences.
4. Clean the brush and place red stain on the alveolar mucosa and frenum attachments.
5. The unattached and attached gingiva and the papillae remain as unstained denture base material.
6. Keep stains moist with the monomer during this

time to prevent crystallization.

7. Cure the acrylic resin stains in the pressure pot or light-curing unit according to the manufacturers instructions



Denture tissue tinting chart with areas to be tinted and shades selected^[10].

AG = Attached Gingiva	Shade <u>Light reddish pink</u>
AM = Alveolar Mucosa	Shade <u>Reddish pink</u>
B = Blanched areas over roots	Shade <u>Pale pink</u>
F = Frenum Attachments	Shade <u>Red stain</u>
P = Papillae	Shade <u>Light reddish pink</u>

Soft tissue shade guide (Fig. 6)

The soft tissue shade guide is used to select a denture base material which is most representative of each patient's tissues. This is done at the appointment when the artificial teeth are selected. Using this same shade guide, other tissue colors and unusual characteristics, i.e., blotches of melanin, are also recorded on the denture tinting chart^[11].

Photocured denture coating

Previous color characterization techniques rarely recommended surface staining of finished dentures with autopolymerizing acrylic resin stains because of the lack of color stability and the lack of abrasion resistance of these stains. However, applying stains to the gingival surfaces in the flask before packing has a major disadvantage. If any reshaping of these surfaces is required after processing, the stains are lost in finishing and in polishing. In this technique, surface staining of finished dentures is possible because of clear, light-cured resin coatings.

The clear coating provides a hard, high gloss which makes the polishing of dentures unnecessary. The coating seals the surface which promotes the color stability of the base and the stains. Abrasion resistance of the denture base and custom staining should be greatly improved. It is claimed that the coatings render the denture more wettable and retentive, and that urethane coatings may prevent allergic responses to poly-methyl methacrylate; but these claims cannot be confirmed. The technique is as follows^[12]:

1. Lightly sand or sandblast the unpolished denture avoiding stained areas, then clean with detergent solution and dry with oil-free air.
2. Using a soft clean brush, apply the coating in a thin even film, painting in one direction only to avoid air bubbles. Do not brush a second time.
3. Polymerize in the manufacturer's laboratory light curing unit according to instructions. (Coatings and curing units from different manufacturers may be incompatible).

Light cured gum shading

It consist of micro filled composite resin , can be applied in multilayered technique and can delivers unlimited possibilities for gingival reproduction^[13].

1. Excellent mechanical and physical properties of a micro-filled composite.
2. Shades based on natural gingival tissue.
3. Lifelike esthetics.
4. Unlimited possibilities for gingival tissue reproduction.
5. Easy to polish and clean.

Conclusion:

This review outlines methods of improving the aesthetics of complete dentures with the aim of constructing dentures which are both functional and have a natural appearance. This will require very close collaborative

teamwork involving the dentist, technician and the patient. With practice, the techniques described can be incorporated into treatment procedures with relative ease and, results in better acceptance of the denture by the patient.

References:

1. Rosenthal RL, Kemper JT. The "blow-wax" technique for stippling dentures. *J Prosthet Dent* 1974;32:344-7
2. Bennett CC. Characterized immediate dentures. *J Prosthet Dent* 1961;11:648-56
3. Mathews T G: Anatomy of smile. *J. Prosthet Dent.* 39: 128, 1978.
4. Dummett CO. Normal variations in the clinical appearance of the gingivae. *J Dent Med* 1963;18:4-10
5. Zimmerman DE, Pomerantz JM, Sanfacon DG, Berger AW. Denture esthetics (III), Denture base color. *Quintessence Internat* 1982;7:747-58
6. Choudhary SC, Craig JF, Suls FJ. Characterizing the denture base for noncaucasian patients. *J Prosthet Dent* 1975;33:73-9
7. Jooste, C. Characterization of acrylic resin denture teeth. *J Prosthet Dent* 1992; 67:279-280
8. Johnson HD. Technique for packing and staining complete or partial denture bases. *J Prosthet Dent* 1956;6:154-9
9. Pound E. Esthetic dentures and their phonetic values. *J Prosthet Dent* 1951;1:98-111
10. Dummett CO. Psychogenic concomitants of oro-mucosal melano-pigmentation. *Q Natl Dent Assoc* 1968;27:14-21
11. Quinlivan JT. Characterization of denture bases. *Dent Clin North Am* 1975;19: 321-32
12. Szabo G, Stafford GD, Huggett R. Some mechanical properties of denture base polymers treated with an ultraviolet light-activated coating material. *J Dent Mat* 1987;15:261-265
13. www.gcamerica.com/lab-gradiagum.html

Legends for figures:

Fig.1 Characterized upper and lower dentures

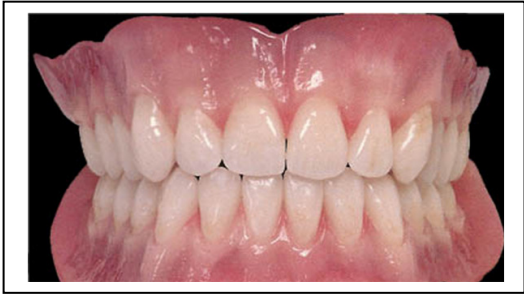

Fig.2 Festooned denture bases

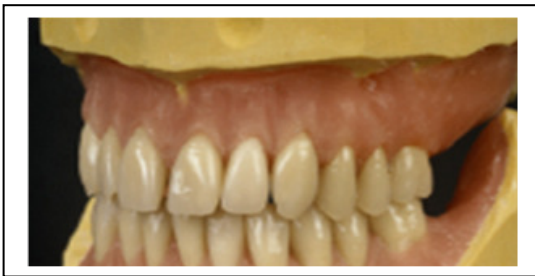

Fig.3 Stippled upper complete and lower partial denture

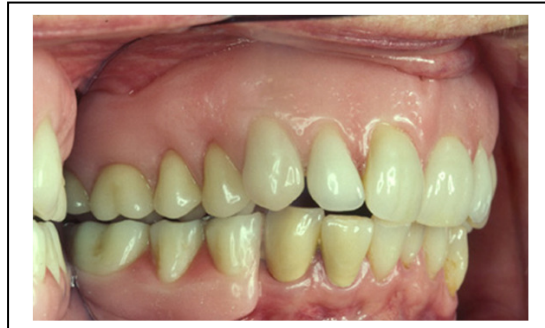

Fig. 4 Offset bur for stippling



Fig. 5 Tinted denture showing blotches of melanin

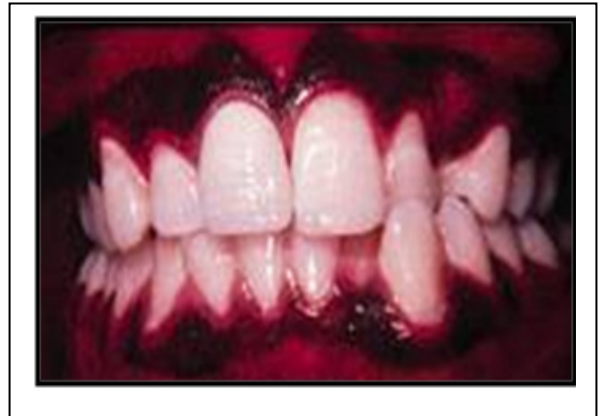

Fig. 6 Soft tissue shade guide



Submission of manuscript: 15 September 2012
Final acceptance: 4 October 2012
Date of Publication: 16 October 2012
Conflict of interest: Nil