

# Arterial Mycotic Aneurysm Rupture of Two Kidney Cadaveric Renal Transplantation Recipients Secondary to Enterococci and Candida

## *Enterokok ve Candida Enfeksiyonuna Bağlı Kadaverik Renal Transplantasyon Alıcısında Gelişen Arteriyel Mikotik Anevrizma Rüptürü*

### ABSTRACT

Although vascular complications due to the arterial anastomosis are rare in transplant patients, infectious vascular complications around the anastomosis site that carry a risk of rupture can cause significant mortality and morbidity. Signs and symptoms of any infectious process can be masked in patients taking more potent immunosuppressants at the early period after transplantation. Staphylococcus aureus, gram-negative bacilli, and fungi such as Candida albicans can especially produce serious complications. We present two renal transplant patients with an arterial anastomosis aneurysm leading to rupture. Early diagnosis may be life saving due to the silent and insidious presentation of arterial mycotic aneurysms and their high mortality and morbidity rates.

**KEY WORDS:** Kidney transplantation, Arterial mycotic aneurysm rupture

### ÖZ

Böbrek transplant hastalarında arteriyel anastomoz hatlarından kaynaklanan komplikasyonlar son zamanlarda oldukça nadir olsa da, anlamlı mortalite ve morbiditeye sebep olabilecek enfeksiyöz patolojiler hala görülebilmektedir. Transplant sonrası erken dönemde kullanılan güçlü immünespresif ilaçlar, klinik bulgu ve semptomları maskeleyebilmektedir. Özellikle Staphylococcus aureus, gram negatif basiller ve Candida albicans gibi mantarlar tehlikeli komplikasyonlar oluşturabilirler. Biz burada arteriyel anastomoz hattı enfeksiyonuna sekonder rüptür ile komplike olmuş iki transplant hastasını tartışacağız. Yüksek mortalite ve morbidite riski taşımaları sebebiyle, sessiz ve sinsi gidişatlı arteriyel mikotik anevrizmaların erken saptanması, hayat kurtarıcı olabilir.

**ANAHTAR SÖZCÜKLER:** Böbrek transplantasyonu, Arteriyel mikotik anevrizma rüptürü

### INTRODUCTION

Despite the advances in the surgical and medical care of transplant patients, infectious complications still have great importance. Signs or symptoms of any infectious process can be masked in patients taking more potent immunosuppressants at the early period after transplantation. We discuss two cases of mycotic aneurysm rupture due to enterococci and fungi in two stable renal transplant patients.

#### Case 1:

A 31-year-old man has received a kidney transplant from an 18-year-old man who died from brain injury. Cyclosporine following lymphoglobulin (anti-thymocyte human immunoglobulin, ATG), prednisone,

and mycophenolate mophetil (MMF) were started during the first seven days of the post-transplant period. The patient was discharged on the eleventh day of the post-transplant period with a creatinine level of 1.3 mg/dL. The patient was readmitted to the hospital within 24 hours of discharge with fever, agitation, flank and low back pain and abdominal bloating resembling acute abdomen. His arterial blood pressure was 70/40 mmHg and heart rate was 120/min. Ultrasound examination revealed perirenal and retroperitoneal hematoma. He was operated immediately and the graft was removed. A disrupted anastomosis between the iliac artery and renal artery due to an aneurysmal dilatation was observed during the surgery. The patient was reoperated four days later because of the sudden onset

Devrim BOZKURT<sup>1</sup>

Bilgin ARDA<sup>2</sup>

Sait ŞEN<sup>3</sup>

Mircelal KAZİMİ<sup>4</sup>

Cüneyt HOŞCOŞKUN<sup>4</sup>

Hüseyin TÖZ<sup>1</sup>

1 Ege University, Medical Faculty, Nephrology Department, İzmir, Turkey

2 Ege University, Medical Faculty, Infection Diseases Department, İzmir, Turkey

3 Ege University, Medical Faculty, Pathology Department, İzmir, Turkey

4 Ege University, Medical Faculty, General Surgery Department, İzmir, Turkey

Received : 25.07.2009

Accepted : 25.11.2009

Correspondence Address:

**Devrim BOZKURT**

Ege Üniversitesi Tıp Fak. Hastanesi,

İç Hastalıkları AD, Bornova

İzmir, Turkey

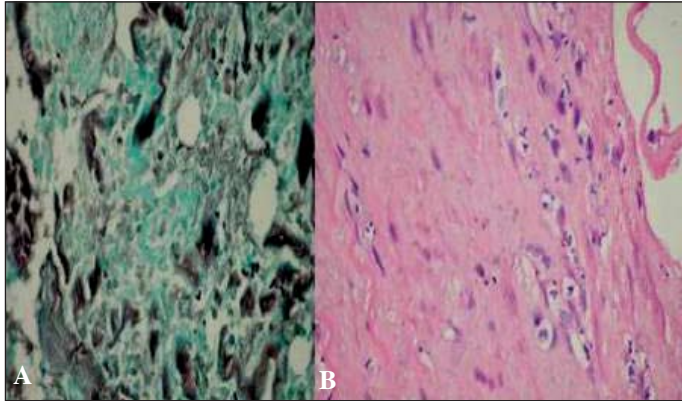
Phone : +90 232 390 35 50

Gsm : +90 533 715 27 17

Fax : +90 232 373 51 21

E-mail : devrim\_bozkurt@yahoo.com

of fever, tachycardia, hypotension and hemorrhagic shock. The anastomosis site was reconstituted due to delayed wound healing. Pathological and microbiological examination of tissue samples around the anastomosis site showed fungi and enterococci (Figure 1).



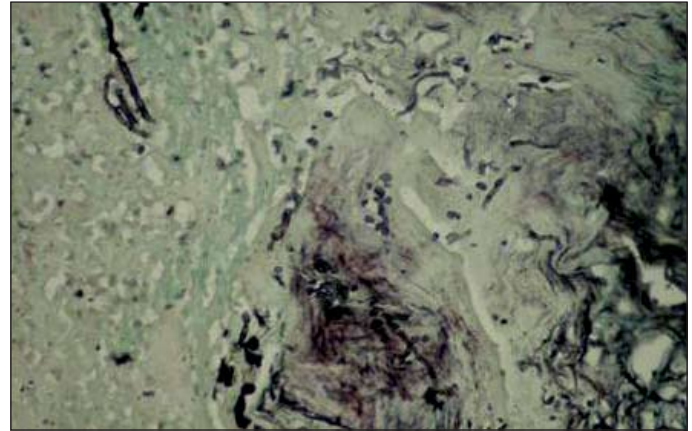
**Figure 1:** Spores of fungi (A) and arteritis (B) due to either fungi or enterococci, from arterial anastomosis line tissue samples.

#### Case 2:

A 47-year-old man with a 15-year history of insulin-dependent diabetes had been transplanted from a 21-year-old man who died from brain injury. The patient had delayed graft function during the postoperative course. The immunosuppressive regimen included ATG, MMF and prednisone. Urine and blood samples were taken for microbiological investigation on the 13th day of the post-transplant period because of fever. Fungi were found in the urine three days later. We did not consider anti-fungal treatment because of the excellent clinical outcome and graft conditions. However, fever, hypotension, tachycardia and abdominal distention appeared suddenly on the 18th day of the post-transplant period. Ultrasound revealed retroperitoneal and pelvic hematoma. The creatinine level was 1.43 mg/dL while the urine output and chemistry were normal. The patient was reoperated immediately. Rupture of arterial anastomosis line was diagnosed during surgery and the graft was promptly removed. Pathological studies on tissue samples from the anastomosis line revealed *Candida albicans* (Figure 2)

#### DISCUSSION

Infections are major complications in patients with solid organ transplantation. Mycotic aneurysms are rare but dangerous complications of the post-transplant period because of their insidious presentation and clinical course. Bijnen et al. reported that contamination of the donor kidney is a frequent event but serious complications are relatively rare. They found that 24% of the donor kidneys were contaminated in their retrospective study of 350 consecutive cadaveric renal transplants. Three



**Figure 2:** Spores and hyphae of *Candida albicans* from the arterial anastomosis line after graft nephrectomy.

patients lost their grafts and one patient died from septic complications. The graft survival of the remaining recipients of contaminated grafts after one year did not differ from that of the whole series (1). Fungal arteritis, although rare, can lead to fatal aneurysmal dilatation and rupture of the renal artery. Most require surgical intervention except occasional cases (2). The frequency of accidental contamination varies from between 5% and 23% (3). Fortunately, most of these are caused by flora with little pathogenic potential but bacteria such as *Staphylococcus aureus*, gram negative bacilli, or fungi such as *Candida albicans* have produced serious complications on some occasions (3-6).

Arterial complications after renal transplantation due to mycotic aneurysms made up only about 4% of total arterial complications in one series (7). These are caused by perinephric wound infection involving the iliac arteries (8) or infected donor kidneys. Donors who have cranioencephalic trauma accompanied by abdominal injury and have spent prolonged periods of more than 7 days in the intensive care unit (ICU), and harvesting of kidneys from non-heart beating donors are risk factors for infectious complications in the post-transplant period. Organ preservation and graft implantation with longer duration of surgery facilitates colonization of bacteria and fungi (9,10).

In our first case, the donor had stayed in the ICU for a prolonged period and had been hemodialyzed. In the other case, the comorbid conditions of the recipient such as a history of ischemic heart disease and diabetes may be the risk factors. Cold ischemia times were 19 and 18 hours respectively. More importantly, our aneurysmal complication in case 1 had no signs or symptoms before its insidious presentation. Unfortunately, a fungus in the urine sample in case 2 was misdiagnosed as contamination because of the stable clinical condition of the patient. Receiving ATG may enhance the risk for infectious complications. In our two cases we started the potent immunosuppressant ATG at the

early post-transplant period due to the long cold ischemia time that may cause delayed graft function under early calcineurin inhibitor therapy.

We believe that prolonged cold ischemia time and recipients who are more susceptible to infections due to diabetes or the other risk factors mentioned above should be considered candidates for mycotic aneurysms. Repeated magnetic nuclear resonance or Doppler ultrasound study to examine the vascular anastomosis should be performed and serial blood and urine culture samples must be obtained in this population during the few days following the transplantation. Routine microbiological examination of the perfusate solutions should be done after harvesting. The digestive tract may be source of fungi transmission during general anesthesia for organ implantation. Routine peritoneal irrigation with diluted betadine in such high-risk populations, especially when accompanied by abdominal trauma before brain death, may have therapeutic value. Immediate antifungal prophylaxis can also be considered depending on the radiological examination if there are any signs of candiduria despite the lack of any signs or symptoms of an infection.

A diagnosis of arterial aneurysm represents an emergency. Silent clinical progression of aneurysms should be kept in mind. Any unexpected finding during the early post-transplant period, especially in patients taking more potent immunosuppressive agents, should be carefully investigated as it may be a final clue. Generally there are no findings other than clinician's suspicion for early recognition of mycotic arterial aneurysms. Early diagnosis of this entity is very important as it can lead to life-threatening hemorrhage.

## REFERENCES

1. Bijnen AB, Weimar W, Bijlstra AM, Jeekel J: Infections after transplantation of a contaminated kidney. *Scand J Urol Nephrol Suppl* 1985; 92:49-51
2. Fujikata S, Tanji N, Iseda T, Ohoka H, Yokoyama M: Mycotic aneurysm of the renal transplant artery. *Int J Urol* 2006; 13(6):820-823
3. Calviño J, Romero R, Pintos E, Novoa D, Mardaras J, Arcocha V, Lens XM, Sanchez-Guisande D: Renal artery rupture secondary to pretransplantation Candida contamination of the graft in two different recipients. *Am J Kidney Dis* 1999; 33(1):E3
4. Garrido J, Lerma JL, Heras M, Labrador PJ, García P, Bondía A, Corbacho L, Taberner JM: Pseudoaneurysm of the iliac artery secondary to Aspergillus infection in two recipients of kidney transplants from the same donor. *Am J Kidney Dis* 2003; 41(2):488-492
5. Pluemecke G, Williams J, Elliott D, Paul LC: Renal transplant artery rupture secondary to Candida infection. *Nephron* 1992; 61(1):98-101
6. Taksin L, Mallick S, Frachet O, Julien M, Lepennec V, Ficheux M, Bensadoun H: Mycotic aneurysm and renal transplant. A case report. *Prog Urol*. 2009; 19(2):149-152
7. Jordan ML, Cook GT, Cardella CJ: Ten years of experience with vascular complications in renal transplantation. *J Urol* 1982; 128(4) 689-692
8. Renigers SA, Spigos DG: Pseudoaneurysm of the arterial anastomosis in a renal transplant. *AJR Am J Roentgenol* 1978; 131(3):525-526
9. Rubin RH: Nephrology forum infectious disease complications of renal transplantation. *Kidney Int* 1993; 44(1):221-236
10. Matignon M, Botterel F, Audard V, Dunogue B, Dahan K, Lang P, Bretagne S, Grimbert P: Outcome of renal transplantation in eight patients with Candida sp. contamination of preservation fluid. *Am J Transplant* 2008; 8(3):697-700