

# Successful Treatment of Refractory Acute Humoral Allograft Rejection with Single Dose Rituximab

## *Refrakter Akut Humoral Renal Allograft Rejeksiyonunun Tek Doz Rituximab ile Başarılı Tedavisi*

### ABSTRACT

Acute humoral rejection (AHR) is a rare event; however it can potentially lead to graft loss in up 40% of cases after 1 year of transplantation. A number of features like re-transplantation, ABO incompatibility and positive lymphocyte cross-match portend a high risk for AHR. We performed a retransplantation to a 23-year-old female patient who had lost her first allograft due to polyomavirus nephropathy. After the second transplantation, she developed AHR that was confirmed by allograft biopsy. We instituted steroid pulses for three days, alternate-day thymoglobulin, plasmapheresis and intravenous immunoglobulin. Despite this therapy, renal function did not improve; therefore as a last resort we administered single-dose rituximab. Later on the course her urine output increased and kidney function recovered. In conclusion, rituximab can be tried as a last line of therapy in refractory AHR episodes.

**KEYWORDS:** Refractory acute humoral rejection, Renal allograft, Rituximab

### ÖZ

Akut humoral rejeksiyon (AHR) nadir bir olaydır, ancak transplantasyondan 1 yıl sonrasında greft kayıplarının %40'ı kadarından sorumlu olabilir. Tekrarlayan transplantasyon, ABO kan grubu uyumsuzluğu ve pozitif lenfosit cross-match gibi bazı özellikler AHR için yüksek risk teşkil eder. İlk transplant böbreğini poliomavirüs enfeksiyonu nedeniyle kaybeden 23 yaşındaki kadın hastaya ikinci böbrek naklini yapıldı. Hastada nakil sonrası, böbrek biyopsisi ile konfirme edilen AHR gelişti. Üç gün boyunca günlük pulse steroid, günasıra timoglobulin ve plazmaferez uygulandı. Daha sonra IVIG verildi. Bu tedavilere rağmen böbrek fonksiyonları iyileşmedi. Son çare olarak hastaya tek doz rituximab uyguladık verildi. Hastanın idrar çıkışı ve fonksiyonları iyileşti. Sonuç olarak, refrakter AHR episodlarında rituximab son tedavi seçeneği olarak denenebilir.

**ANAHTAR SÖZCÜKLER:** Refrakter akut humoral rejeksiyon, Renal allograft, Rituximab

### INTRODUCTION

Acute humoral rejection (AHR) is a rare event but can potentially lead to graft loss in up 40% of cases after 1 year (1). Some patients have high-risk features for AHR which include being highly sensitized in the pretransplantation period, ABO incompatibility, historical and/or current cross match positivity, and retransplantation. Despite better tracking of these high-risk patients and pretransplantation desensitization therapy with high-dose intravenous immunoglobulin (IVIG) and plasmapheresis, AHR still occurs in some of these patients. When it occurs, it is generally treated with IVIG, plasmapheresis, thymoglobulin and high-dose corticosteroids. Some cases are

unresponsive to these standard treatment modalities. Rituximab is a chimeric anti CD 20 antibody (2). It was first used in the treatment of AHR by Becker et al. (3). Here we present a case of AHR which was resistant to steroids, plasmapheresis, IVIG and thymoglobulin.

### Case

A 23-year-old female patient, who had her first kidney transplantation from a deceased donor on May 2006 at another center, was considered as a suitable recipient for a deceased donor kidney transplantation at our institute. Her first kidney allograft had been lost due to polyoma virus nephropathy 10 months after transplantation. She had been given IVIG treatment at that time since clinical

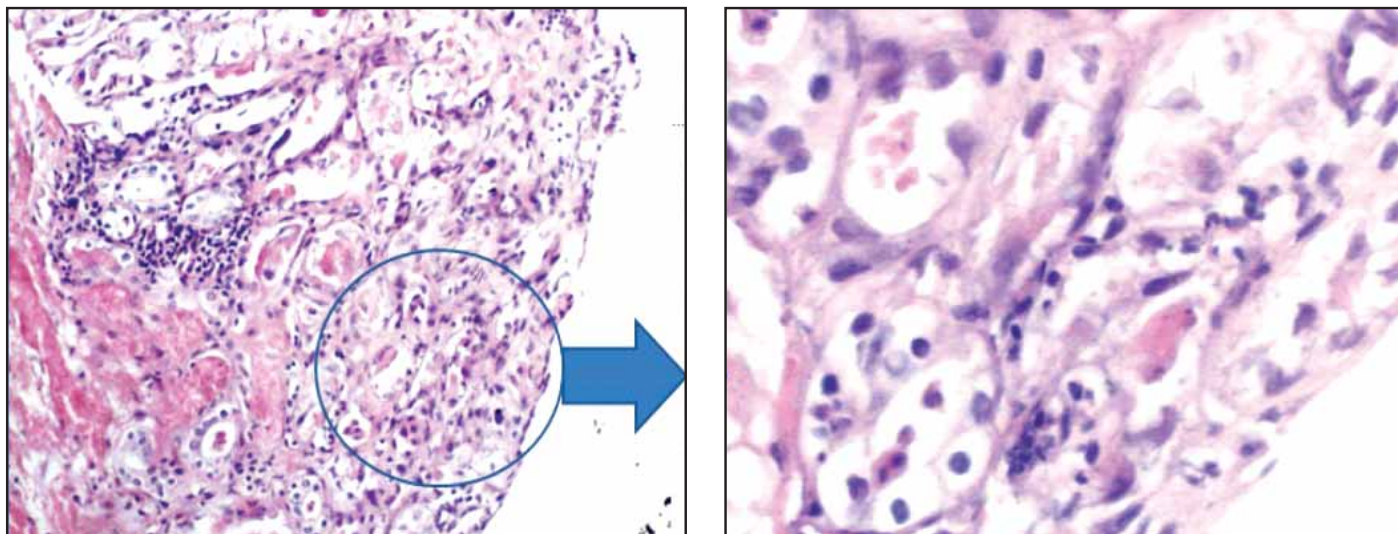
**Yalçın SOLAK**  
**Hüseyin ATALAY**  
**Süleyman TÜRK**

Selçuk University Meram Medical Faculty,  
Nephrology Department, Konya, Turkey

Received: 10.03.2010  
Accepted: 27.04.2010

Correspondence Address:

**Yalçın SOLAK**  
Selçuk Üniversitesi Meram Tıp Fakültesi,  
Hemodiyaliz Sekreterliği,  
Meram, 42080 Konya, Turkey  
Phone : +90 332 223 64 81  
E-mail : yalcinsolakmd@gmail.com

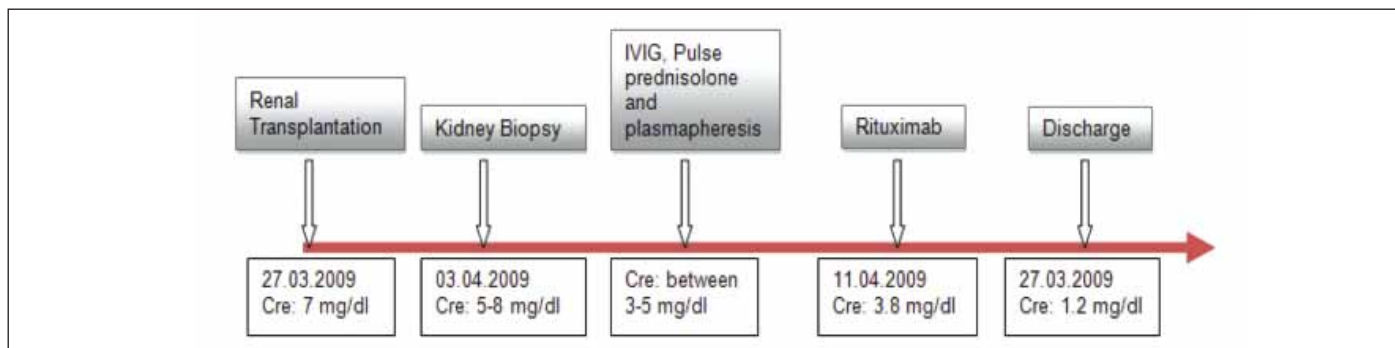


**Figure 1.** Figure panel shows acute tubular necrosis and polymorphonuclear leucocyte infiltration in and around the tubules on the left (H&E x100 magnification). Right side of the panel shows a closer look at the specimen in which PMNLs are seen between tubular epithelial cells (so-called tubulitis).

and biopsy findings could not be differentiated from rejection, but recovery of kidney functions was not achieved. She had been receiving hemodialysis (HD) for 1 year until the current renal transplantation that took place in April 2008. Her native kidney disease was unknown. In our case, a high-risk presensitized patient had been transplanted a deceased donor kidney and there was no delayed graft function. Pretransplantation B and T lymphocyte cross-matches performed via microlymphocytotoxicity method were negative. However, the panel reactive antibody (PRA) level was not determined prior to presentation despite a failed previous transplantation. Due to the high risk, we administered basiliximab as induction agent on post-transplantation days 0 and 4. Her standard immunosuppressive regimen included tacrolimus, mycophenolate mofetil, and corticosteroids. On the third post-transplant day, the urine output was diminished and her serum creatinine level started to rise. Duplex Doppler ultrasonography and scintigraphy studies ruled out obstruction and were consistent with a possible acute rejection episode. Allograft biopsy revealed polymorphonuclear leucocytes in

peritubular capillaries and extensive tubular damage consistent with acute humoral rejection (Figure1). C4d staining of the biopsy samples could not be performed due to institutional limitations at that time. After the diagnosis of AHR, one gram of pulse prednisone for 3 consecutive days, anti-thymocyte globulin (ATG) 2.5 mg/kg body weight and plasmapheresis with fresh frozen plasma on alternate days were administered. After a total of 7 doses of ATG and plasmapheresis treatment, we applied 3 doses of IVIG, 500 mg/kg body weight. Despite this intensive anti-rejection treatment, serum creatinine levels elevated progressively and she required intermittent HD due to uremia and volume overload. As a last resort, we gave a single dose of rituximab at a dose of 375 mg/m<sup>2</sup>. On follow-up her urine output started to increase and creatinine level returned to normal before discharge. Table I shows kidney functions before and after rituximab application. Subsequent renal doppler ultrasound and DTPA renal scintigraphy studies showed a normally functioning renal allograft.

**Table I.** Timeline showing major diagnostic and therapeutic milestones and corresponding serum creatinine values.



## DISCUSSION

Acute humoral rejection is a rare but serious event that can lead to transplant graft loss in the first year in up to 40% of cases (1). AHR is defined by three cardinal features: morphological evidence of acute tissue injury, circulating antibodies directed against donor specific alloantibodies (DSA) and immunopathological evidence of antibody mediation (c4d staining) (4). We were unable to perform c4d staining due to unavailability of the technique in our institution. Treatment options include plasmapheresis, high-dose corticosteroid pulses, and IVIG with varying success rate (4,5). Some of these antibody-mediated rejection episodes are refractory to conventional treatments. Becker et al. first reported successful treatment of such a steroid-resistant rejection episode with rituximab (6). Since then a number of case series and reports have been published with regards to success of rituximab in this particular indication (4,6). Rituximab is a chimeric murine/human anti CD 20 antibody which directly inhibits B cell proliferation by antibody-dependent, cell-mediated, and complement-mediated cytotoxicity (7). Although B cells have traditionally not been implicated in association with acute rejection, a study has demonstrated that unexpected large aggregates of CD 20-staining B cells in biopsies of patients with resistant rejection episodes (8). Along with this observation, treatment success in patients with corticosteroid-resistant AHR implies that B cells might have a role in acute rejection episodes.

Our case was a typical high-risk patient presenting with acute humoral rejection after the second transplantation. We did not know her PRA levels since our patient was not followed up on a regular basis prior to current transplantation after the first transplantation rejection. However, we assume that she might have been sensitized due to prior transplantation and multiple blood transfusions during that time and had high PRA levels. Interestingly, our case was highly resistant to all of the conventional treatment modalities known to date but transplanted kidney started to function normally after a single dose of rituximab. The patient still has normal kidney function approximately 10 months after the rejection treatment. Rituximab should be considered in acute humoral rejection resistant to conventional treatment. We did not experience any serious life-threatening infections in our patient except a mild urinary tract infection before the institution of rituximab.

## REFERENCES

1. Bock HA: Steroid-resistant kidney transplant rejection: Diagnosis and treatment. *J Am Soc Nephrol* 2001; 12 Suppl 17:48-52
2. Rai KR: Future strategies toward the cure of indolent B-cell malignancies. *New biologic therapies. Semin Hematol.* 1999; 36:12-17 Review. Erratum in: *Semin Hematol* 2000; 37(2):217
3. Becker Y, Becker B, Knechtle S: Transplantation of steroid resistant rejection with a novel anti B-cell preparation Rituximab. *Transplantation* 2000; 69:362
4. Faguer S, Kamar N, Guilbeaud-Frugier C, Fort M, Modesto A, Mari A, Ribes D, Cointault O, Lavayssière L, Guitard J, Durand D, Rostaing L: Rituximab therapy for acute humoral rejection after kidney transplantation. *Transplantation* 2007; 83(9):1277-1280
5. Montgomery RA, Zachary AA, Racusen LC, Leffell MS, King KE, Burdick J, Maley WR, Ratner LE: Plasmapheresis and intravenous immune globulin provides effective rescue therapy for refractory humoral rejection and allows kidneys to be successfully transplanted into cross-match-positive recipients. *Transplantation* 2000; 70(6):887-895
6. Becker YT, Becker BN, Pirsch JD, Sollinger HW: Rituximab as treatment for refractory kidney transplant rejection. *Am J Transplant* 2004; 4(6):996-1001
7. Grillo-Lopez AJ: Rituximab: An insider's historical perspective. *Semin Oncol* 2000; 27:9-16
8. Sarwal M, Chua MS, Kambham N, Hsieh SC, Satterwhite T, Masek M, Salvatierra O Jr: Molecular heterogeneity in acute renal allograft rejection identified by DNA microarray profiling. *N Engl J Med* 2003; 349(2):125-138