

Vaka Takdimi

A COCKER SPANIEL BITCH WITH UTERUS UNICORNIS (UNILATERAL CORNUAL AGENESIS)

Kazım GÜVENÇ* F. Seval TOYDEMİR* Hasan B. SONTAŞ*
Adem ŞENÜNVER*

Geliş Tarihi : 30.05.2006
Kabul Tarihi : 15.08.2006

Spaniel Kocker Irkı Dişi Bir Köpekte Uterus Unicornis (Unilateral kornual agenesi)

Özet: Bu olguda beş haftadır devam etmekte olan kanama şikayeti ile Fakülte'miz Kliniği'ne getirilen 12 yaşlı sağlıklı Spaniel Kocker ırkı dişi bir köpekte operasyondan sonra farkedilen unilateral kornual agenesi olgusu sunulmaktadır. Alınan anemnez ve yapılan klinik muayenede köpeğe uzayan proöstrus teşhisi konuldu. Rutin olarak yapılan yöntemle göre köpeğe ovariohisterektomi operasyonu yapıldı. Makroskobik bakıda sol tarafta; ovaryumun polikistik, ancak kornunun oluşmadığı; sağ tarafta ise kornunun kalınlaştığı ve ovaryumun da küçük olduğu belirlendi. Reprodüktif organların makroskobik incelemesinde unilateral kornual agenesi, ovarian ve paraovarian kistler, histopatolojik incelemesinde ise kistik endometrial hiperplazi tespit edildi. Sonuç olarak dişi köpeklerde düzenli östrus sikluslarına rağmen karşılaşılan bazı infertilite olgularında, unilateral kornual agenesi infertilitenin gizli nedeni olarak ihtimal dahilinde düşünülebilmektedir.

Anahtar Kelimeler: Dişi köpek, uzayan proöstrus, kongenital anomaliler, uterus.

Summary: In this case report, an uterus unicornis diagnosed following an operation in a 12 years old sexually intact Cocker Spaniel bitch presented to the clinic at the Faculty of Veterinary Medicine, University of Istanbul with a complaint of prolonged vulval bleeding going on more than 5 weeks has been presented. Extended proestrus was diagnosed based on anamnesis and the clinical findings. An ovariohysterectomy was performed from the mid-line ventral abdominal wall in a routine manner. Visual examination of the reproductive tract during the surgery revealed absence of the left uterine horn, thickness of the right uterine horn and a polycystic left ovary. Histopathological examination of reproductive organs revealed unilateral cornual agenesi and cystic endometrial hyperplasia with an ovarian and para ovarian cysts. In conclusion, despite of regular estrus cycles as in this case, unilateral cornual agenesi should be taken into consideration as a possible hidden reason of infertility in bitches.

Key Words: Bitch, prolonged proestrus, congenital anomalies, uterus

* Kazım GUVENC, DVM, PhD, Department of Obstetrics and Gynaecology, Faculty of Veterinary Medicine, Istanbul University, 34851, Avcilar, Istanbul, Turkey.

Introduction

Congenital structural anomalies of reproductive tracts in dogs are not encountered frequently. Estrous behaviors can be seen in dogs with one ovary and uterus unicornis (unilateral cornual agenesi). In female dogs with bilateral cornual agenesi, conception is not possible. However, in unilateral cornual agenesi pregnancy chances are slim; even if pregnancy occurs, the number of puppies are reduced (1, 2, 6).

Female hermaphrodites characterized with os penis, and congenital reproductive defects of vulva, vagina and vaginal areas can be diagnosed more easily compared to any other hidden congenital defects of reproductive organs. These hidden congenital defects in dogs that do not mate are not realized unless they cause a problem. In doubtful cases the diagnosis of this hidden congenital defect may be possible only after an experimental laparotomy or laparoscopic operation. Contrary to other animals radiologic diagnosis by injecting contrast material in oviduct is not quite helpful in dogs because of poor infiltration into oviduct (2, 3).

Karyotype analysis provides considerable information but the etiology in congenital defects is unknown. Intersexuality (hermaphroditism) in Cocker Spaniels is known to be inherited (3, 5).

The objective of this case study is to present a unilateral cornual agenesi determined in a Cocker Spaniel.

The Case description

A 12 years old sexually intact Cocker Spaniel bitch was presented to the Department of Obstetrics and Gynaecology, Faculty of Veterinary Medicine, with the complaint of vulval bleeding for more than 5 weeks. The owner indicated that, the bitch had regular estrus cycles with no mating or pregnancy history.

During the physical examination the dog was in a normal appearance and conformation. She was active and interested in her surroundings. The body temperature, heart, respiratory rates and auscultation sounds were all normal. Vulvar swelling and serosanguineous discharge was identified during the inspection of the vulva. Vaginoscopic examination revealed moist vaginal mucosa with bloody pink fluid. Ultrasonography with a high-definition ultrasound system, equipped with an 5-7.5 MHz broadband curved-array transducer was used and no clear image of uterus was obtained. The complete blood count and serum levels of urea and creatinine were within normal levels. Based on the history and clinical examination, prolonged proestrus was diagnosed and surgical removal of the reproductive tract was recommended since the bitch was not intended to be bred.

A combination of xylazine (0.6 mg/kg IM, Basilazin %2, Animedica GmbH, Germany) and ketamine (10 mg/kg IM, Ketasol %10, Richterpharma, Austria) was administered following the premedication with atropine (0.04 mg/kg SC, Atropin, Vetas, Turkey). After the maintenance of anesthesia, the ventral abdomen was clipped and routinely prepared for surgery. Warm Lactated Ringer solution was administered through an 22 GA cephalic catheter at the rate of 4 ml/kg of body weight. During the surgery, while extracting the uterus pulling from right horn, it is noted that the left horn is not present and appeared only as a serosa membrane (**Fig. 1**). On the same side, the ovary was polycystic. Prominent follicle on ovary and para-ovarian cyst were notable (**Fig. 2**). The right uterine horn appeared to be thick, had endometrial hyperplasia due to estrogenic effect. This thickness appeared to be more prominent around bifurcation than in the cranial part (**Fig-2**). On the side of the existing uterine horn, the ovary was very small and inactive. Abdominal cavity was closed as in normal ovariohysterectomy and a 0 number of Vicryl used as a suture material.

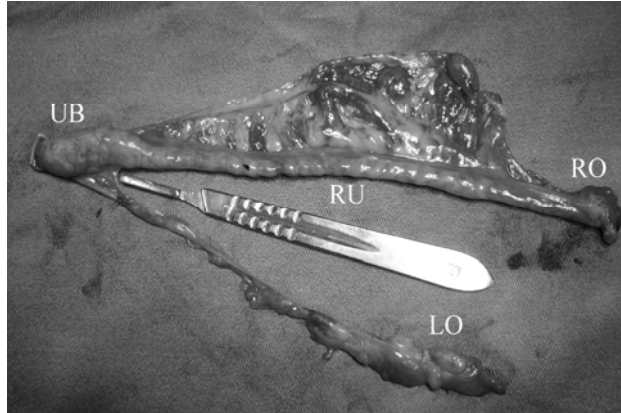


Fig. 1- An unilateral cornual agnesis and ovary cysts in a Cocker Spanel.

Şekil 1- Spaniel Cocker ırkı dişi bir köpekte unilateral kornual agnesisi ve ovariyel kistler

UB: Uterine body, **RU:** Right uterine horn, **RO:** Right ovary, **LO:** Left ovary

UB: Korpüs uteri, **RU:** Sağ kornu uteri, **RO:** Sağ ovariyum **LO:** Sol ovariyum

In uterine histopathology, corpus uteri and right uterine horn had cystic endometrial hyperplasia. The left horn was not present, and the ovary was polycystic and the para-ovarian cysts were prominent.

Following the surgery, enrofloxacin (%5, Batril®- K, Bayer Turkey) and a vitamin combination (Epargriseovit; DEVA Holding A.Ş., Turkey) were used for a week and the animal was closely monitored. About a week later, the animal was released without any complication following the removal of the sutures.

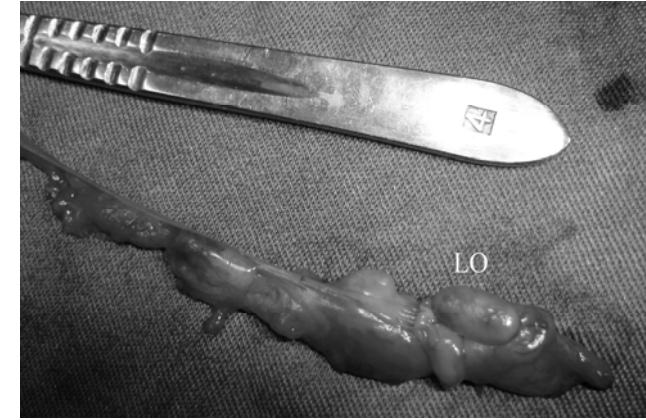


Fig. 2. Cystic structures on the ovary on the side of the non-formed uterine horn (uterus unicornis).

Şekil 2. Oluşmayan uterus kornusunun (unilateral kornual agnesisi) bulunduğu sol taraftaki ovariyumda kistik yapılar

LO: Left ovary, **LO:** Sol ovariyum

Discussion

Female dogs with uterus unicornis who have ovaries are known to show typical estrus behaviour (2). In this case, the Cocker Spaniel has shown typical estrus behavior in each cycle in all past seasons. During this last cycle, she was in extended proestrus because of the anovulatory follicular cysts on the ovary on the side of non-existing uterine horn (uterus unicornis).

Karyotyping genetic investigation shows hermaphroditism to be inherited in Cocker Spaniel (3, 7). There was not any phenotypical findings showing that this unilateral cornual agnesis might be related with hermaphroditism which is thought to be inherited in Cocker Spaniel. It has been reported that in this type of gonadal sex abnormalities, internal genitalies in all affected dogs includes a complete bicornuate uterus but oviduct may or may not be present. We could not investigate the association between unilateral cornual agnesis and hermaphroditism in order to comment specifically on the issue as we were not able to conduct a chromosomal analysis.

The diagnosis of congenital defects related to ovaries and uterus could be made directly by laparotomy or laparoscopy but mostly they are diagnosed incidentally while performing an ovariohysterectomy operation (4). In female dogs with bilateral cornual agnesis, the establishment of pregnancy is not possible; in case of unilateral agnesis pregnancy changes are slim even if conception occurs because abortion is likely due to insufficient endometrial surface (2). In this case, the Cocker Spaniel has had normal regular cycles, but it had never copulated so It is not known whether pregnancy or

abortion would have occurred or not. Moreover, in this cycle if the dog would have been copulated, and that ovulation have occurred she would not have become pregnant as the follicles were on the ovary on the side of non existing uterine horn. In a study related to women, it was indicated that cornual agenesis is widely encountered as a congenital uterine defect and pregnancy in those womens results in abortions in 35% of the cases (5). In conclusion, the congenital unilateral cornual agenesis can be the main hidden causes of infertility in female dogs despite of many regular normal estrous cycles.

References

- 1- **Alaçam, E.:** Karnivorlarda Üreme Süreci ve Sorunları. In: Kedi ve Köpek Hastalıkları. Ed. Yılmaz H., Ankara Medisan Yayınları 1998;437-512.
- 2- **England, G.C.W.:** Infertility in the bitch and queen in: Arthur's Veterinary Reproduction and Obstetrics. Ed. Noakes. D.E., Parkinson, T.J, England, Eighth Edition. Toronto. 2001, 639-670.
- 3- **Harvey, M.:** Condations of the non-pregnant Female. In: Manual of Small Animal Reproduction and Neonatology. Ed. Simpson, G.M, England,G., Harvey, M. 1998, 35-52.
- 4- **Lagerstedt, A.-S.:** Veterinarmedicinska faculteten, Thesis Uppsala, Sweden. 1993.
- 5- **Pentti, K. and Heinonen M.D. :** Unicornuate uterus and rudimentary horn. Fertility and sterility. 1997; 68, 2, 224-230.
- 6- **Seyrek-İntaş, K., Wehrend A., Nak Y., Tek H.B., Yılmazbaş G., Gökhan T., Bostedt H.:** Unilateral hysterectomy (cornuectomy) in the bitch and its effect on subsequent fertility. Theriogenology. 2004; 61:1713-1717.
- 7- **Siegel, E.T.:** Endocrine disease of the dog. Lea Febiger. Philadelphia. 1977, 180-211.