

A Case of *Pentastomum denticulatum* Infection in Goats

Andrey IVANOV¹, Zvezdelina KIRKOVA¹, Petar ILIEV¹, Krassimira UZUNOVA^{1*}

¹Trakia University, Faculty of Veterinary Medicine, Student's Campus 6000, Stara Zagora, Bulgaria

*Corresponding Author: Krassimira UZUNOVA Trakia University, Faculty of Veterinary Medicine,
Department of Animal Husbandry, Student's Campus 6000, Stara Zagora, Bulgaria
e-mail: mira60bg@yahoo.com

Geliş Tarihi / Received: 09.05.2011

ABSTRACT

A case of *Pentastomum denticulatum* infection in goats was described. In August 2007, in a herd of 30 goats, in the region of Rousse (North Bulgaria), there were observed non-specific clinical signs: reduced appetite, depression, emaciation, lying down, and decreased milk secretion. Despite antibiotic therapy 3 of the goats died. A necropsy was performed and small, yellow-white oval cysts with a white parasite inside were established in liver, lungs and mesenteric lymph nodes. The parasites (total number - 30) were examined microscopically and determined as *Pentastomum denticulatum* – larval stage of *Linguatula serrata*.

Key Words: *Pentastomum denticulatum*, *Linguatula serrata*, pentastomiasis

ÖZET

KEÇİLERDE *PENTASTOMUM DENTICULATUM* İNFEKSİYONU OLGUSU

Bu makalede, keçilerde *Pentastomum denticulatum* infeksiyonu olgusu tanımlanmıştır. 2007 yılının Ağustos ayında, Rusçuk bölgesinde (Kuzey Bulgaristan), 30 keçiden oluşan sürü içinde, iştah azalması, depresyon, aşırı zayıflama, yatma ve süt veriminin azalmasını içeren non-spesifik klinik belirtiler gözlemlendi. Antibiyotik tedavisi yapılmasına rağmen keçilerden üç tanesi öldü. Nekropsilerinde, karaciğer, akciğer ve mezenterik lenf düğümlerinin içinde beyaz parazitleri içeren küçük sarı-beyaz oval kistler görüldü. Parazitler (toplam sayı - 30) mikroskopik olarak incelenerek *Linguatula serrata* 'nın larva evresindeki *Pentastomum denticulatum* olarak saptandı.

Anahtar Kelimeler: *Pentastomum denticulatum*, *Linguatula serrata*, pentastomiaz

Introduction

Pentastomiasis is an entomosis in ruminants, rodents and men, caused by *Pentastomum denticulatum* – the larva of *Linguatula serrata*.

Linguatula serrata [Fröhlich, 1789] is an arthropod of class Maxillopoda, family Linguatulidae, that parasitize in the nasal cavity and adjacent sinuses, the larynx and pharynx of domestic and wild canids, felids and humans, that are the final hosts (Lazo et

al., 1999; Meshgi and Asgarian, 2003; Pandey et al., 1987). Due to its tongue-like shape, *Linguatula serrata* is also known as “tongue worm”. Female *Linguatula* are of a size of 80-100/8-10 mm, whereas males – 18-20/3-4 mm (Bussieras and Chermette, 1991). Ova are yellow-brownish, oval, slightly asymmetric and contain an acariform embryo with four hooks. They are shed in the environment with nasal discharge or faeces of final hosts.

Intermediate hosts are ruminants, rodents and rarely men. They become infected orally by ingesting food or water, contaminated with eggs. Acariform larvae hatch in animal intestines, pass in intestinal wall where either encyst, or migrate by a lymphohaematogenous route to mesenteric lymph nodes, liver, lungs, spleen or kidneys. There, they turn into nymphs (*Pentastomum denticulatum*), which are morphologically similar to adult forms. Pentastomes are white and 4-5/2-3 mm in size (Lazo et al., 1999). Their body is segmented by 72-92 grooves, each possessing a single set of spines. *Pentastomum denticulatum* is embedded in an oval pale cyst with diameter of 2 to 8 mm. Approximately 7 months after the infection, some nymphs leave the cysts and enter the abdominal or thoracic cavity of the host (Bussieras and Chermette, 1991). Illnesses could be caused by the adult forms in final hosts, as well as by the larval forms in intermediate hosts.

Linguatula serrata has been detected in dogs, cats, foxes, dingoes and humans (Hendrix and Robinson, 2006; Maleky, 2001; Meshgi and Asgarian, 2003; Morsy et al., 1999), whereas *Pentastomum denticulatum* has been found in domestic and wild ruminants, cats, rats, guinea pigs, rabbits, pigs, and humans (Gardiner et al., 1984; Hendrix and Robinson, 2006; Lazo et al., 1999; Nourollahi Fard et al., 2010; Tavassoli et al., 2007).

Pentastomiasis in herbivores is usually asymptomatic (Ravindran et al., 2008; Saiyari et al., 1996). Mir et al. (2009) have observed clinical signs – diarrhoea, gradual emaciation, anorexia and reluctance to stand in 4 wild goats (*Capra hircus*), caused by a co-infection of *Pentastomum denticulatum* and *Mycobac-*

terium avium subsp. paratuberculosis. In this case, the pentastomes were localized primarily in mesenteric lymph nodes.

Case

In August 2007, in a herd of 30 goats in the region of Rousse (North Bulgaria), the local veterinarian observed non-specific clinical signs: reduced appetite, depression, emaciation, lying down, and decreased milk secretion. The animals were kept on pasture, with the road to their feeding area passing through the village garbage dump. Fever was observed in some of the affected animals – up to 39°C. The veterinarian prescribed a treatment with antimicrobial preparations, yet they did not yield a positive result and 3 of the goats died.

A necropsy of the three dead animals was performed. The bodies were emaciated to cachectic, without discharge from any of the natural openings. The conjunctivas were anaemic and slightly icteric. On carcass dissection, a bloody fluid was discovered in the abdominal cavity, containing single white parasites with prolonged, oval, dorsoventrally flattened bodies, 5-6 mm long, and 1 mm wide. The liver had a pulp-like consistency, with small, yellow-white oval cysts with a diameter of about 5 mm on its surface and within the parenchyma. Some of the cysts were opened and bleeding. The mesenteric lymph nodes were juicy, hyperaemic, with cysts, some of which perforated and bleeding. Inspection of the chest cavity revealed a fluid mixed with blood, containing single parasites similar to the ones described above. On the surface and deep in lungs, there were numerous scattered oval pale cysts – also with a diameter of about 5 mm. Some of the cysts were opened and bleeding (Figure 1). When whole cysts were removed out of the liver, mesenteric lymph nodes, the lungs and were opened, an elongated oval whitish parasite, with a length of about 5 mm and width of 1 mm was found within. No changes in the other organs could be found. The observed lesions were identical in all three examined animals.



Figure 1. Viscera from a goat - haemorrhages.

Şekil 1. Bir keçiye ait iç organlar - hemorajiler.

From each animal, 10 parasites were isolated, stored in 70° ethanol and examined in the laboratories of the Parasitology and Invasive Diseases Unit at the Faculty of Veterinary Medicine, Trakia University, Stara Zagora. Examination of the specimens was performed natively using a stereoscope Stemi 2000-C (Zeiss, Jena), and after clearing with lactic acid, on an Axioscop microscope (Zeiss, Jena). The isolated parasites were white in colour with elongated oval dorsoventrally flattened bodies, with convex dorsal surface while the ventral one was slightly bent inward. They were wider in their anterior end, becoming gradually narrower towards the back end. Their dimensions were: length of 5-6 mm and width of 1-1.6 mm (Figure 2). The parasite's entire body was divided into 80-90



Figure 2. Isolated *Pentastomum denticulatum* parasites.

Şekil 2. İzole edilen *Pentastomum denticulatum* parazitleri

segments by transverse grooves. At the level of the first segment, apically, in the ventromedial area a rectangular structure with rounded corners and harder chitinous edges was outlined. At the dorsal rim of each segment aligned small conical backwards-pointing spikes were located (Figures 3 and 4). A ventrally-positioned mouth orifice along the median, and a pair of hooks laterally were observed on the front, wider body end. The hooks are retractile into their own sheaths and were bent backwards like the talons of a bird of prey. The sheath orifices were oval in shape, with smaller hooks in the apical end. In front of the mouth orifice, close to the front edge of the body, two additional pairs of small spikes could be seen (Figure 3).

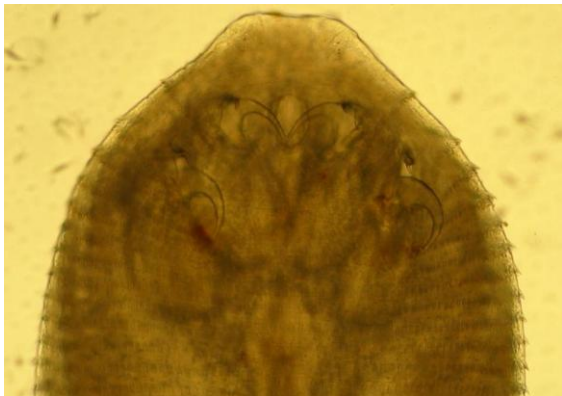


Figure 3. *Pentastomum denticulatum* – anterior end.

Şekil 3. *Pentastomum denticulatum* – anterior ucu.




Figure 4. *Pentastomum denticulatum* – posterior end.

Şekil 4. *Pentastomum denticulatum* – posterior ucu.

Discussion

The described morphology is a summary of all discovered and examined specimens. It corresponds to the morphological and metric descriptions of Baird et al. (1988), Banaja, (1983), Lazo et al. (1999), Soulsby (1982). These results were sufficient to identify the examined parasites as *Pentastomum denticulatum* – the nymph stage of *Linguatula serrata* [Fröhlich, 1789].

Having established the species of the parasites discovered in the goats, it was recommended that the owners perform a single subcutaneous treatment of the animals with Ivermectin at dosages of 0.2 mg/kg. Following the treatment, the herd's condition improved, and there were no further deaths.

The *Linguatula serrata* and *Pentastomum denticulatum* invasion in ruminants and carnivores has a great economical and health significance due to the possibility of wider spread among the animals and the risk of infection in humans. This necessitates the application of suitable and reliable diagnostic methods of establishing the infection at slaughtering, and in case infected animals are discovered – development of programmes for limiting the spread of infection.

Considering that the latest data on the spread of linguatulosis and pentastomiasis among animals in Bulgaria date back to 1956, it is necessary to conduct more detailed studies on the current state of this entomosis in domestic animals.

REFERENCES

- Baird, J. K., Kassebaum, L.J., Ludwig, G.K., 1988.** Hepatic granuloma in a man from North America caused by a nymph of *Linguatula serrata*. *Pathology* 20, 198-199.
- Banaja, A.A., 1983.** Scanning electron microscopy examination of larval *Linguatula serrata* Fröhlich (Linguatulidae: Pentastomida). *Zeitschrift für Parasitenkunde* 69, 271-277.
- Bussieras, J., Chermette, R., 1991.** Parasitologie Vétérinaire Maisons Alfort. Paris, France, pp. 105-106.
- Gardiner, C.H., Dyke, J.W., Shirley, S.F., 1984.** Hepatic granuloma due to a nymph of *Linguatula serrata* in a woman from Michigan: a case report and review of the literature. *American Journal of Tropical Medicine and Hygiene* 33, 187-189.
- Hendrix, C.M., Robinson, E., 2006.** Diagnostic Parasitology for Veterinary Technicians. Third edition, Mosby Elsevier, Philadelphia, PA, USA.
- Lazo, F.R., Hidalgo, E., Lazo, J.E., Bermeo, A., Llaguno, M., Murillo, J., Teixeira, V.P.A., 1999.** Ocular linguatuliasis in Ecuador: Case report and morphometric study of the larva of *Linguatula serrata*. *American Journal of Tropical Medicine and Hygiene* 60, 405-409.
- Maleky, F., 2001.** A case report of *Linguatula serrata* in human throat from Tehran, central Iran. *Indian Journal of Medical Sciences* 55, 439-441.
- Meshgi, A., Asgarian, O., 2003.** Prevalence of *Linguatula serrata* infection in stray dogs of Shahrekord, Iran. *Journal of Veterinary Medicine, Serie B* 50, 466-467.
- Mir, M.S., Darzi, M.M., Hussain, I., Wani, S.A., 2009.** Concurrent occurrence of visceral linguatulosis and paratuberculosis in alpine cross goats (*Capra hircus*). *Veterinarski Arhiv* 79, 301-314.
- Morsy, T.A., El-Sharkawy, I.M., Lashin, A.H., 1999.** Human nasopharyngeal linguatuliasis (Pentastomida) caused by *Linguatula serrata*. *Journal of the Egyptian Society of Parasitology* 29, 787-790.
- Nourollahi Fard, S.R., Kheirandish, R., Asl, E.N., Fathi, S., 2010.** The prevalence of *Linguatula serrata* nymphs in goats slaughtered in Kerman slaughterhouse, Kerman, Iran. *Veterinary Parasitology* 171, 176-178.
- Pandey, V.S., Dakkat, A., Elmamoune, M., 1987.** Parasites of stray dogs in Rabat Region, Marocco. *Annals of Tropical Medicine and Parasitology* 81, 53-55.
- Ravindran, B., Lakshmanan, B., Ravishankar, C., Subramanian, H., 2008.** Prevalence of

Linguatula serrata in domestic ruminants in India. Southeast Asian Journal of Tropical Medicine and Public Health 39, 808-812.

Saiyari, M., Mohammadian, B., Sharma, R.N., 1996.

Linguatula serrata (Frolich, 1789) nymphs in lungs of goats in Iran. Tropical Animal Health and Production 28, 312-314.

Soulsby, E.J.L., 1982. Helminths, Arthropods and Protozoa of Domesticated Animals. 7th Ed., London: The English Language Book Society and Bailliere Tindall.

Tavassoli, M., Tajic, H., Dalir-Naghadeh, B., Hariri, F., 2007. Prevalence of *Linguatula serrata* nymphs and gross changes of infected mesenteric lymph nodes in sheep in Urmia, Iran. Small Ruminant Research 72, 73-76.