



Isolated True Contractile Left Ventricular Diverticulum in an Adult Patient; A Case Report and Review of the Literature

İrfan Barutçu*, Hakan Güllü*, Ertan Yetkin*, Feridun Koşar*, Sengül Çehreli*

* Inonu University, School of Medicine, Department of Cardiology, Malatya

Isolated left ventricular diverticulum, which is characterized by local embryologic development failure of ventricular muscle, is a rare cardiac abnormality and it may be found in isolated form or with other cardiac abnormalities.

Clinically, it has been reported that it might cause heart failure, arrhythmia or chest pain despite the fact that it may often follow an asymptomatic course. We present a case of is left ventricular diverticulum, detected in a patient who referred to our clinic complaining of chest pain.

Key Words: Isolated Ventricular Diverticulum, Chest Pain, Congenital Cardiac Malformation.

Yetişkin Bir Hastada İzole, Gerçek Kontraktıl Sol Ventriküler ; Olgu Sunumu ve Literatürün Gözden Geçirilmesi

İzole sol ventriküler divertikül, ventrikül kasının lokal embriyolojik gelişim kusuruyla karakterize nadir bir anomali olup tek başına veya diğer kardiyak anomalilerle birlikte bulunabilir. Klinik olarak sıklıkla asemptomatik seyirli olsa da kalp yetersizliği, aritmi ve göğüs ağrısına yol açabileceği rapor edilmiştir. Bu nedenle, kliniğimize göğüs ağrısı ile başvuran ve izole sol ventriküler divertikül saptanan olgumuzu sunmayı uygun bulduk.

Anahtar Kelimeler: İzole Ventriküler Divertikül, Göğüs Ağrısı, Konjenital Kardiyak Malformasyon.

Congenital ventricular diverticulum, initially described in 1938 is a rare and usually asymptomatic cardiac malformation.¹ It frequently accompanies other cardiac abnormalities, and it is most commonly diagnosed during early childhood. About 30% of all cases are not associated with any congenital malformation and they are defined as isolated left ventricular diverticulum.²

Due to its asymptomatic course, isolated left ventricular diverticulum is diagnosed with difficulty. Therefore, usually, it is detected during routine echocardiographic evaluation or cardiac catheterization. This is a report of a true left ventricular diverticulum discovered during the diagnostic workup of a woman with chest pain.

CASE

A 53 year-old female patient was admitted to our hospital with the complaint of chest pain increasing by exercise, relieving at rest since last year. There was no remarkable symptoms other than dyspnea and she had a history of hypertension for the last three years. There was no family history of heart disease. The blood pressure was 160/90mmHg, and heart rate was 70 bpm. The physical examination was normal and also the routine blood and biochemical tests were within the normal range. The 12-lead electrocardiogram showed sinus rhythm of 70 beats per minute and 1 mm horizontal ST-segment depression in leads DII, DIII, aVF, V1-V3.

By using standard Judkins method, coronary angiography was performed in order to exclude coronary artery disease, which revealed normal epicardial arteries. Left ventriculography revealed an isolated contractile diverticulum, 3 x 3 cm in size, originating from the apex (Figure I). On echocardiographic examination the left ventricular diverticulum was also demonstrated (Figure II). The myocardial perfusion imaging by Tc-99 sestamibi SPECT did not show any

sign of myocardial ischemia. Due to the lack of ischemic findings and the lack of concomitant cardiac malformation, it was further decided to treat the patient medically.

Figure I. The angiographic appearance of left ventricular diverticulum from right anterior oblique projection.

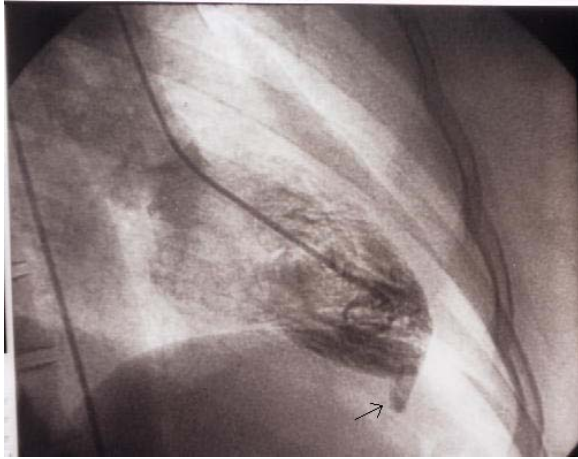
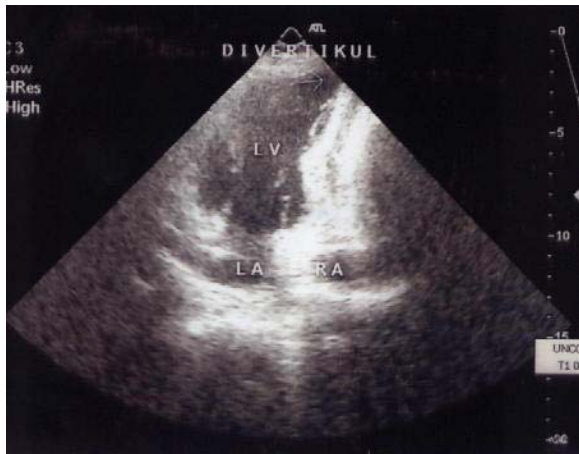

Figure II. The echocardiogram.



DISCUSSION

Cardiac diverticula usually arise as contractile muscular outpouchings from the left ventricular wall. The incidence was reported as 0.4% in autopsies of subjects with congenital cardiac defects.³ As it was in our case, it arises most commonly from left ventricle, but right atrial, right ventricular, and dual ventricular origins have been reported.⁴⁻⁶ They are most frequently classified as muscular and fibrous.⁶ Although its etiology is not clear an embryologic developmental defect has been proposed. Failure of normal midline fusion of the paired primitive

mesoderm in combination with abnormal fusion of the cardiac loop to the yolk sac before its descent is believed to result in the development of muscular apical ventricular diverticula.⁷

The cases with all three cardiac layers present along their walls are named as true diverticula. They usually arise from the left ventricular apex by a narrow neck. The fibrous diverticula arise from the apex or base of the ventricle near the atrioventricular valvular ring. They are not associated with thoraco-abdominal or other cardiac defects. Their histological examination reveals predominantly fibrous tissue.

Cardiac diverticulum may be seen as part of a pentalogy in Centrall's syndrome, which was described by Centrall et al. in 1958.¹ The classic clinical picture is characterized by congenital defects involving the abdominal wall, sternum, diaphragm, pericardium and heart. Most common cardiac defects accompanying this syndrome are principally, ventricular septal defect, atrial septal defect, left ventricular diverticulum, pulmonary stenosis and atresia.⁸ The long-term prognosis of Centrall's syndrome depends on the severity of the cardiac defects and associated malformations. In patients who undergo surgery during the first days of life, mortality can be as high as 50%.⁹ Cardiac rupture, tamponade, sudden death, endocarditis, peripheral embolism, heart failure, and arrhythmia have all been described as complications of Centrall's syndrome and as causes of death.⁹⁻¹⁰ Since our case has no other cardiac malformations, we described it as an isolated ventricular diverticulum.

The patients with diverticula, even though they are asymptomatic, may present with an abnormal electrocardiogram or chest x-ray. On the other hand, the diverticulum may cause chest pain, heart failure, ventricular arrhythmias, or cardiac rupture.¹¹⁻¹² Rupture and cardiac tamponade are unusual findings.¹³ However, in our case, except the abnormal electrocardiogram characterized with ST segment depression and chest pain, the above-mentioned findings were not present.

There are only a few reports presenting contractile muscular diverticula in the absence of congenital heart disease. Therefore, the natural history and management of such cases is not clearly defined. There is no agreement among the authors with respect to the therapeutic approaches. Some advocate resection in all cases even if asymptomatic to prevent rupture and thrombosis formation, whereas others

Isolated True Contractile Left Ventricular Diverticulum in an Adult Patient; A Case Report and Review of the Literature

recommend a conservative approach, especially in case of muscular diverticula, which may be less inclined to rupture than fibrous diverticula.¹ Surgery is often indicated for congenital heart disease, and concomitant diverticular resection is usually performed.¹² In the light of these data, considering the lack of ischemic findings in our patient, we preferred the conservative approach.

In patients with midline defect or congenital heart disease, the prognosis depends on the severity and the degree of concomitant malformations. Isolated and asymptomatic cases usually have a benign course. Although isolated ventricular diverticulum is a rare cardiac malformation and often has an asymptomatic course, as seen in our case, in patients presenting with chest pain and dyspnea, isolated ventricular diverticulum should be kept in mind in the differential diagnosis of chest pain.

REFERENCES

1. Okereke OJ, Cooley DA, Frazier OH. Congenital diverticulum of the ventricle. *J Thorac Cardiovasc. Surg* 1986;91:208-14.

2. Gruberg I, Goldstein SA, Pfister AJ, Monstein LH, Evans DM, Leon MB. *Circulation* 2000;101:109-10.
3. Pressior R, Downing JW. Congenital diverticula of the right ventricle of the heart: case report. *J Natl Med Assoc* 1980;72:262-4.
4. Bandow GT, Rowe GC, Crummy AB. Congenital diverticulum of the right and left ventricles. *Radiology* 1975;117:19-20.
5. Vilacosta I, San Roman JA, Camino A, et al. Right atrial diverticulum and hypertrophic cardiomyopathy. *Eur Heart J* 1993;14:721-22.
6. Shen EN, Fukuyama O, Herre JM, Yee E, Scheinman MM. Ventricular tachycardia with congenital ventricular diverticulum. *Chest* 1991;100:283-85.
7. Hudson REB. Congenital abnormalities of the heart as a whole. In: Hudson REB, ed. *Cardiovascular Pathology*, Vol.2 London: Edward Arnold Publishers Ltd. 1965:174-46.
8. Centrall JR, Haller JA, Ravitch MM. A syndrome of congenital defects involving the abdominal wall, sternum, diaphragm, pericardium and heart. *Surg Gynecol Obstet.* 1958;107:602-14.
9. Vazquez-Jimenez JF, Muehler EG, Daebritz S, Kuetel J, Nishigaki K, Huegel W, Messmer BJ. Centrall's syndrome: a challenge to the surgeon. *Ann Thorac. Surg.* 1998;65:1178-85.
10. Walton-Shirley M, Smith SM, Talley D. Left ventricular diverticulum: case report and review of the literature. *Cathet Cardiovasc diagn.* 1992;26:31-33.
11. Ho KT, Sim EKW, Lee CN, Chia BL. Isolated right ventricular diverticulum with chest pain. *Int J Cardiol* 1997;59:89-91.
12. Handler CE, Walker JM. Congenital diverticulum of the left ventricle presenting as heart failure and diagnosed by magnetic resonance imaging. *Int J Cardiol* 1989;22:115-19.
13. Westaby S, Katsumata T, Runciman M, Burch M. *Ann Thorac Surg* 1997;64:1181-2.

Corresponding Address:

Dr. Hakan Güllü
İnönü Üniversitesi Tıp Fakültesi
Kardiyoloji AD, 44069 Malatya
Tel : 422 341 0660-4509
Fax : 422 341 0610
E-mail : gulluhakan@hotmail.com