



Lower Gastrointestinal Tract Bleeding Caused by Inflammatory Pseudotumour in Meckel's Diverticulum: Report of A Case

Gökhan Sögütlü*, Mehmet Yılmaz*, Neşe Karadağ **, Burak Işık*, Aydemir Ölmez*,
Özgür Cinpolat*

* İnönü University Medical School, Department of General Surgery, Malatya, Turkey

** İnönü University Medical School, Department of Pathology, Malatya, Turkey

Inflammatory pseudotumour of the gastrointestinal tract is rare causes gastrointestinal bleeding rarely. We report in a case of a bleeding inflammatory pseudotumour in Meckel's diverticulum in an adult.

Key Words: Inflammatory pseudotumour, Meckel's diverticulum, Bleeding

Meckel Divertikül Yerleşimli İnflamatuvar Psödötümörün Neden Olduğu Alt Gastrointestinal Kanama

Gastrointestinal sistem inflamatuvar psödötümörü nadir görülür. Nadir olarak gastrointestinal kanamaya yol açarlar. Biz burada, yetişkin bir kadında meckel divertikül yerleşimli kanayan infalamatuvar psödötümör vakasını sunduk.

Anahtar Kelimeler: İnflamatuvar psödötümör, Meckel divertikülü, Kanama

Inflammatory pseudotumours are polypoid lesions of the gastrointestinal tract, composed of fibrous tissue and blood vessels.¹ These may occur anywhere in the alimentary tract¹. Inflammatory pseudotumour in Meckel's diverticulum represents a rare entity.² These polyps may cause symptoms such as obstruction and intussusception.^{1,2} Gastrointestinal tract bleeding, as a manner of presentation of the inflammatory pseudotumour, is rare.

We report a case of an inflammatory pseudotumour in a Meckel's diverticulum presenting with lower gastrointestinal tract bleeding.

CASE

A 57 year-old woman was admitted to our hospital with complaints of severe hematochesia. There was no previous history of any bloody stool or digestive disease. On admission, her blood pressure was 103/77 mmHg and pulse was 104/min. An initial hemogram showed hemoglobin of 8.2 g/dl, hemotocrit of 22.6 %, WBC count of 1770/mm³ and platelet count 187000 / mm³.

Blood transfusion of 5 units was performed. Following the stabilizaion of the patient, colonoscopy was performed, but could not disclose any cause of bleeding because of the fresh and hematinised blood in the colon. An emergency angiography was also performed concurrently with the blood transfusion but revealed no abnormality. However, the patient continued to have massive gastrointestinal bleeding and there was deterioration of the hemodynamic parameters inspite of the repeated blood transfusions. We decided on an emergency operation and the patient was taken to the operating room for a celiotomy. During the operation, we irrigated the whole colon through the appendiceal stump with a large bore tube to accomplish intraoperative colonoscopy whereas colonoscopy did not reveal any source of bleeding. A Meckel's diverticulum was found about 50 cm proximal from the ileocecal valve on the antemesenteric side.

Bleeding from the Meckel's diverticulum was thought to be the most probable site. The Meckel's diverticulum resection was performed with a limited small bowel resection with primary anastomosis. The postoperative course was uneventful. The patient is in good health and bleeding has not recurred 2 years after surgery.

The specimen consisted of a 2x2x1.8 cm polypoid that was covered with mucosa. Its cut surface was solid and tau colored (Fig.1).

Microscopically, the surface of the polyp lesion consisted of intact epithelium except a limited ulceration area. The tumour was in the submucosa, which was composed of uniform spindle-shaped cells with vesicular nuclei, lymphocytes, histiocytes and plasma cells (Fig. 2). Therefore, the diagnosis was made as inflammatory pseudotumour.

Figure 1. Resected small bowel showing Meckel's diverticulum and inflammatory pseudotumour.

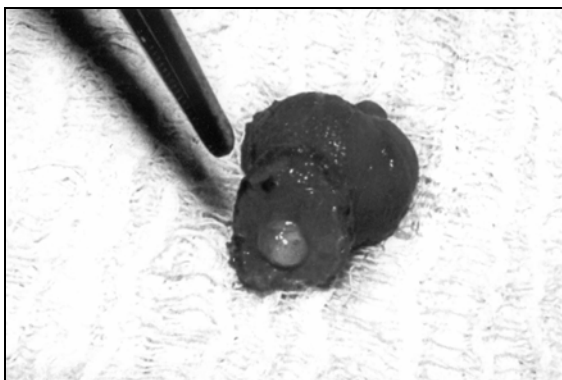
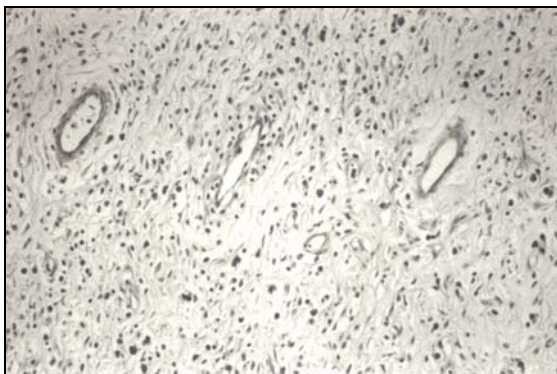


Figure 2. The characteristic picture of inflammatory fibroid polyp: Spindle-shaped cells, blood vessels and inflammatory infiltrate that composed of lymphocytes, plasma cells and histiocytes. (HE x200)



DISCUSSION

Meckel's diverticulum is usually asymptomatic, but approximately 4% induce some complications.³ Although bleeding from a Meckel's diverticulum in an adult is rare, it should be kept in mind since the bleeding tends to be acute and massive.⁴ Pathogenesis of the bleeding from Meckel's may be ectopic gastric mucosa, repeated intussusception, food remnants and circulatory disturbance.^{5,6} Inflammatory pseudotumour in Meckel's diverticulum as a source of bleeding has not been reported yet.

Inflammatory pseudotumours of the gastrointestinal tract are rare entities. These may occur anywhere in the alimentary tract nevertheless, symptomatic inflammatory pseudotumour in Meckel's diverticulum reported in only one case.² The symptoms of inflammatory pseudotumours are usually small bowel obstruction or intussusception^{1,2}. Gastrointestinal tract bleeding caused by inflammatory pseudotumours was reported rarely. Chronic bleeding of inflammatory pseudotumours in jejunum was reported by Samter et al.¹ Massive bleeding of inflammatory pseudotumours in cecum was reported by Mc Gee et al.⁷ Catala et al. reported a case of lower gastrointestinal tract bleeding from an inflammatory pseudotumour in a patient with ileal Crohn's disease⁸. Our case is the first report of a bleeding inflammatory pseudotumour in Meckel's diverticulum.

Inflammatory pseudotumours are inflammatory lesions rather than neoplasms and tend to have no malignant potential. Nevertheless, incomplete excision or biopsy alone may predispose to recurrent symptoms,² so complete surgical excision is the correct surgical treatment.

REFERENCES

1. Samter TG, Alstott DF, Kurlander GJ. Inflammatory fibroid polyps of the gastrointestinal tract. *Am J Clin Path* 1966; 45:420-36.
2. Wakefield SE, Baigrie RJ, Molyneux AJ, Dowling BL. Inflammatory pseudotumour in Meckel's diverticulum producing intussusception. *Br J Surg* 1995; 82:30-1.
3. Diamond T, Russel CFJ. Meckel's diverticulum in the adult. *Br J Surg* 1985; 72:480-2.
4. Satya R, O'Malley JP. Case 86: Meckel diverticulum with massive bleeding. *Radiology*. 2005; 236: 836-40.
5. Higaki S, Saito Y, Akazawa A, Okamoto T, Hirano A, Takeo Y, et al. Bleeding Meckel's diverticulum in adult. *Hepato-gastroenterology* 2001; 48:1628-30.
6. Heider R, Warshauer DM, Behms KE. Inverted Meckel's diverticulum as a source of chronic gastrointestinal blood loss. *Surgery* 2000; 128:107-8.
7. Mc Gee HJ. Inflammatory fibroid polyps of the ileum and cecum. *A M A Arch Path* 1960; 70:203-7.
8. Catala M, Sanchez A, Hinojosa J, Primo J, Floros J, Calvete J, Martinez B. An inflammatory fibroid polyp (eosinophilic granuloma) and Chron's disease located in the ileum. *Rev Esp Enferm Dig* 1992; 82:193-5.

Corresponding Author:

Yrd.Doç.Dr.Gökhan SÖĞÜTLÜ
İnönü University Medical School, Department of General Surgery,
44069 Malatya, TURKEY
E.mail : gsogutlu@inonu.edu.tr
Fax: : 422 341 02 29