



## A 31-Year-Old Man with Well-differentiated Fetal Adenocarcinoma

Sacit İcten<sup>1</sup>, Nejat Altıntaş<sup>2</sup>,  
Frank Scheineider<sup>3</sup>,  
Bulent Altinsoy<sup>4</sup>

<sup>1</sup> Health Ministry Pasabahce  
Government Hospital  
Department of Pulmonary  
Medicine, Istanbul

<sup>2</sup> UPMC Montefiore Hospital,  
Department of Pulmonary,  
Allergy and Critical Care,  
Pittsburgh, PA, USA

<sup>3</sup> UPMC Presbyterian Hospital,  
Department of Pathology, USA

<sup>4</sup> Health Ministry Afyon  
Government Hospital,  
Department of Pulmonary  
Medicine, Afyon

Well-differentiated fetal type adenocarcinomas used to be classified as subtype of pulmonary blastomas until recently. Today it is considered a rarely seen type of adenocarcinoma, characterized by low malignant potential and low mortality. In this article, we report a patient who was found to have a well-differentiated fetal type adenocarcinoma, following left lower lobectomy. We believe that the identification of this cancer subtype in patients with lung carcinoma will reduce unnecessary radical treatment methods beyond surgery.

**Key Words:** Well differentiated Fetal Adenocarcinoma; Lung Cancer, Pulmonary Blastomas.

### İyi Diferansiyeli Fötal Adenokarsinomlu 31 Yaşında Erkek Hasta

İyi-diferansiyeli fötal adenokarsinom son zamanlara kadar pulmoner blastomların alt grubu olarak sınıflandırıldı. Bugün ise düşük malignansi potansiyeli ve düşük mortalite özelliğine sahip, adenokarsinomların nadir görülen bir alt tipi olarak düşünülmektedir. Bu makalede, sol alt lobektomi sonrası iyi-diferansiyeli fötal adenokarsinom tanısı alan bir hastayı sunuyoruz. Akciğer karsinomlu hastalarda bu kanser alt tipinin tanımlanmasının cerrahi haricindeki, diğer gereksiz radikal tedavileri azaltacağını düşünüyoruz.

**Anahtar Kelimeler:** İyi- diferansiyeli Fötal Adenokarsinom; Akciğer Kanseri, Pulmoner Blastomalar.

Bavuru Tarihi: 16.01.2012

Kabul Tarihi: 06.03.2012



DOI: 10.7247/jiumf.19.2.7

### Introduction

The most current classification of rare variants of invasive adenocarcinoma of lung are invasive mucinous adenocarcinoma (formerly mucinous bronchioloalveolar carcinoma), colloid adenocarcinoma, fetal adenocarcinoma and enteric adenocarcinoma.<sup>1</sup> Fetal adenocarcinoma (FA) is divided into low-grade

(well-differentiated [WD]) and high-grade (HG) forms.<sup>1</sup>

Well-differentiated fetal adenocarcinoma (W DFA) is a rare type of lung tumor, first described by Koss and coworkers in 1991.<sup>2</sup> Morphologically, it resembles fetal lung between the 10th and 15th week of gestation. It differs from pulmonary blastoma in that the mesenchymal component of the tumor is histologically benign.<sup>3</sup>

We report a case of a 31-year-old male with W DFA and discuss the unusual features of this type of tumor.

**Correspondence** Nejat ALTINTAS, MD,  
UPMC Montefiore Hospital, Department of Pulmonary,  
Allergy and Critical Care, Pittsburgh, PA, USA  
Voice; +1412-2512864  
e-mail: altintasn@upmc.edu

**Case Report**

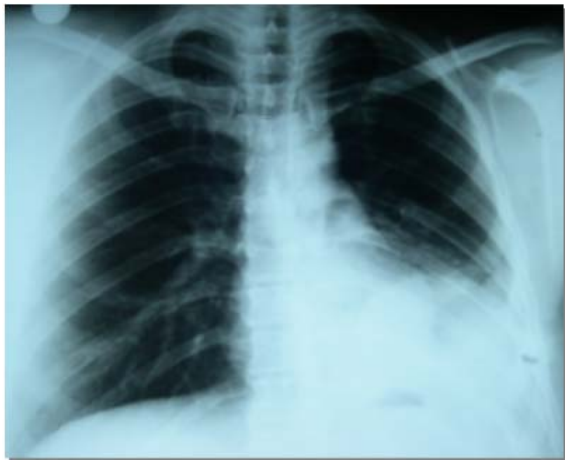A 31-year-old man presented with one month history of left sided chest pain, hemoptysis, cough, and dyspnea. He had no significant past medical history and no history of smoking. The physical examination was normal. The chest x-ray showed an opacity with well defined border in the left lower lung (Figure 1). Chest computed tomography scans revealed a left hilar opacity measuring 11x9.5 cm in diameter (Figure 2).

Subsequent fiberoptic bronchoscopy demonstrated a polypoid structure entirely obstructing the left main bronchus (Fig. 3).

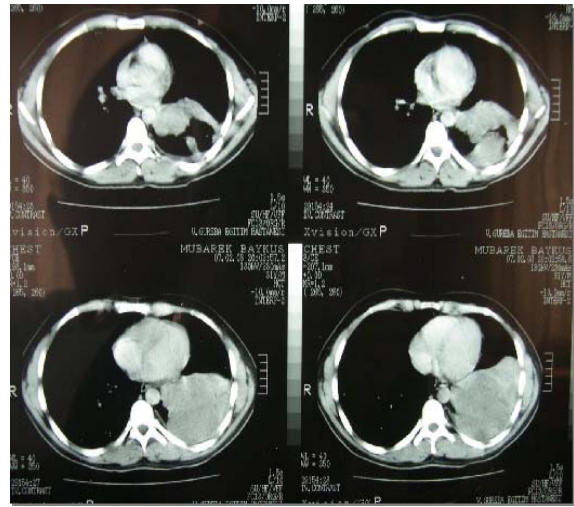
A diagnosis of malignancy was rendered on bronchoscopic biopsies. It was decided to proceed directly to surgical exploration and resection without performing additional pre-operative testing. A left lower lobectomy with mediastinal lymph nodal sampling was performed.

A gross examination revealed single, white, necrotic measuring 18x14x7.5 cm well defined mass. By light microscopy, the tumor revealed sharp borders fully surrounded by normal lung tissue. The tumor was composed of well differentiated glands lined by a single layer of columnar cells with occasional subnuclear vacuolization, resembling endometrial glands (Fig. 4).

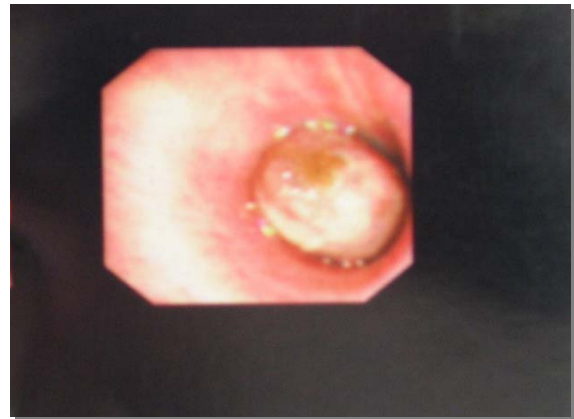Focal squamous metaplasia and a desmoplastic stroma with no immature cells were observed. Centrally, a squamous morule was present, composed of large squamoid cells with dense, eosinophilic cytoplasm and large round nuclei with pale chromatin and small but distinct nucleoli. The scant stroma was composed of bland spindle shaped fibroblasts. The definitive diagnosis of well-differentiated fetal adenocarcinoma of



**Figure 1.** In chest x-ray; an opacity with well-defined border in the left lower lung.



**Figure 2.** Chest Computed Tomography revealed a left hilar opacity measuring 11x9.5 cm in diameter.



**Figure 3.** Fiberoptic bronchoscopy demonstrated a polypoid structure entirely obstructing the left main bronchus.

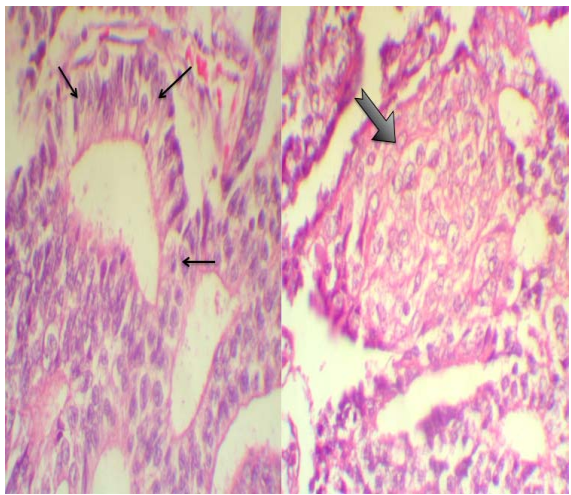
the lung was made. Immunohistochemistry showed strong positivity for cytokeratin 8/18 and beta-catenin. There was no reactivity for estrogen and progesterone receptors, CEA, alpha-feto protein, chromogranin A, NSE, p-53, and S100.

**Discussion**

Fetal adenocarcinoma of the lung is used to be classified as variant of pulmonary blastoma.<sup>4</sup> Today, we recognize it as a very uncommon form of lung adenocarcinoma with pathogenesis, clinical manifestations, course, and morphologic features quite distinct from pulmonary blastoma.<sup>1</sup> The term “pulmonary blastoma” is reserved for tumors having both a malignant stromal and epithelial components, with the epithelial component showing some similarity

## A 31-Year-Old Man with Well-differentiated Fetal Adenocarcinoma

to the glands of FA.<sup>5,6</sup> It is important to distinguish FA and true pulmonary blastoma as the prognosis of the former lesion is considerably better.<sup>3,4</sup>



**Figure 4.** Histological findings. The malignant cells form lumen-containing glands; have uniform, small, basally oriented hyperchromatic nuclei; and optically clear to faintly eosinophilic cytoplasm (small arrows). Subnuclear vacuoles are well developed in a minority of the neoplastic cells. Centrally, a morule is composed of large squamoid cells with distinctly denser eosinophilic cytoplasm and larger, round nuclei with pale chromatin and small but distinct nucleoli. The scant stroma is composed of bland, spindle shaped fibrosis.

FA occurs in low-grade (well-differentiated [WD]) and high-grade (HG) forms.<sup>3</sup> FA typically occurs in young patients,<sup>7</sup> many of whom are asymptomatic and have the pulmonary mass found during routine radiologic examinations. The peak incidence of pulmonary blastoma, on the other hand, is 35-40 years of age,<sup>8</sup> with slight female predilection for the development of this tumor. 80% of pulmonary blastoma patients are smokers, while up to 24% of patients are nonsmokers.<sup>5,8</sup>

The HG variant of FA typically occurs several decades later in life. Although it resembles the well-differentiated variant histologically, it shows more complex and disorganized glands, necrosis, and larger nuclei with more prominent nucleoli. High-grade FA may also be combined with other, more common, forms of lung adenocarcinoma.<sup>9,10</sup>

Usually, patients are asymptomatic or complain of cough, fever, and chest pain. The prognosis is better

than those for other subtypes of adenocarcinomas. The 5-year survival rate is 80%.<sup>11</sup>

Usually, BPB is present as a large mass, the average size in reported cases. The mass ranges from 1 to 10 cm (mean, 4.5 cm), in reported cases, presenting as a solitary peripheral or midlung mass.<sup>11,12</sup> Multiple masses and endobronchial tumors are infrequent.<sup>12</sup> Adenopathy and pleural effusion are rare. The tumor has a homogeneous solid appearance, and necrosis and hemorrhage are rare. Usually, there is a well-defined lobulated margin due to expanding tumor growth.<sup>11,12</sup>

It is very rare to see intrabronchial polypoid obstruction by fiberoptic bronchoscopy as described in this case.<sup>13</sup>

Histologically, the W DFA element characteristically demonstrates glandular elements with tubules composed of glycogen-rich, non-ciliated cells that resemble fetal lung tubules and squamoid morules may be seen with clear nuclei within lumens. The immature mesenchyme and epithelium mimic the embryonic lung at 10-16 weeks gestation. The name W DFA is therefore derived from the histological appearances of the tumor.<sup>1</sup> Most are low grade with a favorable outcome. When mixtures occur with other histological subtypes, the tumor should be classified according to the predominant component.<sup>1</sup>

The standard treatment is surgical resection, if technically possible.<sup>1,12</sup>

### Conclusion

This report emphasizes a rare variant of adenocarcinoma with detailed discussion of its pathology. Well-differentiated fetal adenocarcinoma is a low grade malignancy it is associated with good prognosis, therefore it is very important for clinicians to consider and identify this type of tumor so as to unnecessary radical treatment methods beyond surgery.

### References

1. Travis WD, Brambilla E, Noguchi M, et al. International association for the study of lung cancer/American Thoracic Society/European Respiratory Society: international multidisciplinary classification of lung adenocarcinoma: executive summary. *Proc Am Thorac Soc* 2011; 8(5): 381-5. DOI: [1556-0864/11/0602-0244](https://doi.org/10.1002/1097-0142)
2. Koss MN, Hochholzer L, O'Leary T. Pulmonary blastomas. *Cancer* 1991; 67(9): 2368-81. DOI: [10.1002/1097-0142](https://doi.org/10.1002/1097-0142)
3. Nakatani Y, Kitamura H, Inayama Y, et al. Pulmonary adenocarcinomas of the fetal lung type: a clinicopathologic study indicating differences in histology, epidemiology, and natural history of low-grade and high-grade forms. *Am J Surg Pathol* 1998; 22(4): 399-411. DOI: [0147-5185](https://doi.org/10.1002/1097-0142)

4. Proctor L, Folpe AL, Esper A, Wolfenden LL, Force S, Logani S. Well-differentiated fetal adenocarcinoma of the lung: cytomorphologic features on fine-needle aspiration with emphasis on use of beta-catenin as a useful diagnostic marker. *Diagn Cytopathol* 2007; 35(1): 39-42. DOI: [10.1002/dc.20583](https://doi.org/10.1002/dc.20583)
5. Geisinger KR, Travis WD, Perkins LA, Zakowski MF. Aspiration cytomorphology of fetal adenocarcinoma of the lung. *Am J Clin Pathol* 2010; 134(6): 894-902. DOI: [10.1309/ajcp4t5swatqlktq](https://doi.org/10.1309/ajcp4t5swatqlktq)
6. Gamsızkan M, Kurt B, Deveci S, Gunhan D. Fetal akciğer tipi pulmoner adenokarsinom. *Gülhane Tıp Dergisi* 2005; 46(4): 347-50.
7. Longo M, Levra MG, Capelletto E, et al. Fetal adenocarcinoma of the lung in a 25-year-old woman. *J Thorac Oncol* 2008; 3(4): 441-3. DOI: [10.1097/JTO.0b013e318169cd9a](https://doi.org/10.1097/JTO.0b013e318169cd9a)
8. Paull DE, Moezzi J, Katz N, Little AG, Adebonojo SA. Positron emission tomography in well-differentiated fetal adenocarcinoma of the lung. *Clin Nucl Med* 2006; 31(4): 213-4. DOI: [10.1097/01.rlu.0000204131.93846.39](https://doi.org/10.1097/01.rlu.0000204131.93846.39)
9. Sato S, Koike T, Yamato Y, Yoshiya K, Honma K, Tsukada H. Resected well-differentiated fetal pulmonary adenocarcinoma and summary of 25 cases reported in Japan. *Jpn J Thorac Cardiovasc Surg* 2006; 54(12): 539-42. DOI: [10.1007/s11748-006-0048-8](https://doi.org/10.1007/s11748-006-0048-8)
10. Atoini F, Ouarsrani A, Elmejerreb C. A well-differentiated fetal adenocarcinoma of the lung with early local recurrence after limited resection. *Thoracic Cancer* 2011; 2(3): 123-7. DOI: [10.1111/j.1759-7714.2011.00047.x](https://doi.org/10.1111/j.1759-7714.2011.00047.x)
11. Furuya K, Yasumori K, Takeo S, et al. Well-differentiated fetal adenocarcinoma of the lung: early-phase sequential high-resolution computed tomographic findings. *J Comput Assist Tomogr* 2008; 32(5): 806-9. DOI: [10.1097/RCT.0b013e3181573e98](https://doi.org/10.1097/RCT.0b013e3181573e98)
12. Ouazzani El H, Jniene A, Bouchikh M, et al. Well-differentiated fetal adenocarcinoma: A very uncommon malignant lung tumor. *Rev Port Pneumol* 2011; DOI: [10.1016/j.rppneu.2011.06.003](https://doi.org/10.1016/j.rppneu.2011.06.003)
13. Politiek MJ, Vrugt B, Aalbers R. A 49-year-old woman with well-differentiated fetal adenocarcinoma. *Neth J Med* 2001; 58(4): 177-80. DOI: [0300-2977\(01\)00092-4](https://doi.org/0300-2977(01)00092-4)

**How to cite this case report:** Altintas N. A 31-Year-Old Man With Well-Differentiated Fetal Adenocarcinoma. *JJUMF* 2012; 19(2): 100-3. DOI: 10.7247/jjumf.19.2.7