

LEPTOSPIROSIS PRESENTED WITH PERICARDIAL EFFUSION, PLEURISY AND ASCITES: CASE REPORT

Nilgun ERTEN*, Bulent SAKA*, Mehmet Akif KARAN*, Cemil TAŞÇIOĞLU*,
Erdem POLAT**, Abdulkadir KAYSI*

SUMMARY

Leptospirosis, an infectious disease that affects humans and animals, is considered the most common zoonosis in the world. The infection causes a systemic illness that often leads to renal and hepatic dysfunction. Eighteen year old woman admitted to our clinic with cough, sore throat, fever, fatigue, maculopapular rash and monoarthritis. Joundice, hepatosplenomegaly and ascites were noted on physical examination. Pericardial and pleural effusion in addition to ascites were seen on computed tomography. Weil's syndrome was diagnosed with direct microscopy and ELISA test of the blood sample. Despite the prompt initiation of penicillin-G treatment with daily 24 million units in six equal doses, the patient died in 48 hours. Six weeks later blood culture result was reported as *Leptospira icterohaemorrhagiae*. Polyserositis is a rare clinical finding in leptospirosis. Together with fever, joundice, organomegaly and arthritis, Weil syndrome must be included in the differential diagnosis of polyserositis.

Key words: Leptospirosis, pericardial effusion, ascites, pleurisy

INTRODUCTION

Leptospirosis is a globally important zoonotic disease that affects humans mostly in temperate and tropical climates. Leptospirosis is a disease of the environment; transmission depends on interactions between humans and mammalian reservoir hosts, especially rats (5). Clinical signs are high fever, severe malaise, muscular pain, and conjunctival congestion. Jaundice and bleeding disorders can be seen in severe forms (2). In this report, a leptospirosis case was presented with the initial finding of polyserositis which is unusual in the clinical course of this disease.

CASE REPORT

Eighteen year old woman was admitted to our clinic with cough, sore throat, high fever and fatigue. One month ago maculopapular rash and monoarthritis had occurred and

computed tomography showed pericardial and bilateral pleural effusions with ascites. She was pale and had joundice. Tachypnea, tachycardia, a pansystolic murmur and third heart sound was detected. Hepatosplenomegaly and ascites were found on physical examination. Erythrocyte sedimentation rate was 80 mm/hour. Laboratory examination revealed, anemia (Hgb 84 g/L), thrombocytopenia (platelet count of 92000/mm³), blood-urea-nitrogen 22.8 mmol/L, creatinine 300.1 µmol/L, alanine transaminase 156 IU/L, aspartate transaminase 133 IU/L, total bilirubin 82.1 µmol/L and direct bilirubin 61.6 µmol/L. Ascites, pleural effusion and moderate pericardial effusion with thickened parietal pericardium were reported on CT scans (Figure 1,2,3). Biochemical analysis of ascites and pleural effusion samples revealed an exudate. Blood culture results were negative. Infero-apical pericardial effusion and insufficient left ventricular relaxa-

Received for publication: September 29, 2003

* Istanbul University, Istanbul Faculty of Medicine, Department of Internal Medicine, Capa, Istanbul, Turkey

** Istanbul University, Cerrahpasa Faculty of Medicine, Department of Microbiology and Clinical Microbiology, Kocamustafapasa, Fatih, Istanbul, Turkey

Figure 1. Pericardial effusion with thickened pericardium and pleural effusion were seen on computed tomography of the thorax.

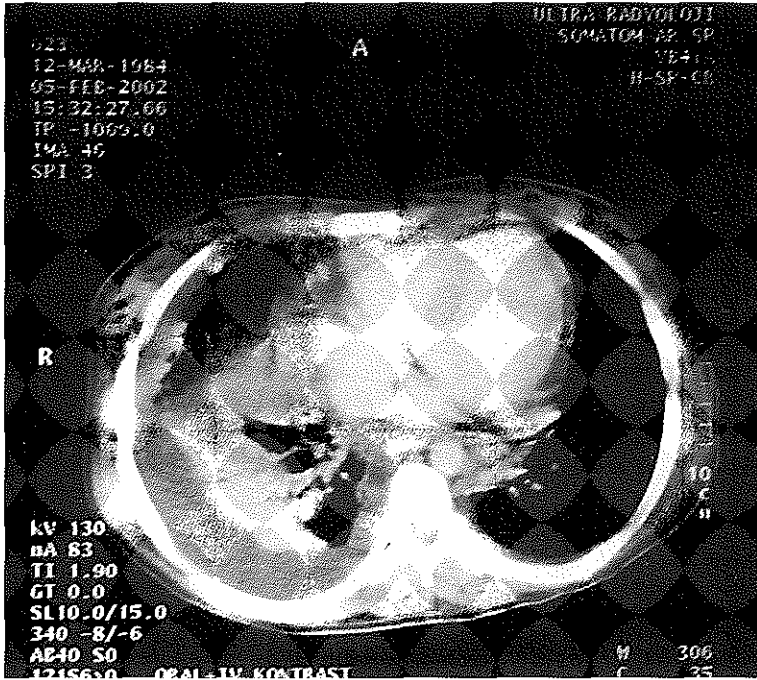
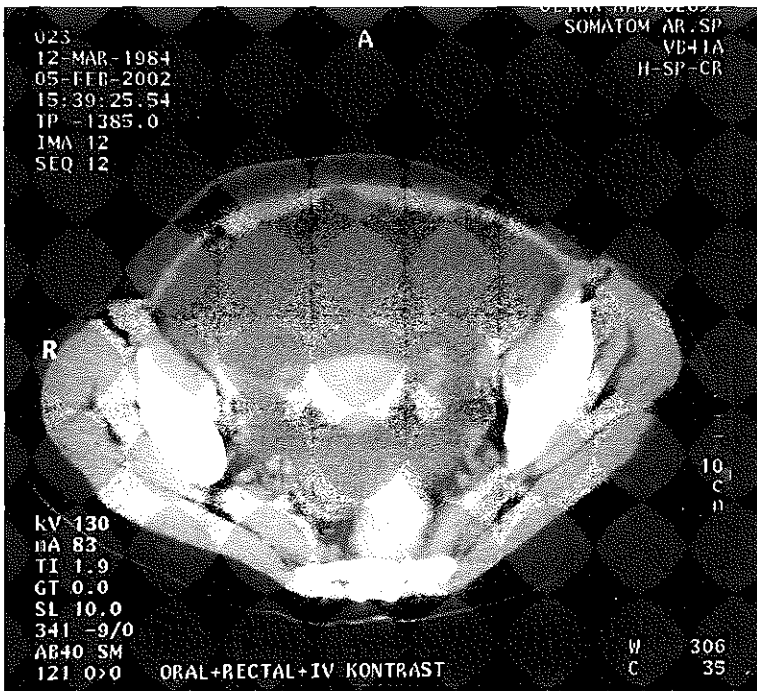


Figure 2. Abdominal computed tomography revealed massive ascites.



tion were noted on echocardiography. Antinuclear antibody and anti double-stranded DNA antibody tests were negative. Steroids (1.5 mg/kg prednisolone/day) was started on

a presumptive diagnosis of Still's disease. During the steroid treatment, gingival bleeding, epistaxis and macroscopic hematuria developed. Coagulation tests were highly suggestive of disseminated intravascular coagulation. Fresh frozen plasma and thrombocyte suspensions were given. Bone marrow biopsy revealed a normocellular bone marrow. No acid-fast bacilli (AFB) was noted on pleural effusion and ascitic fluid samples. Wright agglutination test was negative. Although being rare, direct microscopy and ELISA test were performed from blood samples for leptospirosis. After both tests were found positive, Weil's syndrome was diagnosed and penicillin-G 24 million units daily in six equal doses was started. Platelet counts plummeted down to 20000/mm³ and the patient developed extensive mucosal bleeding. The patient died on the second day of the treatment. Six weeks later, *Leptospira icterohaemorrhagiae* grew on blood culture.

DISCUSSION

Several systemic infections including tuberculosis and brucellosis are the most frequent causes of exudative polyserositis. Inflammatory rheumatic diseases especially rheumatoid arthritis, adult onset Still's disease, systemic lupus erythematosus (SLE) and polyarteritis nodosa

(PAN) are among the less common causes. Rheumatoid vasculitis, rarely seen with severe rheumatoid arthritis can involve multi-organ systems. Serum rheumatoid factor level is extremely high. In our patient there was monoarthritis involving knee joint which is not usual in rheumatoid arthritis and serum rheumatoid factor was negative. Negative anti nuclear and anti double-stranded DNA antibodies and lack of response to steroid treatment decreased the possibility of adult onset Still's disease and SLE. Polyserositis can occur in the late stages of PAN secondary to uremic nephropathy. In high grade leukemias and lymphomas, rarely multiorgan failure develops after generalized infiltration.

Few cases have been reported about leptospirosis and involvement of the serosal surfaces. Pericardial friction rub and related electrocardiographic changes were noted as pericarditis in one patient but pericardial effusion was absent (7). Non-segmentary opacities caused by alveolar infiltrations, pleural effusion and ascites due to leptospirosis were reported rarely (3,4,6). Leptospirosis can

progress to sepsis, named Weil's syndrome, presenting with jaundice, increased bleeding tendency and multiorgan failure (1).

Despite the fact that polyserositis is an uncommon manifestation of Leptospirosis, our case suggests that Weil's syndrome should be included in the differential diagnosis, especially in cases presenting with high fever, jaundice and organ enlargement.

REFERENCES

1. Coursin DB, Updike SJ, Maki DG. Massive rhabdomyolysis and multiple organ dysfunction syndrome caused by leptospirosis. *Intensive Care Med* 2000; 26: 808-812.
2. Kobayashi Y. Clinical observation and treatment of leptospirosis. *J Infect Chemother* 2001; 7:59-68.
3. Lee RE, Terry SI, Walker TM, Urquhart AE. The chest radiograph in leptospirosis in Jamaica. *Br J Radiol* 1981; 54: 939-943.
4. Matos ED, Costa E, Sacramento E, Caymmi AL, et. al. Chest radiograph abnormalities in patients hospitalized with leptospirosis in the city of Salvador, Bahia, Brazil. *Braz J Infect Dis* 2001; 5: 73-77.
5. Vinetz JM. Leptospirosis. *Curr Opin Infect Dis* 2001;14:527-538.
6. Wang SC, Wang YM. Leptospirosis: report of one case. *J Microbiol Immunol Infect* 1999; 32: 129-132.
7. Watt G, Padre LP, Tuazon M, Calubaquib C. Skeletal and cardiac muscle involvement in severe, late leptospirosis. *J Infect Dis* 1990; 162: 266-269.