

## A CASE OF COEXISTENT ADENOCARCINOMA OF THE STOMACH AND T-CELL LYMPHOMA OF THE STOMACH AND JEJUNUM

### *MİDE ADENOKARSİNOMU VE MİDE VE JEJUNUMDA T-HÜCRELİ LENFOMANIN BİRLİKTE GÖRÜLDÜĞÜ BİR OLGU*

Oktar ASOĞLU\*, Hasan KARANLIK\*, Çağatay KORKUT\*, Yavuz BOZFAKİOĞLU\*,  
Yersu KAPRAN\*\*, Mehmet AĞAN\*\*

#### ABSTRACT

A case with a rare coexistence of adenocarcinoma of the stomach and T-cell lymphoma of the stomach and jejunum, diagnosed postoperatively, was reported. The patient underwent surgical intervention for passage problems and a distal subtotal gastrectomy and Roux-En-Y gastrojejunostomy were performed and the approach for the intestinal lymphoma was discussed.

**Key words:** Gastric adenocarcinoma, intestinal lymphoma

#### INTRODUCTION

Although primary gastric malignant lymphoma, first described by Theodor Billroth in 1871, accounts for slightly more than 10% of all lymphomas at extranodular sites, it is a relatively rare clinical event, representing only 1% of all malignant diseases of the stomach. In addition, such diseases mostly tend to be B-cell lymphoma, while T-cell lymphoma is extremely rare (9). This case of coexistent malignant lymphoma of the stomach, jejunum and carcinoma of the stomach reported here is unusual and worthy of discussion.

#### CASE

A 57-year-old man was brought to our institution with a recent history of abdominal pain, anorexia, nausea, and vomiting over a 2-month period. His recent medical history was significant due to his 20 kg weight loss in six months. He had no diarrhea. He used drugs irregularly for schizophrenia. A diagnostic upper gastrointestinal system endoscopy was performed and a vegetative mass on the antrum of the stomach, also an ulcerative lesion on the corpus were found. The pylorus was decentralized and deformed. A biopsy was carried out which revealed adenocarcinoma with signet ring cells. The patient's blood count, biochemical profile and tumor markers (AFP, CEA; CA19-9) were in normal ranges, except for hypoalbuminemia (serum albumin level: 1.9 g/dl). The serologic tests for hepatitis A, B, C and HIV were performed and the results were negative. Subsequent abdominal CT revealed diffuse thickening of the gastric wall located at the antrum. There were no significant lymph nodes at any area including

the paraaortic area and distant metastases. Total parenteral nutrition and human albumin solution (20% 100 ml 2 x 1 IV) were given for 10 days preoperatively, because of hypoalbuminemia and his nutritional status. Deep venous thrombosis prophylaxis was administered (enoxaparin sodium 0,4 ml 1 x 1 SC). Afterwards, laparotomy was performed. During the exploration, a 6 x 5 cm tumor on the antrum of the stomach was observed, which did not invade serosal surface. There were three obstructing masses in the first 50 cm of the jejunum from the Treitz ligament with invasion of the serosal surface and there were conglomerated lymph nodes on the meso-intestinum and paraaortic area. A sampling of these lymph nodes was made intraoperatively and there were no signs of adenocarcinoma metastasis or lymphoma during the frozen section examination. Due to the obstruction of the small intestine, distal subtotal gastrectomy and Roux-En-Y gastrojejunostomy with 55 cm resection of the jejunum with duodeno-jejunostomy were performed. An antibiotic with broad-spectrum coverage was initiated (ampicillin/sulbactam 4 x 1 g/day). The patient was extubated and taken out of the operating room. The day after, his general physical status had worsened; he became dyspneic, tachypneic, and hypoxemic (pH: 7.25, pCO<sub>2</sub>: 55 mmHg, pO<sub>2</sub>: 61mmHg, HCO<sub>3</sub><sup>-</sup>: 29 mmol/l). The patient was re-entubated and relocated in the reanimation ward. The day after, his body temperature was 38.4 °C and leukocyte and platelet counts were 4200 /mm<sup>3</sup> and 35 000 /mm<sup>3</sup>, respectively. His trachea, urine and blood cultures were taken and were found sterile. The blood count revealed pancytopenia with Hb of 7.3 g/dl, Hct of 22%,

Date received/Dergiye geldiği tarih: 22.03.2004

\* Istanbul University, Istanbul Faculty of Medicine, Department of Surgery, Çapa, Istanbul, Turkey

\*\* Istanbul University, Istanbul Faculty of Medicine, Department of Pathology, Çapa, Istanbul, Turkey

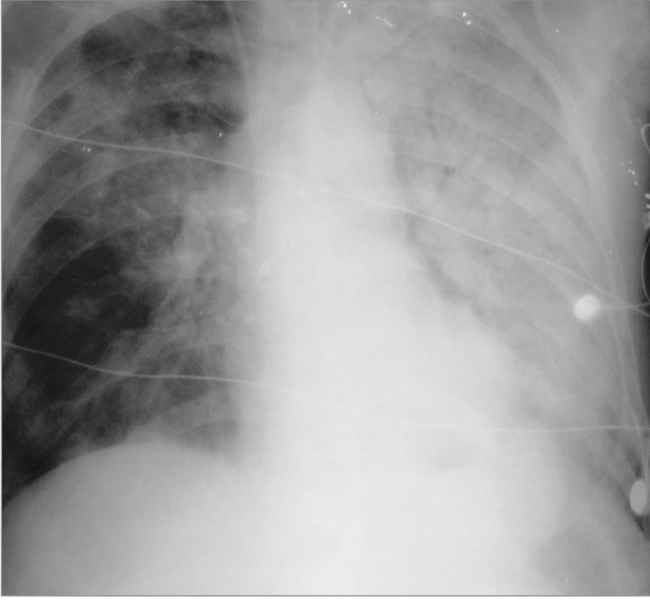
leukocyte count of 2700 /mm<sup>3</sup> and platelet count of 27 000/mm<sup>3</sup>. A blood smear confirmed the pancytopenia. The biochemical profile of the blood was normal except for the observation of hypoalbuminemia (2.4 g/dl) and the coagulation tests (prothrombin time: 21.5 seconds, partial thromboplastin time: 73.1seconds and INR: 1.97). Fresh frozen plasma solutions were administered. An abdominal CT was performed to

look for a possible intraabdominal sepsis. No anastomotic leakage or intraabdominal fluid collection were found. A disseminated bronchopneumonia was diagnosed from his chest X-ray. On the 5th postoperative day, the patient died of the bronchopneumonic sepsis (Figure 1).

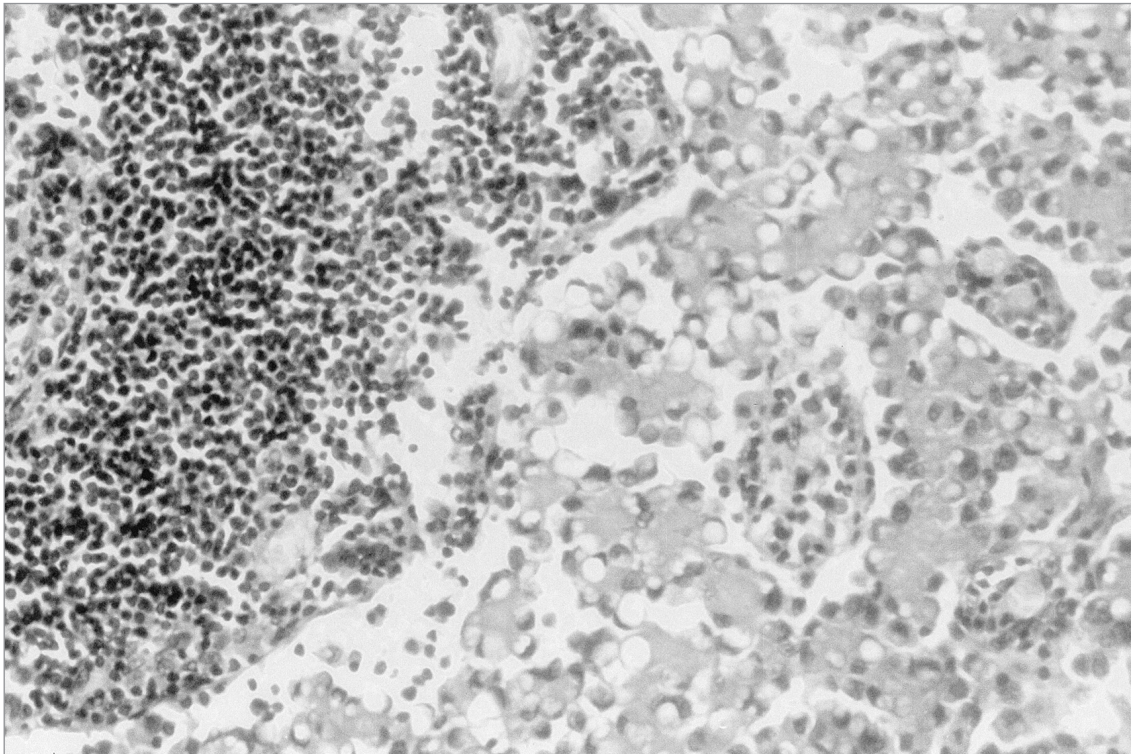
On the pathological examination of the specimen, one polypoid tumoral mass having the measures of 5 x 4 x 3 cm was found on the antrum and an additional ulcerous lesion -2 cm in diameter- was apparent in the corpus of the stomach. On the resected specimen of the intestine, there were three multifocal tumoral lesions of 3 cm in diameter, the greatest tumor, located at 22 cm and 15 cm distance from each other and were separated with normal, intact mucosa, which obstructed the intestinal lumen and infiltrated the intestinal wall.

Histological examination of the gastric ulcerous lesion revealed signet cell carcinoma limited to the mucosal layer, but with metastasis at two of the peri-gastric lymph nodes (Figure 2). The tumors of the intestine had invaded the serosa and metastasized two of the lymph nodes. The surface epithelium of both the polypoid lesion of the stomach and the tumors of the intestine were ulcerated. Beneath the ulcerous area, an infiltration of evident pleomorphic lymphoid cells with large nuclei and prominent nucleoli was observed. In the stroma, there was dense eosinophilia (Figures 3A, 3B, 4A, 4B). There were no morphologic or histopathologic findings related to enteropathy on the intestinal mucosa other than the tumor.

The immunphenotype of the tumoral cells revealed that the neoplastic cells were positive for CD30, LCA, CD43 and perforin and negative for CD20, granzyme B, CD2, CD3, CD5, ALK1, fascin, CD15 and EBV (Figure 4A, 4B). With these



**Figure 1. Patient's chest X-ray with disseminated bronchopneumonia**



**Figure 2. Metastasis of signet cell carcinoma in the lymph node with cytokeratin dye (x500).**

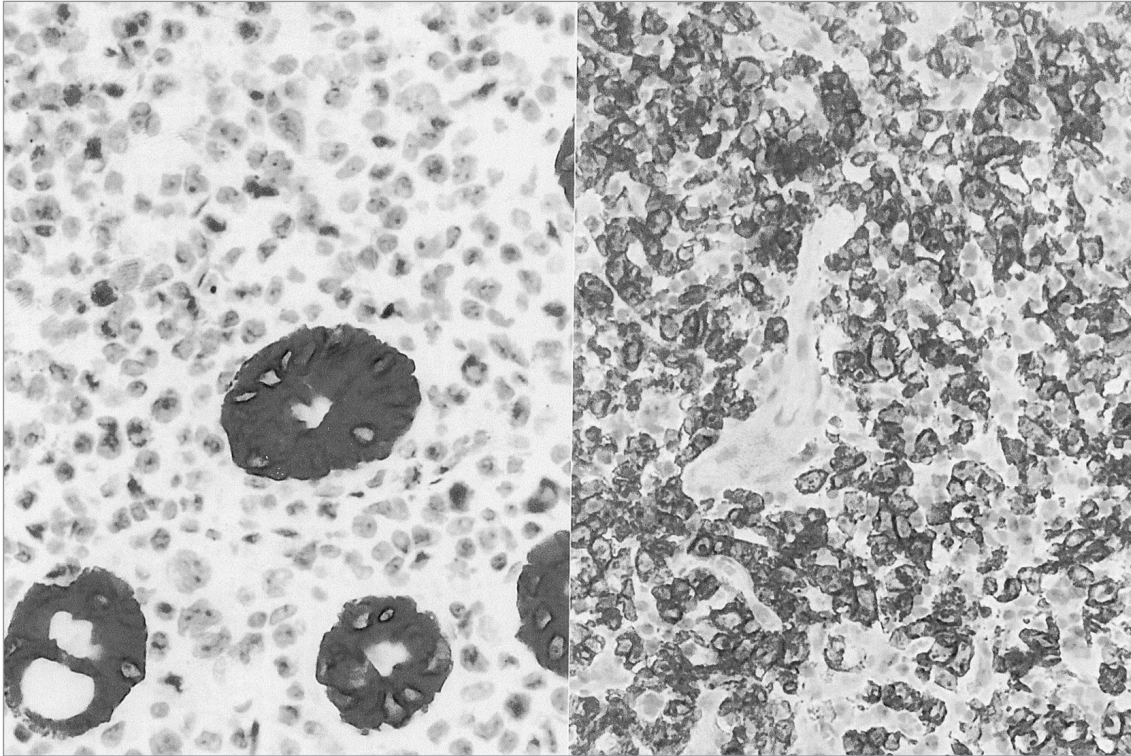


Figure 3A. Pleomorphic tumoral lymphoid cells in the mucosa (HEx500).

Figure 3B. Cells resembling Reed-Sternberg cells (HEx500).

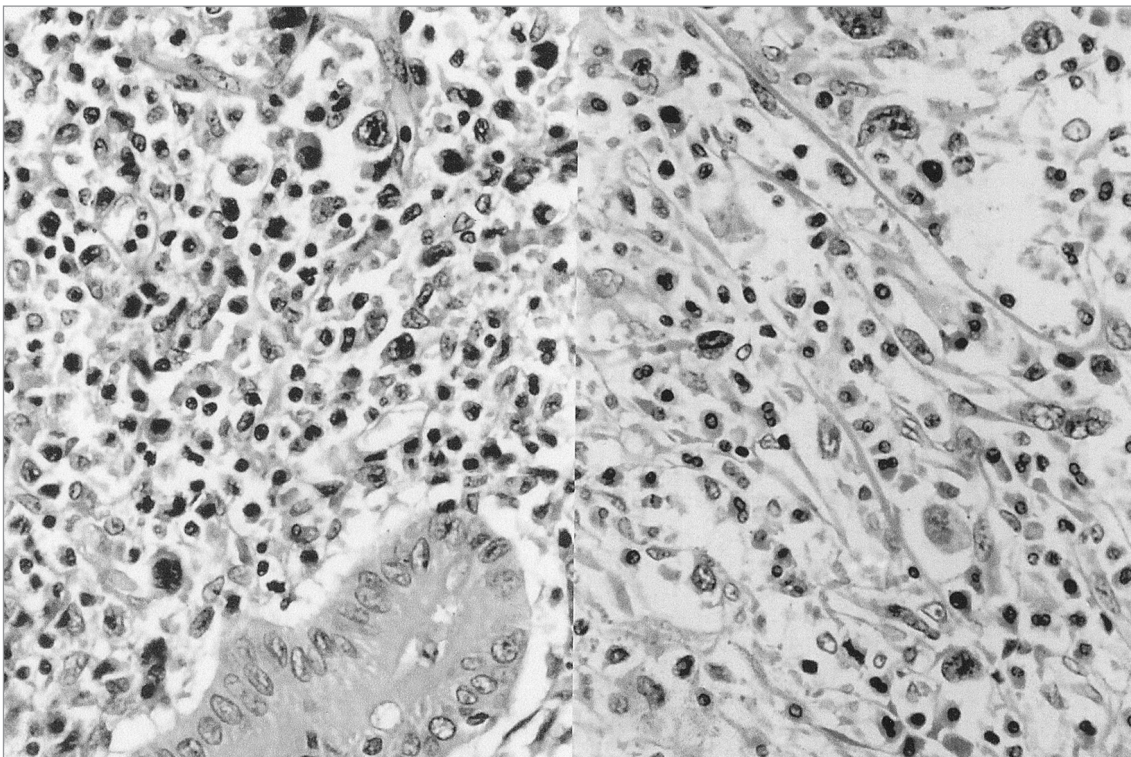


Figure 4A. CD30 (+) tumoral lymphoid cells on gastric specimen.

Figure 4B. The tumoral cells are seen (-) and the epithel cells of the mucosa are seen (+) at the same specimen with the cytokeratin dye.

immunphenotypic and histopathologic findings, this patient was diagnosed as CD30 (+) anaplastic large cell lymphoma.

## DISCUSSION

Malign lymphoma of the stomach has rarely been reported in association with gastric cancer. In addition, primary T-cell lymphoma of the stomach is a rare disease, most gastric lymphomas being of B-cell type (9). According to our literature review, only 3 cases of primary T-cell lymphoma associated with gastric cancer have previously been reported (2, 6, 7).

Although, the majority of the T-cell lymphomas within the gastrointestinal tract are associated with enteropathy (1, 5, 8), the case presented here had no diarrhea; in addition no enteropathy proved by pathological examination was found.

The tumor cells of the presented case showed CD30 (+), CD43 (+), LCA (+) and perforin (+) immunophenotype. These findings are in concordance with CD30 (+) T-cell lymphoma. Enteropathy-associated T-cell lymphomas can show a CD30 (+) phenotype, however our case had no enteropathy proved by microscopic examination. Infiltration of eosinophilic cells were determined by microscopy and confirmed the diagnosis of the T-cell lymphoma (4).

According to the Ann Arbor classification, our patient had stage I2EA T-cell lymphoma. Due to the possibility of perforation or hemorrhage of the tumor after radiotherapy or chemotherapy, en bloc resection of the tumor and regional lymph nodes including a margin of normal tissue in the specimen is the treatment of choice according to most publications for this stage of the lymphoma (3, 5).

Our patient was admitted to the clinic with acute abdominal pain accompanied by abdominal distension and bilious vomiting. The CT scan and endoscopic examination revealed that there is no pathology which could explain the obstruction. On the laparotomy, mass lesions in the first 50 cm of the proximal jejunum were seen. Because of the antrum filling gastric tumor and the jejunum obstructing lesions, a distal subtotal gastrectomy and Roux-En-Y gastrojejunostomy were performed. During the postoperative course, after the worsening of the physical status of the patient, a CT was taken to investigate the possible existence of an anastomotic leakage. There was no intraabdominal pathology. The patient's white blood cell and thrombocyte count decreased. Bronchopneumonia was observed in his chest X ray. Although the cultures taken from the trachea and the blood were found sterile, the patient was thought to have died of a disseminated infection caused a viral or mycotic agent, which could not be cultured, accelerated by the immunodeficiency due to his malignant immune system

disease and by his surgical stress condition.

In conclusion, the most important point that should be grasped from the presentation of this unusual case is that it is important to keep in mind the possibility of a second or an unexpected tumor even there is a pathologically proven diagnosis and to recall the probability of immunosuppression in a case of T-cell lymphoma. If a lesion is found on the jejunum resembling a bunch of grapes, the intestinal lymphoma should be considered and if there is no obstruction, aggressive surgery should not be attempted. Otherwise, a by-pass procedure or a limited resection should be considered. Although most of the gastrointestinal lymphomas are associated with enteropathy, it is important to note before the treatment decisions for the patient that it is not a definite rule. The possibility of a gastrointestinal lymphoma should be kept in mind even for an emergent surgical intervention for gastrointestinal obstruction.

## REFERENCES

1. Dieter RS, Duque K. Enterotherapy associated T-cell lymphoma: a case report and literature review. *WMJ* 2000; 99: 28-31.
2. Kang SK, Chang SE, Choi JH, Sung KJ, Moon KC, Koh JK, Huh JR. Occurrence of angiosarcoma and gastric adenocarcinoma following a cutaneous CD30-positive anaplastic large cell lymphoma. *Br J Dermatol* 2002; 147:818-820.
3. Mafune KI, Tanaka Y, Suda Y, Izumo T. Outcome of patients with non-Hodgkin's lymphoma of the stomach after gastrectomy: clinicopathologic study and reclassification according to the revised European-American lymphoma classification. *Gastric Cancer* 2001; 4:137-143.
4. Sadahira Y, Akisada K, Sugihara T, Hafa S, Uehira K, Muraki N, Manabe T. Comparative ultrastructural study of cytotoxic granules in nasal natural killer cell lymphoma, intestinal T-cell lymphoma and anaplastic large cell lymphoma. *Virchows Arch* 2001; 438: 280-288.
5. Samel S, Wagner J, Hofheinz R, Sturm J, Post S. Malignant intestinal non-Hodgkin's lymphoma from the surgical point of view. *Onkologie* 2002; 25: 268-271.
6. Seki Y, Toba K, Nagai K, Shinada S, Hattori A, Shibata A. IBL-like T cell lymphoma associated with early gastric cancer: a case report. *Rinsho Ketsueki* 1989; 30:111-115.
7. Tsuchiyama J, Yoshino T, Imajo K, Kondou E, Hamada E, Tomiyama Y, Toba K, Furukawa T, Fuse I, Aizawa Y, Harada M, Tsubota T. Lymphomatous polyp of mantle cell type in the duodenum complicated by gastric cancer: a case of trisomy 3 and t(11;14)(q13;q32). *Ann Hematol* 2002; 81:224-227.
8. Watanabe M, Moriyama Y. Primary gastric T-cell lymphoma without human T-lymphotropic virus type 1: report of a case. *Surg Today* 2002; 32: 525-530.
9. Zaubner NP, Berman EL. Synchronous and metachronous primary gastric lymphoma and adenocarcinoma: a clinicopathologic study of 12 patients. *Cancer* 1998; 82:226-227.