

“CASE REPORT: TWO PIECE HOLLOW BULB OBTURATOR FOR POSTSURGICAL PARTIAL MAXILLETOMY DEFECT IN DENTULOUS PATIENT.”

¹Dr. Poonam Agarwal, ²Dr Rupal J. Shah

¹ Postgraduate Student, ² Head & Professor

Department of Prosthodontics, Government Dental College & Hospital,

Ahmedabad-380016, Gujarat.

Corresponding author: Dr. Poonam Agarwal ; Email id :poonamsomu@yahoo.com

Abstract:

Rehabilitation of the missing oral and extra oral structures is one of the main aim of prosthodontics. Each patient has a different types of defect that presents with its own limitations and difficulties for successful rehabilitation. Defect of any extend result from surgical treatment of benign and malignant neoplasms, trauma, or congenital defects ,causes problems in mastication, speech and esthetics. So, prosthetic rehabilitation with an obturator is a predictable intervention as it allows restoration of esthetics and function. Lack of support, retention, and stability are common prosthodontic treatment problems for patients who have had a maxillectomy. Hollow bulb obturator reduce the weight of the prosthesis and make it lighter thereby reducing the pull of gravity. Factors that affect the prosthetic prognosis for these patients are the size of defect, number of remaining teeth, amount of remaining bony structure, quality of existing mucosa, radiation therapy, and patients own ability to adapt to the prosthesis. In the present case hollow bulb obturator has been planned for restoration of the defect, which helps in reducing the weight of the prosthesis.

Keywords: Aramany class I defect , Hollow bulb obturator, Two-piece complete obturator

Background:

Maxillary defects result from surgical treatment of benign and malignant neoplasm, trauma, or congenital defects.⁽¹⁾ The patient with an acquired maxillary defect should be provided with an obturator prosthesis that is comfortable, restores adequate speech, deglutition and masticatory function, and is acceptable cosmetically.⁽²⁾ The primary goal of prosthetic obturation is closure of the maxillectomy defect and separation of the oral cavity from the sino-nasal cavities.⁽³⁾ Instability of the obturator results in air and fluid leakage through the nasal cavity and thereby compromises function.⁽⁴⁻⁶⁾

Aramany^(7,8) proposed a defect classification system that presents differences of mechanics in 6 classes that are acknowledged in the prosthetic design of an obturator framework for partially edentulous patients. A

definitive obturator for a partially edentulous patient has 2 main components: a metallic framework and an acrylic resin obturator bulb. Important considerations in the design of the framework are the size and location of the defect as they relate to the remaining palate and dentition. The stabilization of the obturator bulb and its intimacy with the soft tissues that line and surround the defect are thought to minimize adverse effects such as nasal leakage and hypernasal speech. Fabrication of an obturator involves fundamental principles of removable partial denture framework design and techniques that are characteristic for the maxillectomy defect.

Numerous references in the literature describe various methods for fabricating open and closed hollow obturator prostheses.^(1,5) Both types of obturators allow for the fabrication of a lightweight prosthesis readily tolerated by

the patient, while effectively extending into the defect. By fabricating a hollow maxillary obturator, the weight of the prosthesis may be reduced by up to 33%.⁽⁹⁾

In this article, Impression techniques and method of fabrication of two piece closed hollow bulb obturator for partially maxillectomy patient (Aramany class I defect) are described here.

Case Report:

A male patient aged 40 years, who had undergone surgery for a maxillary tumour on the left side of the maxilla was referred from the Gujarat Cancer Research Institution (GCRI) to the Prosthodontics Department of Government Dental College And Hospital, Ahmedabad, Gujarat, for the rehabilitation of the defect. On intra-oral examination, there was a defect on the left side of the maxilla of the patient which was extending anteriorly up to the midline and posteriorly up to the posterior extent of hard palate, superiorly almost to the floor of the orbit, mesially to the nasal septum and laterally, the entire buccal aspect and the defect was including mainly the alveolus portion of the maxilla. Teeth were present from central incisor to the second molar on the right side of maxilla and in mandible from right second premolar to the left second premolar and all teeth were intrinsically stained, mouth opening was average.

On extra-oral examination, patient's left side of the face was disfigured and the skin below the infra-orbital margin was depressed with scar, surgical scar was also seen in the midline of the upper lip.

Patient was experiencing difficulty in mastication and deglutition due to nasal reflex of food and also complained of hyper nasal speech.

Treatment plan:

On the basis of extent of the defect as per Aramany class I, a closed hollow bulb obturator was planned for this patient. In this patient Aramany class I design was not

followed because the condition of the remaining teeth was not favourable to follow the the design. So, two piece hollow bulb obturator with continuous clasp on remaining teeth was planned for the retention and stability of the prosthesis. And in mandible simple removable partial denture was planned in place of missing teeth.

Procedure:

1. Primary impression was made in the putty consistency of the rubber base impression material and a primary cast was retrieved out. Then the undercuts on the side of the defect were blocked with the wax and also, the internal part of the defect recorded in the primary impression was painted with the thin layer of the wax on the primary cast before making acrylic custom tray on the defect area (custom tray was made in the region of denture wearing area and defect area).
2. Final impression of the defect area was made in the putty and light body of the rubber base impression material, then the dual impression with final impression in place was made with stock metal tray, final cast with accurate reproduction of defect portion was retrieved out. (figure-1)
3. Again, the minor undercuts in the defect were blocked out using the modeling wax and a thin layer of wax up was done, then the entire assembly was flaked and dewaxed. Now, a heat polymerized acrylic resin was mixed and a small amount of dough was pressed on to the bottom of the defect and the curing was done in the conventional manner, flask was opened and then around the walls of inner portion of the bulb

defect was filled to the level of the remaining palate with the thick mix of the plaster, after setting of the plaster, wax up was done to contoured to the shape of the palate on the non-defect side and, again the entire assembly was flaked and dewaxed, now after opening of the flask the defect area in the base of the flask filled with the table salt and covered with a cellophane sheet. Then a heat polymerized acrylic resin was mixed and a small amount of dough was placed on to the counter portion of the flask and then flask was closed and trial closure was done, the flask was opened again and removal of cellophane sheet and table salt was done and this was followed by closure of the two portion of the flask again. In all this procedure we used separating media wherever needed, then the curing was done in the conventional manner, after that de-flasking, polishing, and finishing of the prosthesis was done and then heat cure hollow bulb was ready to place in the patient mouth, before placing in the patient mouth a handle was attached on to the outer surface of the bulb in alignment of the arch form.

4. After placing the hollow bulb in the patient mouth pick up impression was taken in putty consistency of the rubber base impression material, then the hollow bulb was removed from the impression and then beading, boxing and pouring of the impression was done and final cast was removed for fabrication of the second part of the prosthesis. (figure-2)
5. Shellac denture base was adapted on the final cast and wax rim was made for jaw relation, and then jaw relation was recorded with the

hollow bulb in position in the patient mouth. (Figure-3)

6. The rules of esthetics were born in the mind during the selection and setting of the teeth and, then waxed up denture were tried in the patient mouth and checked for retention, stability and comfort. Phonetics was checked and corrections were made accordingly, this was done when the hollow bulb was in place in the patient mouth.
7. Before commencing with the laboratory procedure, a continuous clasp of 19 gauge wire was adapted to the remaining teeth on the final cast for the retention of the prosthesis in the mouth.
8. Now, the second part of the prosthesis with the replacement of missing teeth is ready, here the both parts are separate and the first part (hollow bulb) locked in the second part (denture part) with the help of the handle, patient can wear or remove both parts his self and he can also separate them for cleaning. (Figure-4)
9. Patient was happy with the masticatory efficiency and the improved quality of speech instantaneously. Necessary instructions were given on technique of placement, removal and maintenance of the prosthesis. Post-insertion follow-up and patient care were carried out at the regular intervals of time.

Discussion:

Obturator prosthesis play an important role in the recovery of oral function in postsurgical maxillectomy patients.⁽¹⁰⁾ Lack of support, retention, and stability are common prosthodontic treatment problems for patients who have had a maxillectomy. A hollow bulb prosthesis (either one piece or two piece) is a better Choice, as it is lighter in weight and is more hygienic. Light weight has also been considered for maxillary resection prosthesis, by Chalian and Barnett.^(11,12)

In the year 1972, they explained a simple technique of fabricating a single- piece, hollow obturator prosthesis. Tanaka et al.⁽¹³⁾ in 1977 simplified the fabrication process for a light weight obturator. They felt that using polyurethane foam as core to reduce the weight of the obturator would be efficient and economical. Parel and LaFuente⁽¹⁴⁾ in 1978 formed a hollow prosthesis in single visit. First a resilient liner material was adapted to the defect on all surfaces except at the palatal side. This was then filled with sugar to the level of the palate. Autopolymerizing resin was used to form the lid for the palatal side. Sugar was drained later through a small bur hole on the lid, which was sealed with more autopolymerizing resin. Beder and Todo⁽¹⁵⁾ in 1978 explained yet another rapid technique for constructing a hollow bulb.

They used hollow plastic forms of different shapes and sizes, which were modified according to the requirements. They were enclosed in autopolymerizing resin to form to forms the walls of the defect. Phankosol and Martin⁽¹⁶⁾ in the year 1985 developed a technique for constructing a hollow obturator with a removable lid combining the benefit of both closed and open hollow obturators. In the present case bulb was fabricated with heat cured acrylic resin, as the unreacted monomer being less in heat polymerized acrylic resin and risk of its leaching is also reduced.

Acknowledgements:

The authors are very thankful for Support from The Department Of Prosthodontics, Government Dental College and Hospital, Ahmedabad , Gujarat .

References :

- 1.Desjardins RP: Obturator prosthesis design for acquired maxillary defects. J Prosthet Dent 1978;39:424-435
- 2.MacCarthy and Murphy. Replacement of an obturator section of an existing two-piece implant- retained edentulous obturator. J Prosthet Dent 2000;83:652-5.
- 3.Okay et al: Prosthodontic guidelines for surgical reconstruction of the maxilla: A classification system of defects. J Prosthet Dent 2001;86:352-63.
- 4.Minsley GE, Warren DW, Hinton V: Physiologic responses to maxillary resection and subsequent obturation. J Prosthet Dent 1987;57:338-344
- 5.Watson RM, Gray BJ: Assessing effective obturation. J ProsthetDent 1985;54:88-93
- 6.Shipman B. Evaluation of occlusal force in patients with obturatordefects. J Prosthet Dent 1987;57:81-4.
- 7.Aramany MA. Basic principles of obturator design for partially edentulous patients. Part I: classification. J Prosthet Dent 1978;40:554-7.
- 8.Aramany MA. Basic principles of obturator design for partially edentulous patients. Part II: design principles. J Prosthet Dent 1978;40:656-62.
- 9.Oh W, Roumanas ED: Optimization of maxillary obturator thickness using a double-processing technique. J Prosthodont 2008;17:60-63
- 10.Curtis TA, Beumer J, Rehabilitation of acquired hard palate defects. In: Beumer J, Curtis TA, Marunick MT (eds). Mxillofacial Rehabilitation, Prosthodontic and Surgical Considerations, ed 1. St. Louis: Ishiyaku Euro-America, 1996:225-284.

11. Chalian VA, Barnett MO. A new technique for constructing a one-piece hollow obturator after partial maxillectomy. J Prosthet Dent 1972;28:448-53.
12. Chalian VA, Drane JB, Standish M. Maxillofacial Prosthetics: Multidisciplinary Practice. The Williams and Wilkins Co: 1971. P. 133-48.
13. Tanaka Y, Gold HO, Pruzansky S. A simplified technique for fabricating a light weight obturator. J Prosthet Dent 1977;38:638-42.
14. Parel SM, LaFuente H. Single- visit hollow obturators for edentulous patients. J Prosthet Dent 1978;40:426-9.
15. Beder OE, Todo J. Rapid technique for constructing a hollow -bulb provisional obturator. J Prosthet Dent 1978;29:237-9.
16. Phankosol P, Martin JW. Hollow obturator with removable lid. J Prosthet Dent 1985;54:98-100.

Legends :

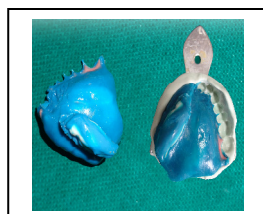

Figure 1: Final impression of defect for hollow bulb fabrication in rubber base impression material

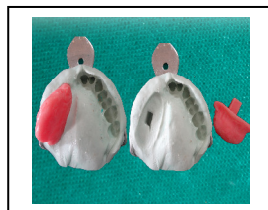


Figure 2: Final pick-up impression with hollow bulb for final second component prosthesis fabrication

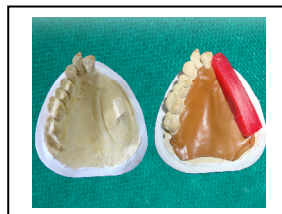


Figure 3: Final cast with wax rim

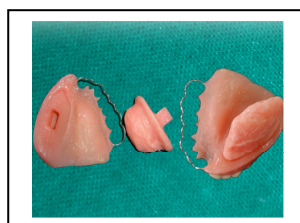


Figure 4: Final finished and polished two piece hollow bulb obturator

Source of support: Nil; Conflict of Interest: Nil
Date of submission: 08 Nov 2012
Date of Provisional Acceptance: 17 Nov 2012
Date of Peer review approval: 22 October 2012
Date of final drafting: 24 November 2012
Date of Publication: 2 December 2012