

## Case Report:

### Superficial Palmer Arch: Some Interesting Variations

Sharmistha Biswas<sup>1</sup>, Paromita Mukhopadhyay<sup>2</sup>, Sushmita Sen<sup>3</sup>,  
Sarmistha Chakraborty<sup>3</sup>, Biswapriya Sinha<sup>3</sup>, Hasi Dasgupta<sup>4</sup>

<sup>1</sup> Associate Professor, NRS Medical College, Kolkata

<sup>2</sup> Assistant Professor, NRS Medical College, Kolkata

<sup>3</sup> Post Graduate Trainees, NRS Medical College, Kolkata

<sup>4</sup> Professor, NRS Medical College, Kolkata

Corresponding author:- Sharmistha Biswas

Date of submission: 04 October 2014 ; Date of Publication: 10 December 2014

---

#### Abstract

The superficial palmer arch is formed by superficial division of ulnar artery and completed on radial side by either of the superficial palmar branch of radial artery, arteriaprincepspollicis, arteriadirialisindidis or arterianervimediana. It may be incomplete at times. It lies beneath the palmar aponeurosis and in front of long flexor tendons, lumbricals and palmar digital branches of median nerve. Awareness of the superficial palmer arch variation in the hands is essential for surgeons, radiologists and anatomists because of innovative microsurgical techniques in reconstruction of a traumatized hand, arterial repairs and may be useful for vascular graft surgeries. Variations in the superficial palmer arch have been studied by several authors.

We intended to study superficial palmer arch in twenty pairs of hands in a course of two years and report the variations. We dissected forty palms of twenty cadavers over 2 years during routine dissection for undergraduate teaching in a medical college of Kolkata, India. Bilateral variations of superficial palmer arch were observed in three pairs of palms. Of them, one pair was complete arch, other two incomplete, though they again differed in distribution.

With high rate of road traffic accidents in today's world, and increasing needs of surgical reconstruction procedures of hand and vascular graft application, it has become essential to acquire knowledge of anatomical variation of superficial palmer arch. Such knowledge is also essential to have proper interpretation and performance of the diagnostic angiography and therapeutic surgery in case of ischemic changes in fingers.

**Key words:** superficial palmer arch, incomplete arch, palmer arch variations

---

#### Introduction

The arterial supply of the hand on the volar aspect consists of two systems, superficial and deep palmer arches. The superficial palmer arch is mainly contributed by ulnar artery, passing superficial to flexor retinaculum, then curving laterally to form an arch, lying just deep to palmer aponeurosis.<sup>1</sup> It is located just

deep to palmer aponeurosis and is superficial to digital branches of median nerve, long flexor tendons of forearm and lumbricals of palm.<sup>2</sup> A classic type of superficial palmer arch fed by superficial division of ulnar artery and completed by superficial palmer branch of radial artery is found only in 34.5% of the cases<sup>1,3</sup>. Coleman & Anson<sup>4</sup> have categorised superficial

palmer arch saying that in about 1/3<sup>rd</sup> cases they were formed by the ulnar artery alone; in 1/3<sup>rd</sup> cases, completed by the superficial palmer branch of radial artery and in another 1/3<sup>rd</sup> either by the arteriarradialisindicis or arteriaprincepspollicis or persistent median artery. The arteriaprincepspollicis arises from the radial artery just as it turns medial ward to the deep part of the hand; arteriarradialisindicis arises close to the preceding <sup>1</sup>. Five cases were described where the first web space of the hand received arteries only from the superficial palmer arch<sup>5</sup> instead of the trunk of radial artery. The anastomosis between ulnar and radial arteries in hand is significant, because it plays an important role in collateral circulation in any disease condition of palm. Variations in the superficial palmer arch have been studied by several authors.

Awareness and identification of the superficial palmer arch variation in the hands is essential for surgeons, radiologists and anatomists because of innovative microsurgical techniques in reconstruction of a traumatized hand, arterial repairs and may be useful for vascular graft surgeries, when the arteries of the upper limb are used for coronary artery bypass<sup>6</sup>. We intended to study superficial palmer arch in twenty pairs of hands in a course of two years and report the variations.

#### **Materials and methods:**

Both right and left palms of twenty formalin-preserved cadavers were dissected during routine dissection for undergraduate teaching over a period of two years (2013-2014) in a medical college of Kolkata, India, to observe the formation and branching of superficial palmer arch. Those arches with variations were painted and photographed.

#### **Results :**

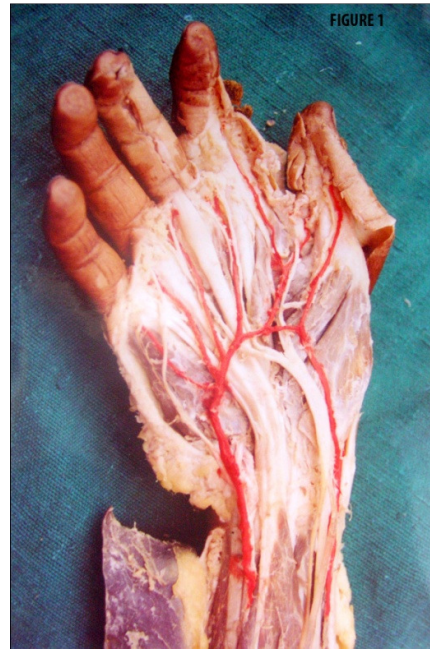During routine dissection of twenty cadavers over 2 years, (from 2013-2014) for undergraduate

teaching in a medical college of Kolkata, India, some variations of distribution of arteries of three pairs of palms were revealed. All the variations were bilaterally present.

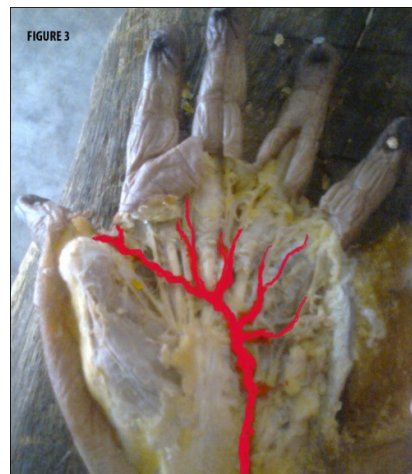
1) The first case that we want to report was a middle-aged Indian male cadaver in whom a rare variation of arteries in both the palms was revealed (Figure 1). The superficial branch of ulnar artery joined the superficial palmer branch of radial artery to form the superficial palmer arch. The arch gave rise to six branches. The medial-most branch went to the medial border of the little finger. The next three branches joined with the palmer metacarpal branches of deep palmer arch, forming the common digital arteries supplying the adjacent sides of little, ring, middle and index fingers. The fifth branch divided to supply the adjacent borders of index finger and thumb. The lateral-most branch supplied lateral side of thumb. The lateral two branches did not join with any other artery. The radial artery, on the other hand, did not give rise to arteriaprincepspollicis and the arteriarradialisindicis branches. The arterial pattern of the superior extremity were otherwise normal.

2) The second anomalous pattern of superficial palmer arch was also observed in a middle-aged male cadaver (Figure 2). The medial end of the superficial arch was formed by the superficial terminal branch of ulnar artery as usual. But, on the radial side, the arch was not completed by joining with any branches from the radial artery. Instead, it was terminated by forming the inter-digital artery for the web space between middle and index finger. As the ulnar artery is not anastomosing with any branch from radial artery, the superficial arch in this case can be designated as incomplete variety.

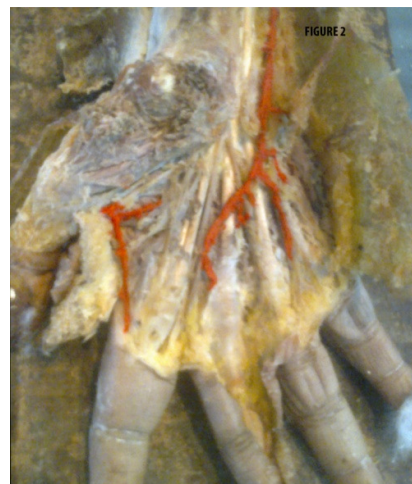Four palmer digital arteries arose from the convexity of the arch. The most medial one supplied the ulnar side of the little finger. The remaining three branches formed common digital arteries that proceeded towards the web and joined with palmer metacarpal arteries from the deep arch. Each artery then divided into two proper palmer digital arteries to supply the adjacent fingers. The most lateral pair of palmer digital arteries are the terminal branches of the arch on the radial side. The arteriaprincepspollicis and arteriaradialisindicis were arising from the radial artery as usual and supplied the thumb and index finger. The anomaly was bilateral. The vasculature of the superior extremity of the subject was otherwise normal.



3) The third case was a 65 year old female cadaver showing bilateral anomalous pattern of superficial palmer arch. The arch was an incomplete one, formed only by superficial branch of ulnar artery (Figure 3). But, from the convexity of the arch arose five palmer digital arteries. The most medial one supplies the ulnar side of the little finger. The remaining four branches formed common digital arteries that proceeded towards the web and joined with palmer metacarpal arteries from the deep arch. Each artery then divides into two proper palmer digital arteries to supply the adjacent fingers. The web between thumb and index was also supplied by the superficial arch. Branches of the radial artery, i.e. arteriaprincepspollicis and arteriaradialisindicis were absent.



All the other palms dissected had shown usual formation of superficial arch.



### Discussion:

Apart from the three pairs of variant arches, rest of the seventeen pairs of superficial palmer arches were as usual. The first variant case of the present series was of complete type of superficial palmer arch (Group I, Type A of Coleman & Anson, 1961)<sup>4</sup>. Ikeda et al<sup>7</sup> reported the incidence of this type of arch in 55.9% of the 220 cadaveric hands they studied. The radial artery while entering the palm from the dorsum gives the arteriaprincepspollici and arteriadiradialisindici branches<sup>1</sup>. But, in the present case typical arteriadiradialisindici and arteriaprincepspollici were absent. Instead, a proper palmer digital branch of superficial palmer arch supplied the radial side of the thumb and a common palmer digital branch of the superficial palmer arch supplied the adjacent sides of the thumb and index finger. Loukas et al<sup>8</sup> reported a similar case of termination of superficial palmar arterial arch by giving rise to a common trunk for the princepspollici and radialisindici arteries.

In the second anomalous case of present series, the arch is not complete because it has not joined any radial arterial branch. This arch can be classified as Group II or incomplete variety according to Coleman & Anson's classification of superficial palmer arch<sup>4</sup>. Adachi described this type of arch as Type A: Ulnar type-- in which contribution from radial artery is absent or minimal<sup>9</sup>. Huber classified this type of arch as Type 2 where there is no true arch and the participating arteries failed to anastomose and giving rise independently to the digital branches<sup>10</sup>.

The third variation of the present series was an incomplete arch, formed only by superficial branch of ulnar artery. The web between thumb and index was also supplied by the superficial arch and therefore by ulnar artery. Branches of the radial

artery, i.e. arteriaprincepspollici and arteriadiradialisindici were absent. Coleman and Anson<sup>4</sup> found that 34% of superficial palmer arches were contributed solely by ulnar artery.

They stated that the nomenclature of arteries originating from superficial palmer arch and supplying thumb and index needs to be discussed because of their surgical importance. According to Suman and Jayanthi, superficial arch completed only by ulnar artery cannot be designated as variation, since 50% specimens of their series of 60 hands were of this type<sup>13</sup>.

### Clinical significance:

The knowledge of exact pattern of vasculature of hand is essential for performing superficial dissection, proper interpretation and performance of diagnostic angiography and most importantly, therapeutic surgery in case of ischemic changes in digits and orthopaedic surgeries on hand. In case of incomplete palmer arch, both ulnar and radial arteries will behave as end arteries. So, any procedure on radial and ulnar arteries should be planned carefully, and any ischemic complications of the digits must be kept in mind. It is mandatory to conduct the investigations like Allen's test, angiography and colour Doppler studies of the hand before undertaking any invasive procedures including the vascular surgeries.

As Ruengsakulrachet al<sup>14</sup> suggested, awareness about variation in collateral circulation, like the occurrence of an incomplete superficial palmer arch, becomes necessary while harvesting the radial artery for arterial by-pass channels or while harvesting the free Radial Forearm Flap. Rao et al (2010),<sup>15</sup> commented that if superficial palmer arch is contributed only by ulnar artery having no communication with radial or other arteries like persistent median artery, manifestations of claudication, rest pain or gangrene may develop in

case of occlusion of ulnar artery since there will not be collateral blood flow.

#### **Embryological explanation**

Arey (1957)<sup>16</sup> opined that the anomalies of blood vessels develop because of:

1. Unusual pathway of primitive vessels.
2. Persistence of vessels normally obliterated.
3. Disappearance of vessels normally retained.
4. Incomplete development.
5. Fusion and absorption of distinctive parts.

Senior<sup>17</sup> commented that when the embryo is 18mm in length, ulnar artery joins with median artery forming superficial palmar arch. This arch gives rise to the digital branches. Later on, superficial brachial artery appears and reaches posterior aspect of the wrist dividing into branches for thumb and index finger. In 23 mm embryo, superficial brachial artery becomes radial artery and establishes communication with the superficial palmar arch.

In the first case of our series, superficial palmar arch, though normally developed, gave rise to six digital branches. The digital branches of the superficial brachial artery failed to develop or regressed. All the primitive branches of superficial palmar arch were retained. As a result, the arteries supplying the thumb and index finger arose from

the superficial palmar arch. Arteriaprincepspollicis and arteriaradialisindidis did not have typical presentation.

In the second and third cases, the anomaly of the palmar arch can be explained by either disappearance of a segment of ulnar superficial branch originally joining with radial artery or incomplete development of one segment of ulnar artery. The portion of radial artery, interconnecting with the ulnar arterial branch may have undergone the same fate of disappearance or incomplete development. Thus, the ulnar arterial system failed to anastomose with radial arterial system.

#### **Conclusion**

With high rate of road traffic accidents in today's world, and increasing needs of surgical reconstruction procedures of hand and vascular graft application, the knowledge of anatomical variation of superficial palmar arch has become essential. So, continuous reporting of such variations is needed to keep the clinicians aware of them and avoid potential problems posed by them. Knowledge of variations is essential for verifying the validity of various surgical and radiological procedures under practice and to define new ones.

#### **References**

- 1) Standring S. Grey's Anatomy (39 eds). In: Wrist and hand. Elsevier Churchill Livingstone. Edition London UK, (2005); PP 925-929.
- 2) Gajisin S, Zbrodowski A. Local vascular contribution of the superficial palmar arch. Acta Anat (Basel) 1993; 147: 248-251.
- 3) Moore KL, Dalley AF. Clinically Oriented Anatomy. 10th ed. Philadelphia: Lippincott, Williams and Wilkins; 1999. p. 751
- 4) Coleman S, Anson J. (1961): Arterial pattern in hand- based upon a study of 650 specimens. Surgery. Gynaecology. Obstetrics. [113 (4)]:pp. 409-24.
- 5) Erbil M, Aktekin M, Denk CC, Onderoglu S, Sürücü HS. Arteries of the thumb originating from the superficial palmar arch: five cases. SurgRadiol Anat. 1999; 21(3):217-20.

- 6) Valentin N. and Veras W. R. Variation on the Formation of Superficial Palmar Arch. A cadaveric Study. The FASEB Journal. 2011;25:866-15.
- 7) Ikeda A, Ugawa A, Kazihara Y, Hamada N. Arterial patterns in the hand based on a three-dimensional analysis of 220 cadaver hands. J Hand Surg 1988; 13: 501-509.
- 8) Loukas M, Tubbs S, Louis R G, Apaydin N. Princepspollicis artery arising from the superficial palmar arch. Singapore medical journal. 2009; 50(11):e391-2
- 9) Adachi B. (1928) Das Arterien System des Japaner, 365, 368, 389.
- 10) Huber G. C.(1930) Piersol's Human Anatomy, 9th ed., I, J.B. Lippincot Co. Philadelphia, 785-91.
- 11) Mookambica R.V., Nair V., Nair N., Somayaji S.N., Pamidi N., Vollala V.R. Incomplete superficial palmar arch. International Journal of Anatomical Variations 2010; 3:65-66.
- 12) Gellman H., Botte M.J., Shankwiler J., Gelberman R.H. Arterial patterns of the deep and superficial palmar arches. ClinOrthop and Related Research 2001; 383: 41-46.
- 13) Suman.U.,K.S.Jayanthi, A Study of Complete Superficial Palmar Arches formed entirely by Ulnar Artery. J Anat. Soc. India. 2011; 60(2): 199-201.
- 14) Ruengsakulrach P, Eizenberg N, Fahrer C, Fahrer M, Buxton BF. Surgical implications of variations in hand collateral circulation: anatomy revisited. J ThoracCardiovasc Surg. 2001 Oct;122 (4):682-6.
- 15) Rao S, Vollala VR, Pamidi N, Nagabhooshana S, Potu BK. Variant formation and distribution of the superficial palmar arch. Indian J PlastSurg 2010;43:116-7.
- 16) Arey: Developmental anatomy. In: Development of the arteries. 6th Ed. W.b. Saunders Co., Philadelphia : pp. 375-377 ( 1957).
- 17) Senior, H. D. (1926): A note on development of radial artery. Anatomical Record., (32): p. 220.