

Case Report:

Gastric malignancy presenting as extensive osteolytic lesions

Dr. Feroz Jenner.P , Dr. Jemshad.A, Dr. Mansoor.C.Abdulla, Dr. Mohammed Salih. P

¹Associate Professor, Department of General Medicine , M.E.S. Medical College , Malaparamba, Kerala

²Assistant Professor, Department of General Medicine, M.E.S. Medical Colleg, Malaparamba, Kerala

³Associate Professor, Department of General Medicine, M.E.S. Medical College, Malaparamba, Kerala

⁴Senior resident , Department of General Medicine, M.E.S. Medical College , Malaparamba, Kerala

Corresponding Author: Dr Jemshad. A

Abstract

Gastric malignancy presenting as low backache due to bone metastasis from the primary is rare. We report a case of 51 year old male presented with low back ache from extensive metastases to the spine, which on evaluation originated from adenocarcinoma of the stomach. Magnetic resonance imaging of the spine showed osteolytic metastases in vertebral body in the whole of the spine and pelvic girdle. Gastrointestinal endoscopy revealed ulcerative growth in the stomach that on biopsy showed poorly differentiated adenocarcinoma. This case is reported since the initial presentation of gastric cancer was bony metastases without any features of primary malignancy which causes diagnostic dilemma.

Key words : Gastric malignancy, osteolytic lesions, adenocarcinoma.

Introduction

Bony metastases are common in cancers of the lung, breast and prostate. Secondaries to bone from gastric cancer is very rare and have been reported infrequently in literature.⁽¹⁾Asymptomatic gastric cancer with an initial presentation as bony metastases is even rarer.⁽²⁾ Haematogenous dissemination to the vertebrae is thought to occur through lymphatic channels and Batsons plexus . We report a case of gastric carcinoma presenting as symptomatic bone metastases without symptoms of underlying malignancy.

Case report

A 51 year old male presented with low grade intermittent fever and low back ache of one month. He also had significant weight loss of 20 kg in the last two months. He was pale, vitals were stable and had tenderness over lower back and left posterior iliac crest. Rest of the examination was normal.

His hemoglobin was 9.1 gm%(microcytic hypochromic), total leucocyte count 10100 cells/c.mm, platelet count 2.6 Lakhs/c.mm and erythrocyte sedimentation rate 78mm/1st hr. Liver function test showed moderately elevated alkaline phosphatase and albumin-globulin ratio reversal. Renal function tests, serum electrolytes, urinalysis were all normal. Chest radiograph was normal. Radiograph of Skull showed osteolytic lesion (Figure1A). USG abdomen showed mild hepatomegaly with fatty change. MRI spine showed patchy altered marrow signal throughout the vertebral body in the whole of the spine and pelvic girdle which was hypointense on T1 and hyperintense on Inversion Recovery (Figure 1B). Bone marrow examination and serum protein electrophoresis done to rule out plasma cell disorder were normal. His serum prostate-specific antigen and ultasonography thyroid were normal. Since his stool occult blood was

positive and had microcytic hypochromic anemia, an upper gastrointestinal endoscopy was done which showed ulceronodular lesion in the lesser curvature of stomach. Histopathology of the lesion showed poorly differentiated adenocarcinoma (Figure 2). He was given palliative chemotherapy with oxaliplatin and epirubicin and is under follow up.

Discussion

Gastric cancer is the fourth most common cancer worldwide in men and the fifth in women.⁽³⁾ The common manifestations include epigastric pain, early satiety, vomiting and constitutional symptoms. Cancers of the prostate, breast and lung are commonly associated with bone metastasis, however metastasis to bone is quite rare in gastric cancer.⁽¹⁾ Bone metastasis as the initial manifestation of carcinoma stomach is even rarer.⁽²⁾ Mohandas et al. reported four cases of gastric cancer that presented with bone pain as the initial symptom.⁽⁴⁾ Further evaluation of these cases revealed poorly differentiated adenocarcinoma of stomach.

The most frequent site for distant spread in gastric carcinoma is the liver.⁽⁵⁾ However, poorly differentiated adenocarcinomas spread less often to the liver and tend to involve the bones more frequently.⁽¹⁾ The location of the primary tumour has also been implicated in development of bone metastasis. Cancers of the body of stomach and those with extensive local lymph node involvement are more likely to spread to the bones.⁽¹⁾ It is interesting to note that carcinoma of the stomach with bone metastasis do not have liver involvement, as in our patient. However, in such cases lymph node involvement seems very common. When bone metastasis occurs in carcinoma of the stomach, they are often osteolytic and less commonly mixed osteolytic-osteosclerotic. In this case there was no

involvement of liver which points to a non portal spread of the tumor probably via Batsons plexus.⁽⁶⁾

Our patient had osteolytic lesion in the skull, which was not reported previously.

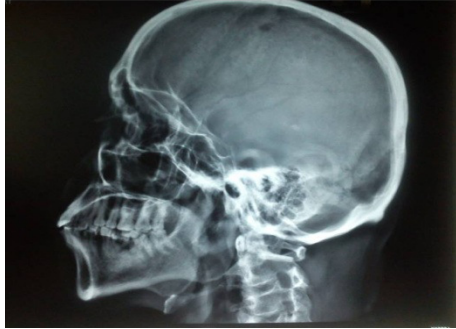Kusumoto et al. described nine gastric cancer patients with bone metastasis and all of them had elevated serum alkaline phosphatase levels.⁽⁵⁾ They concluded that an elevated alkaline phosphatase in a patient with gastric cancer may indicate bone metastasis and should prompt a detailed search for the same. In a Korean study, the most frequent site of bone metastasis was the vertebrae (89%), ribs (63%), scapula (10%), lower extremities (10%) and upper extremities (5%).⁽¹⁾ The identification of bone metastasis in carcinoma stomach has prognostic utility. In the above mentioned study, the median time to death from time of detection of bone metastasis was three months.⁽¹⁾ Kamiyo T et al⁽⁷⁾ found patients with bone metastases in gastric cancer have a poor survival rate of 2.5 to 5 months. Hence, presence of bone metastasis in patients with stomach cancers portends imminent death.

Extensive bony metastases being the presentation of gastric cancer, without features of the underlying primary makes the diagnosis difficult in this case. Presence of osteolytic skull lesions also makes the case distinct. So evaluation of patients with osteolytic bony metastasis may include tests for detecting carcinoma of stomach also.

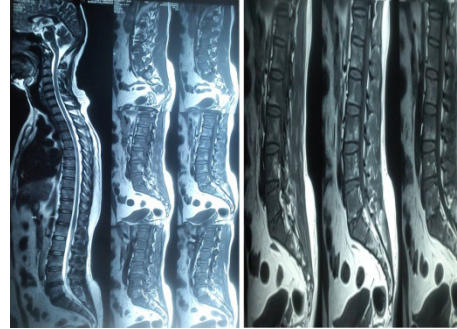
Medworld asia

Dedicated for quality research

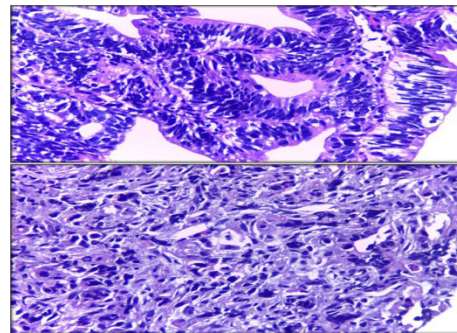
www.medworldasia.com



Radiograph of lateral view of Skull showing osteolytic lesions.



MRI spine showing patchy altered marrow signal throughout the vertebral body in the whole of the spine and pelvic girdle .



Photomicrograph showing poorly differentiated adenocarcinoma of stomach (haematoxylin and eosin stain: 100x)

References

1. Ahn JB, Ha TK, Kwon SJ. Bone metastasis in gastric cancer patients. *J Gastric Cancer*. 2011; 11:38–45.
2. Nottebaert M, Exner GU, von Hochstetter AR, Schreiber A. Metastatic bone disease from occult carcinoma: a profile. *Int Orthop*. 1989;13:119–23.
3. Jemal A, Bray F, Center MM, Ferlay J, Ward E, Forman D. Global cancer statistics. *CA Cancer J Clin* 2011; 61: 69–90.
4. Mohandas KM, Swaroop VS, Krishnamurthy S, Desai DC, Dhir V, Pradhan SA, *et al* . Unusual bone metastasis as the initial symptom of gastric cancer--a report of four cases. *Indian J Cancer*. 1993; 30:146-50.
5. Kusumoto H, Haraguchi M, Nozuka Y, Oda Y, Tsuneyoshi M, Iguchi H. Characteristic features of disseminated carcinomatosis of the bone marrow due to gastric cancer: the pathogenesis of bone destruction. *Oncol Rep*. 2006;16:735–740.
6. Sagara K, Fujiyama S, Kin F, Sato T. An unusual case of Gastric carcinoma initially presenting bone metastasis and later transverse myelopathy. *Jpn J Clin Oncol*. 1985 ; 15:133-4.

7. Kamiyo T, Honda K, Kizaki M, Maruyama T, Masuda T, Suzuki O, et al. Clinicopathological studies on disseminated carcinomatosis of the bone marrow occurring through metastasis of gastric carcinoma. Gan No Rinsho. 1985;31: 819-26.