

Case report :

Left sided Hemorrhagic Pleural effusion due to Acute Pancreatitis and a Pseudocyst

¹Phani Harshitha Yarlagadda , ²Karthik Adiraju , ³ Anish Reddy

¹MBBS, Intern , Kamineni Institute of Medical Sciences , Hyderabad, Telangana

^{2,3} MBBS, Kamineni Institute of Medical Sciences , Hyderabad, Telangana

Corresponding author: Phani Harshitha Yarlagadda

Abstract:

A 42 year old male presented to emergency department with shortness of breath and chest pain radiating to back which relieved on lying down. On examination he was tachypneic, cachexic and pale. Chest Xray showed left side pleural effusion with subsegmental collapse of left lower lobe. CT abdomen showed calcifications in head of pancreas and a pseudocyst near to body of pancreas along with septate collections in lesser sac communicating with left pleural effusion. Pleural fluid analysis showed hemorrhagic fluid with significant amylase (21,320 IU/dl) in it. Thoracocentesis was done twice for fluid aspiration and treated symptomatically. On surgical consultation a Cystogastrostomy was done and was discharged on stable condition.

Keywords: Hemorrhagic pleural effusion, Pancreatitis, Pseudocyst, Amylase, Cystogastrostomy

Introduction:

According to World Journal of Gastroenterology, up to 20 percent of patients with acute pancreatitis develop pleural effusions. Most pleural effusions are left-sided, but effusions sometimes may involve only the right lung or both lungs. These are mostly commonly observed in men than women around 50-60 years of age with chronic alcoholism. Because pancreas lies just beneath diaphragm, swelling of the pancreas may block the drainage of lymph on the upper side of diaphragm. As the lymph collects at the base of lung, an effusion forms. Alternatively, acute pancreatitis may damage pancreatic ducts and allow leakage of pancreatic enzymes into the surrounding tissues. If the enzymes percolate through diaphragm, they can injure lungs and generate a pleural effusion. At times perforation of pseudocyst, a fistula or open tract, forms between the pancreas

and the thoracic cavity, permitting the free flow of pancreatic enzymes into the area surrounding the lungs. We present this case to report moderate left hemorrhagic pleural effusion due to pancreatitis and a pseudocyst in a non alcoholic patient.

Case Presentation:

A 42-year-old male, from a village in Nalgonda district, Andhra Pradesh, developed chest pain which was gradual in onset, dull type, radiating to back, aggravated on deep breath and relieved on lying down in left lateral position and shortness of breath insidious in onset, gradually progressive from grade-1 to grade-2 since 15 days and is associated with loss of appetite and loss of weight. He is a known case of bronchial asthma since childhood. On examination decreased chest movements, tactile vocal fremitus on left side, shifting of trachea to right side and stony dullness on left side of chest were noted. The patient

had no history of drug and alcohol intake or abdominal trauma.

Chest X-ray showed moderate left-sided pleural effusion(fig1) which was thought to be due to either smoking or chronic tuberculosis. Thoracentesis revealed a dark red bloody effusion with pleural fluid analysis showing markedly elevated amylase: 21,320IU/dl (serum amylase: 2655 U/L), protein: 4 mg/dL, cell count: 10,000 cells/mm³ with 80% neutrophils. Acid fast staining of pleural fluid was negative three times. The results of pleural biopsy and pleural fluid culture for Tuberculosis were negative as well.

Important peripheral blood laboratory values were as follows: hemoglobin: 11.7 g/dL; white blood cell count: 12,500/mm³; platelet count:2,50,000 /mm³; fasting blood sugar: 96 mg/dL; serum glutamic-oxaloacetictransferase (SGOT):36U/L; serum glutamic-pyruvic transaminase (SGPT): 29 U/L; alkaline phosphatase: 133 U/L; total bilirubin: 0.48 mg/dL; direct bilirubin: 0.15 mg/dL;blood urea:44mg%;serum creatinine:1.4mg%;serum sodium:137meq/L;serum potassium:4.1meq/L;serum chlorine:105meq/L;bleeding time:2 sec;clotting time:4 sec; prothrombin time: 13_ (control: 13_); partial thromboplastin time: 50_ (control: 35–45_); total calcium: 9.2 mg/d; triglyceride: 89 mg/dL (nl: 60–160 mg/dL); erythrocyte sedimentation rate (Westergen): 35 mm/hr; serum C-reactive protein: 12 mg/L (nl: <8 mg/L); serum fibrinogen: 215 mg/dL (nl: 200–400 mg/dL); fibrin split products: 9 ∞g/mL (nl: <10 ∞g/mL). Electro cardiogram (ECG) was normal. The patient was tested for HIV and was found non reactive.Pleural fluid cytology (three times) was found negative.

Abdominal ultrasonography revealed a small septated cystic structure adjacent to the body of the pancreas

which was edematous and suggestive of pseudocyst of acute pancreatitis. Hepatobiliary tract and gall bladder were devoid of any gall bladder lesions, including stones.

CT scan of chest and abdomen are done showing pleural effusion on left side (fig2) ,necrosed areas in pancreas with pancreatitis (fig3) a cystic structure adjacent to the body of pancreas, highly suggestive of a pancreatic pseudocyst(fig4)and presence of mesenteric collaterals can also be seen (fig5).

Management:

- Diet without fat & high protein intake is given .
- Drugs Used :CEFTUM.(cephalosporin)- 200mgBD ,DECORIL.(Mucolytic)- 2tsp-TID.SYP,OMITEX 2tsp-TID
- CAP. ZPES - OD,PROTINEX - 2tsp-TID.
- Diagnostic & therapeutic thoracentesis was done twice.1200ml &900ml hemorrhagic fluid is aspirated. In view of chronic pancreatitis, Gen Medicine & Gen Surgery consultation is awaited and “cystogastrostomy” is the surgery to be performed.

Discussion:

The incidence of pleural effusion with acute pancreatitis in older reports was about 3-7% , but it is nearing 50% in recent reports based on pleural fluid detection by CT[2] . The pleural effusion in chronic pancreatitis though uncommon, does occur, but is often missed because of lack of abdominal symptoms.

The Pleural effusion was secondary to pancreatitis was confirmed by estimation of pleural fluid amylase levels (which were markedly elevated) and serum amylase levels (which were only mildly

raised). The only other two conditions which can lead to raised pleural fluid amylase levels like malignant tumor and oesophageal rupture [3] were excluded by carrying out detailed investigations like UGI endoscopy, abdominal ultrasonography, CT of thorax and by pleural fluid cytology. Investigations like ERCP could not be carried out as patient refused due to financial constrains. Most patients of chronic pancreatic pleural effusion are men and fluid is usually left-sided. The pleural effusion is usually large, some times occupying the entire hemithorax. In 20% cases the fluid can be right sided and in 15% bilateral [4] .

The accumulation of amylase rich pleural fluid may be due to transfer of pancreatic secretions through transdiaphragmatic lymphatics [1] ,diaphragmatic perforation of a pseudocyst or a medistinal extension. In most cases, a pancreaticopleural fistula can be demonstrated either by ERCP or by CT.

Because chest symptoms dominate the clinical picture and often patients have no history of prior pancreatic disease, the diagnosis is easily missed. The best screening test for chronic pancreatic pleural effusion is the measurement of pleural fluid amylase (which is markedly elevated, usually over 1000 U per Liter), where as the serum amylase may be normal or mildly elevated [5] . CT chest as well as abdomen and ERCP are required for confirmation of diagnosis and for planning surgery.

Pancreatic disease is not readily recognized as a cause of pleural effusion. Since the underlying pancreatic disease is commonly asymptomatic, it is suggested that the pleural fluid amylase content should be measured in any case of recurrent exudative pleural effusion of unknown aetiology.

Treatment with drainage by a chest tube, with concomitant conservative treatment of the pancreatitis, is usually effective in massive pancreatic pleural effusions. If drainage by a chest tube fails, percutaneous catheter drainage of the abdominal pseudocyst can be considered for treatment or Gastrocystotomy can be done for pseudocyst as done in this case.

Conclusion:

Pancreatitis should be taken into consideration when hemorrhagic pleural effusion occurs, especially when it occurs concomitant with elevated amylase level of pleural fluid. In such a condition visual methods such as CT scan, ultrasonography and ERCP are so helpful. Treatment with drainage by a chest tube, with concomitant conservative treatment of the pancreatitis, is usually effective in massive pancreatic pleural effusions and Gastrocystotomy for pancreatic pseudocyst.

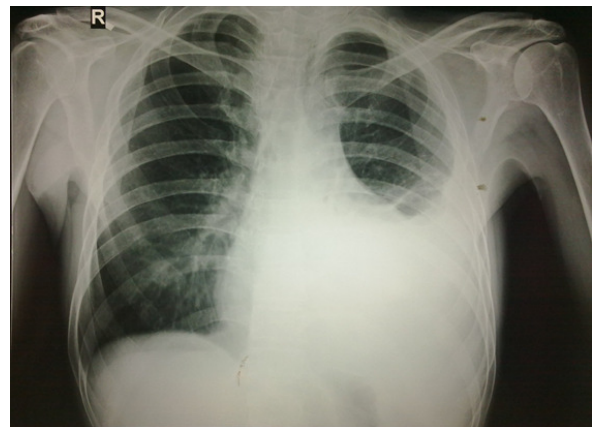


fig 1 X ray chest showing Left pleural effusion and sub segmental collapse of left lower lobe

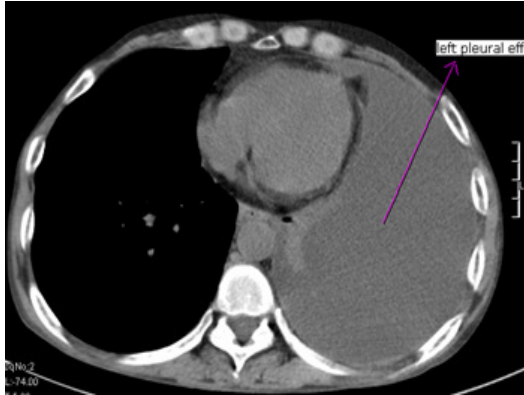


fig 2 showing Chest CT with Left sided pleural effusion.

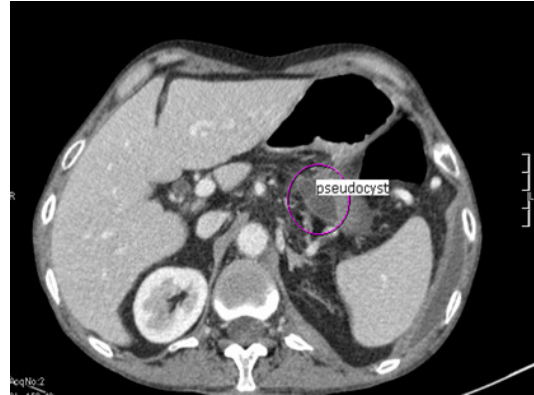

fig 4 showing Pseudocyst near body of pancreas

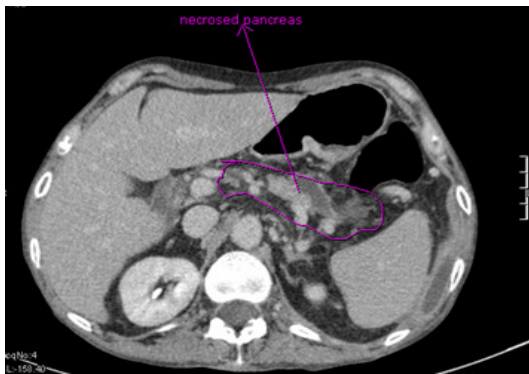


fig 3 acute pancreatitis with necrosis

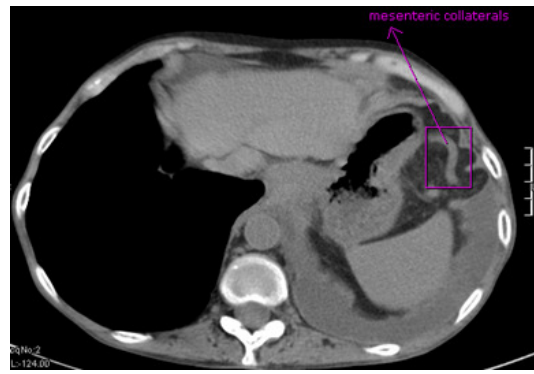


fig 5 showing mesenteric collaterals

References:

- 1) Raghu MB, Balasubraminian S, Balasubramanyam G. Hemorrhagic pleural effusion: sole manifestation of pancreatitis. *Indian J Pediatr.* 1992;59:767–769.
- 2) Ramsdell CM, Muslow I. Recurrent hemorrhagic pleural effusion associated with relapsing pancreatitis. *South Med J.* 1973;66:1016–1018.
- 3) Gupta D, Chakraborty KL, Gomber S, et al. Massive pancreatico-pleural effusion-an often unrecognized entity. *Indian J Pediatr.* 2001;68:883–5.
- 4) Imai Y, Taniguchi M, Tagawa K, et al. A case of chronic pancreatitis complicated by massive pericardial and right pleural effusion. *Gastroenterol Jpn.* 1993;28:734–8.
- 5) Siwczynski H. Chronic pleural effusion from the pancreas. *Wiad Lek.* 1998;51:190–5.
- 6) Thandroyen FT, Samson RE, Keeton GR. Hemorrhagic right pleural effusion complicating acute-on-chronic pancreatitis. *S Afr Med J.* 1984;65:933–934.
- 7) Dewan NA, Kinney WW, O'Donohue WJ., Jr Chronic massive pancreatic pleural effusion. *Chest.* 1984;85:497–501.
- 8) Uchiyama T, Suzuki T, Adachi A, et al. Pancreatic pleural effusion: case report and review of 113 cases in Japan. *Am J Gastroenterol.* 1992;87:387–91.

- 9) Abisheganaden J, Sin Fai Lam KN, Chew LS. Massive pleural effusion in pancreatitis: 2 case reports. Singapore Med J. 1995;36:487–90.
- 10) Gumaste V, Singh V, Dave P. Significance of pleural effusion in patients with acute pancreatitis. Am J Gastroenterol. 1992;87:871–4.
- 11) Girbes ARJ, Postmus PE, Jansen W, et al. An alcoholic with pleural effusion. EurRespir J.1990;3:934–936.
- 12) Svane S. Recurrent, hemorrhagic pleural effusion and eosinophilia accompanying pancreatitis. ActaChir Scand. 1966;131:352–356.