

## Case report

# “Multiple neurovascular variations in the right upper limb of a single cadaver”

**<sup>1</sup>Dr. Jayeeta Burman , <sup>2</sup>Dr. Mithu Paul , <sup>3</sup>Dr. Biplab Goswami , <sup>4</sup>Dr. Gopal Chandra Mandal , <sup>5</sup>Dr. Satyajit Sangram , <sup>6</sup>Dr. Chiranjit Samanta , <sup>7</sup>Dr. Biswapriya Sinha , <sup>8</sup>Prof. (Dr.) Sudeshna Majumdar**

<sup>1</sup> Demonstrator, Department of Anatomy, Nilratan Sircar Medical College, Kolkata – 700014, West Bengal, India.

<sup>2</sup> Junior Resident, Department of Anatomy , Nilratan Sircar Medical College, Kolkata – 700014, West Bengal, India

<sup>3</sup> Assistant Professor , Department of Anatomy, Calcutta National Medical College, Kolkata - 700014, West Bengal, India.

<sup>4</sup> Assistant Professor, Department of Anatomy, Nilratan Sircar Medical College, Kolkata – 700014, West Bengal, India.

<sup>5</sup> Junior Resident, Department of Anatomy , Nilratan Sircar Medical College, Kolkata – 700014, West Bengal, India

<sup>6</sup> Junior Resident, Department of Anatomy , Nilratan Sircar Medical College, Kolkata – 700014, West Bengal, India

<sup>7</sup> Junior Resident, Department of Anatomy, Nilratan Sircar Medical College, Kolkata – 700014, West Bengal, India

<sup>8</sup> Professor, Department of Anatomy, Nilratan Sircar Medical College, Kolkata -700014, West Bengal, India.

Corresponding author: Prof. (Dr.) Sudeshna Majumdar

---

## Abstract

In September, 2014, while doing the routine dissection for undergraduate students in the department of Anatomy, NRS Medical College, Kolkata, India, few neurovascular variations were detected in the right superior extremity of a male cadaver, aged about sixty-five years. In the right upper limb, there is a single superficial vein which passed upwards from lateral to medial side to join the axillary vein. A slender and unusual branch arose from the brachial artery at the junction of the upper one – fourth and lower three - fourth of the right arm.

The median nerve trunk has been formed in the axilla and then it bifurcated. In the upper part of the right arm, the two divisions united to form the median nerve trunk again on the lateral side of the brachial artery.

This case report will contribute in the fields of gross and clinical anatomy and will help clinicians for invasive procedures or surgical approach in the arm.

**Key words:** Brachial plexus, median nerve, brachial artery, cephalic vein, basilic vein.

---

## Introduction

From normal anatomy we came to know that **the cephalic vein**, originating at the radial end of the irregular dorsal venous arch at the back of the hand, ascends in the superficial fascia on the lateral side of the biceps. On reaching the infraclavicular fossa, it drains into axillary vein<sup>1</sup>.

The origin of **the basilic vein** is the ulnar side of the dorsal venous arch, and this vein is the main venous outlet in 53% of cases<sup>1</sup>. This vein ascends in the superficial fascia along the medial aspect of the forearm and along the medial side of the biceps brachii muscle. On halfway up to the arm, it pierces the deep fascia and joins with the venae comitantes of

the brachial artery to form the axillary vein at the lower border of the teres major<sup>2</sup>.

**The axillary artery**, a continuation of the subclavian artery, begins at the outer border of the first rib and ends normally at the inferior border of the teres major where it becomes the brachial artery. **The brachial artery**, a continuation of the axillary artery, begins at the distal border of the teres major and ends about 1cm. distal to the elbow joint dividing into radial and ulnar arteries<sup>2</sup>.

**The median nerve** has two roots (lateral and medial) arising from the lateral cord (C5, 6,7) and the medial cord (C8,T1) of brachial plexus respectively, which unite in the axilla antero-lateral to the third part of the axillary artery [3]. The median nerve enters the arm at first lateral to the brachial artery and near the insertion of the coracobrachialis crosses in front of the artery to descend medially to the cubital fossa<sup>2,3</sup>.

The aim of the case report was to know about the variations of these structures concerned to prevent serious complications during surgical interventions.

#### **Materials and methods**

While doing the routine dissection for the undergraduate students in the Department of Anatomy, NRS Medical College, Kolkata, in September, 2014, few variations were found in the right superior extremity of a male cadaver. The subject was about sixty-five year old and the variations were present in superficial veins, brachial artery and the median nerve of the right upper limb.

Dissection was done properly in both the upper limbs of the cadaver concerned. All the structures were observed carefully and relevant photographs were taken.

#### **Observations**

In the right upper limb of the cadaver concerned there is a single superficial vein which passed upwards from lateral to medial side. The right cephalic vein started from the lateral end of the dorsal venous plexus, passed upwards across the cubital fossa from lateral to medial side to run as the basilic vein and the latter continued as the axillary vein. So the cephalic vein was absent in the right upper limb above the elbow and the basilic vein was absent below the elbow.

A slender and unusual branch arose from the brachial artery at the junction of the upper one – fourth and lower three - fourth of the right arm and it ran downwards and medially along with the basilic vein.

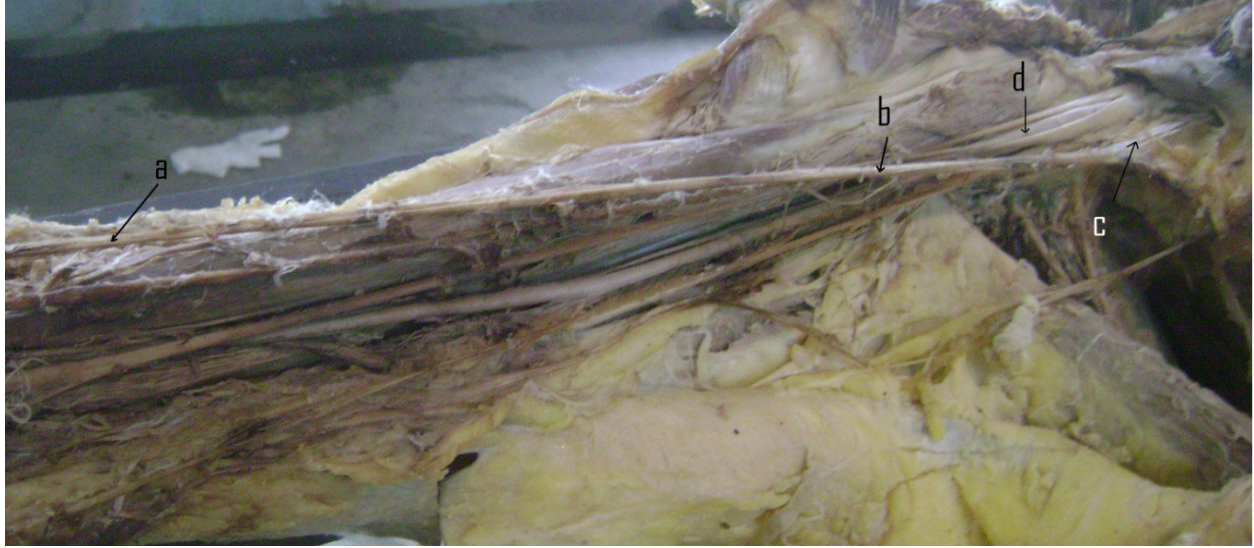
The median nerve trunk has been formed in the axilla by two roots and then it bifurcated. The two divisions embraced the lower part of the axillary artery and the upper part of the brachial artery. At the junction of the upper one –fourth and lower three- fourth of the right arm, these two divisions joined with each other to form the single median nerve trunk again on the lateral side of the brachial artery.

In the left upper limb no such neurovascular variation was found.

**Medworld asia**

**Dedicated for quality research**


**[www.medworldasia.com](http://www.medworldasia.com)**



**Figure – 1**

Single superficial vein crossing the right upper limb from the lateral to the medial side and continued as the axillary vein.

**Index:** a – cephalic vein, b – basilic vein, c – axillary vein, d- axillary artery, continued as the brachial artery.

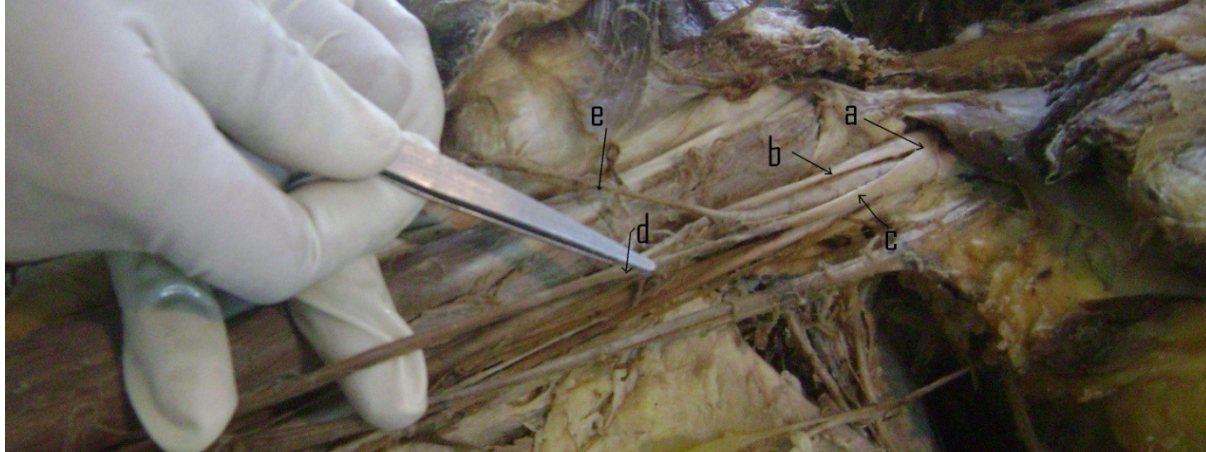


**Figure – 2**

The variant slender branch of the brachial artery arose in the upper part of the right arm.


**Index:** a - axillary artery, continued as the brachial artery, flanked by two divisions of the median nerve, b- a slender branch arising from the brachial artery, c- median nerve trunk in the axilla, d & e – two divisions of the median nerve, f - median nerve trunk formed again in the arm.





**Figure – 3**

The two divisions of the right median nerve joined in arm to form the median nerve trunk again. **Index:** **a** – median nerve trunk in the axilla, **b** & **c** – two divisions of the median nerve, **d** - median nerve trunk formed again in the arm, **e** – a slender branch arising from the brachial artery.



**Figure – 4.** The left upper limb - with usual arrangement of muscles, vessels and nerves.

**Index:** **a** – cephalic vein, **b** – basilic vein, **c** – median nerve, **d** – brachial artery.

### Discussion

The main venous return in the upper limb is by the basilic vein, with all others converging upon it. In 83% of cases, the general arrangement is two longitudinally directed veins, the cephalic and the basilic, connected by the median cubital vein. In 1% of cases, there are no connections between the cephalic and basilic veins in the vicinity of the elbow. Different studies show that there is a reciprocal relationship between the size of cephalic and basilic veins. Either one may predominate or be lacking. The delto-pectoral portion of the cephalic vein may also be small or absent. Absence of cephalic vein was found in 3% male and 1% female subjects<sup>1,4</sup>.

In 2012, Bhattacharya et al presented a case where a single superficial vein was found in the left upper limb which passed upwards from the level of the wrist joint, crossed the forearm from lateral to medial side to drain into the axillary vein on the medial side. It was the cephalic vein, originating at the radial end of the dorsal venous arch, passed proximally and medially to be continued as the basilic vein<sup>4</sup>.

The basilic vein is commonly used for venipuncture (for blood sampling and transfusion or intravenous injections), often under conditions of emergency<sup>5,6,7</sup>. Superficial segment of this vein can be used in general, vascular and endovascular surgeries, to

introduce a catheter for obtaining blood samples from cardiac chambers and for cardioangiography<sup>6,7</sup>.

Vascular surgeons also utilize the basilic vein to create an AV (arteriovenous) fistula or AV graft for hemodialysis access in patients with renal failure<sup>5</sup>. Vascular access for chronic hemodialysis has classically been initiated by the creation of a primary radial artery-to-cephalic vein arteriovenous fistula (RCAVF)<sup>8</sup>.

Sometimes a slender vasa aberrantia connect the brachial artery to the axillary artery or to one of the forearm arteries, usually the radial<sup>2</sup>. There is a similar slender artery in the right arm of the cadaver in the present case.

The knowledge of these vascular patterns concerned is necessary for coronary angiography, other invasive procedures and vascular surgery in arm<sup>9</sup>.

Gupta et al described a case where the two roots of the median nerve joined at a lower level, almost in the middle of the arm to form median nerve trunk<sup>9</sup>. They also found another case where 'figure of 8 loop' was formed around the axillary artery by the two roots of the median nerve and a nerve twig connecting the lateral root with the ulnar nerve<sup>9</sup>. Nayak et al described a case where the median nerve was formed just below the mid point of the arm, medial to the brachial artery by the two long roots<sup>10</sup>. But it is the unique finding of the present case where the two branches of the median nerve, embraced the lower part of the axillary artery and the upper part of the brachial artery, united again in the upper part of the arm to form a single median nerve trunk. The Brachial plexus is formed by the lower four

cervical ventral rami with a variable contribution from C4 and T2. In humans, the forelimb muscles develop from the mesenchyme of the paraxial mesoderm during the fifth week of intrauterine life regulated by Fox D gene<sup>11,12</sup>. Nerves supplying the limbs are joined by connecting loops of nerve fibres to form plexuses. The median nerve is formed by a combination of ventral segmental branches and the musculocutaneous nerve arises from it<sup>13</sup>. The existence of their variations may be due to altered signaling between mesenchymal cells and normal growth cones or circulatory factors at the time of gene controlled site specific formation of the cords of the brachial plexus, usually during 4th to 7th week of intrauterine life<sup>1</sup>. It is important for surgeons to be aware of possible anatomical variations of the branches of brachial plexus to avoid unexpected complications, especially in post-traumatic evaluations and exploratory interventions of the arm for peripheral nerve repair or during the performance of axillary blocks by anesthetists<sup>3,12,14</sup>.

### Conclusion

This case will enhance our knowledge in gross and clinical anatomy and will be of help to the clinicians regarding venipuncture, cardiac catheter introduction, regional nerve block and surgical approach in upper limb.

### Acknowledgement

We are grateful to all the members of the Department of Anatomy, Nilratan Sircar Medical College, Kolkata, for their cordial help regarding this case report.

### References

1. Bergman RA, Afifi AK, Miyauchi R. Illustrated Encyclopedia of Human Anatomic Variation: Opus II: Cardiovascular System: Veins: Upper Limb.

<http://www.anatomyatlases.org/AnatomicVariants/Cardiovascular/Text/Veins/UpperLimb.shtml> (accessed in December, 2014).

2. Standing S, Johnson D, Collins P, Healy JC, Lee J (editors). In: 'Gray's Anatomy, The Anatomical Basis of Clinical Practice'. Pectoral Girdle and Upper Limb: Overview and Surface Anatomy; Pectoral Girdle, Shoulder Region and Axilla; Upper Arm. 40th Edition. Spain, Churchill Livingstone Elsevier. 2008; 780-81, 815, 821-822,828-830.
3. Ibrahim CH, Erden A, Denk CC. Variation between Median and Musculocutaneous nerves. In Internet Journal of Surgery. 2005; Volume 6, Number-1.
4. Bhattacharya S, Majumdar S, Chatterjee A, Mazumdar A. Multiple Neurovascular Variations in a single Cadaver. International Journal of Anatomical Variations (2012)5:81-84.
5. WIKIPEDIA, The Free Encyclopedia, Downloaded from [http://en.wikipedia.org/wiki/Median\\_cubital\\_vein](http://en.wikipedia.org/wiki/Median_cubital_vein). Accessed in December, 2014.
6. Dharap AS, Shaharuddin MY. Patterns of Superficial Veins of the Cubital Fossa in Malays. Med J Malaysia; Vol 49 No 3 Sept 1994; 239-241.
7. José Carlos Costa, Baptista-Silva, André Lourenço Dias, Serafim Vincenzo Cricenti, Emil Burihan. Anatomy of the basilic vein in the arm and its importance for Surgery. Braz. J. morphol. Sci. 2003; 20(3): 171-175.
8. Brescia MJ, Cimino JE, Appel K, Hurwich BJ. Chronic hemodialysis using venipuncture and a surgically created arteriovenous fistula. N. Engl. J. Med. 1966; 275: 1089-1092.
9. Gupta I, Majumdar S, Mondal S, Bandopadhyay M, Ghosh S. Variations in the Branches of the Brachial Plexus along with a Vascular Anomaly. The Indian Journal of Physiology and Allied Sciences, 2012; Vol-66 (1): 28-38.
10. Nayak S, Samuel VP, Somayaji N. Concurrent Variations of Median Nerve, musculocutaneous nerve and biceps brachii muscle; Neuroanatomy, 2006;5:30-32.
11. Gupta C, D'Souza AS, Shetty P, Vidya P, Arunashri. A morphological study to note the anatomical variations in the branching pattern of the lateral cord of the brachial plexus. Journal of Morphological Science, 2011; 28(3): 161-164.
12. Srimani P, Meyur R, De Bose A, Sadhu A. Unilateral variations in the branches of brachial plexus supplying anterior compartment of arm. International Journal of Anatomical Variations; 2014; 7:112-114.
13. Patel SJ, Patel RK, Bhatt C, Mehta CD. Variation of musculocutaneous nerve in arm with additional muscular slip in forearm. International Journal of Anatomy and Physiology. March, 2013. Vol. 2 (3):20 - 22.. **1**
14. Ray A, Bhattacharya S, Dutta S, Mandal L, Majumdar S. An evaluation of the system of classifications of the median and musculocutaneous nerves: A study in West Bengal population. Indian Journal of Basic & Applied Medical Research; September 2013: Issue-8, Vol.-2, P. 841-853.