

Nephrotic Range Proteinuria Due to Everolimus in a Renal Transplant Recipient

Bir Renal Transplant Hastasında Everolimusa Bağlı Nefrotik Düzeyde Proteinüri

Garip ŞAHİN¹, N. Şule YAŞAR², Evrim ÇİFTÇİ³, Ahmet Uğur YALÇIN¹, Haluk KİPER⁴

¹ Osmangazi University, Medical Faculty, Department of Nephrology, Eskişehir, Turkey

² Osmangazi University, Medical Faculty of Internal Medicine, Eskişehir, Türkiye

³ Osmangazi University, Medical Faculty of Pathology, Eskişehir, Türkiye

⁴ Osmangazi University, Medical Faculty of General Surgery, Eskişehir, Türkiye

Correspondence Address: Garip ŞAHİN
Osmangazi University, Medical Faculty,
Department of Nephrology,
Eskişehir, Turkey
Phone : +90 222 2399187
Fax : +90 222 2393774
E-mail : gsahin@ogu.edu.tr
garipsahin@superonline.com

Received: 28.04.2009, Accepted: 21.08.2009

ABSTRACT

Survival of transplant recipients strongly depends on the success of the immunosuppressive regimen. Many immunosuppressive drugs such as calcineurin inhibitors (CNIs) and purine biosynthesis inhibitors (mycophenolic acids) are used after renal transplantation. Everolimus is a new agent which is a proliferation signal inhibitor (PSI)/mammalian target of rapamycin inhibitor that is structurally similar to sirolimus. Everolimus has adverse effects associated with dose-related class actions including proteinuria. Proteinuria due to sirolimus has been reported previously but there are only a few publications about everolimus. Here, we report a case with severe proteinuria due to everolimus which developed three months after transplantation.

KEYWORDS: Everolimus, Proteinuria, Renal Transplantation, Proliferation signal inhibitor (PSI)

ÖZ

Transplant hastalarının yaşam süresinde immünespresif ajan seçimi büyük önem taşır. Kalsinörin inhibitörü ve pürin biyosentez inhibitörü gibi bir çok immünespresif ilaç renal transplantasyon sonrasında kullanılır. Everolimus bu amaçla kullanılan yeni bir ajandır. Everolimus sirolimus gibi proliferasyon sinyal inhibitörüdür. Doza bağlı olarak spesifik yan etkileri vardır. Bunlardan bir tanesi de proteinürüdür. Literatürde proliferasyon sinyal inhibitörü olarak etki gösteren sirolimus ile ilgili nefrotik düzeyde proteinüri geliştiğini gösteren raporlar olduğu bilinmektedir. Ancak aynı etki mekanizmasına sahip ve yeni jenerasyon bir immünespresif ajan olan everolimus ile ilgili proteinüri geliştiğini gösteren bilgi nadirdir.

Biz bu yazıda transplantasyondan 3 ay sonra everolimusa bağlı şiddetli proteinüri gelişen vakayı sunuyoruz.

ANAHTAR SÖZCÜKLER: Everolimus, Proteinüri, Renal transplantasyon, Proliferasyon sinyal inhibitörü

INTRODUCTION

Renal transplantation is an alternative treatment modality in end-stage renal disease. Survival of transplant recipients has greatly improved over the years with new immunosuppressive agents (1). The aim of the immunosuppressive therapy is to balance the nephrotoxic effects of therapy and the survival of the graft (2).

Proliferation signal inhibitors (PSIs) are known to prevent CAN without inducing nephrotoxic effects. However, it has been reported that PSIs have some adverse effects in renal transplant patients (2,3).

Here, we report a case with nephrotic range proteinuria that developed during treatment with everolimus.

CASE REPORT

A 34-year-old male patient had been undergoing regular hemodialysis for 17 months. Renal transplantation was performed on December 2006. The etiology of renal failure was unknown. The physical examination of the patient was normal. The transplanted kidney belonged to his father.

Doclizumab 1mg/kg was infused over 15 minutes just before transplantation as a part of the immunosuppressive regimen. 500 mgr of pulse metilprednisolon was infused intraoperatively. Mycophenolate mophetil 2x1g, cyclosporin A(CsA) 2x125 mg and steroid was administered postoperatively. He was also on trimethoprim-sulfamethoxazole, valacyclovir and a

proton pump inhibitor. He had 1.32 g/day proteinuria and his residue urine output was 1800 ml/day before the transplantation. After the operation, his blood urea nitrogen was 23 mg/dl and the creatinine level was 1.70 mg/dl. Other biochemical and serological tests were within normal limits. One month after transplantation, his serum creatine levels increased to a value of 3.34 mg/dL, proteinuria was 0.7 g/day and his CsA level was 165 ng/ml. Ultrasonography revealed a perirenal collection (63x9mm) at the upper anterior pole of the graft and completely normal pelvicaliceal structures. It was inappropriate to perform a biopsy because of the collection. This pathological state was considered to be a result of CsA toxicity and/or acute allograft rejection. The patient underwent 250 mg/day methyl prednisolone therapy for three days. The collection was surgically drained. CsA was changed to everolimus 1.5 mg/day and final creatinine level decreased to 1.98 mg/dl. Weekly follow-ups were continued during this period and his serum creatinine levels were about 1.88 mg/dL. In the second month of the everolimus therapy, 9.17 g/day proteinuria was detected at one of these routine examinations. The proteinuria level was 14.8 g/day in a second control test. Blood urea nitrogen level was 27 mg/dl and serum creatinine level was 2.85 mg/dl. His blood everolimus level was 4.48 ng/dl. Renal ultrasound and renal doppler ultrasound were normal. Diagnostic renal biopsy was performed on the transplanted kidney. The pathology evaluation of the renal biopsy did not reveal any evidence of glomerular injury, or acute and chronic allograft rejection. Granular casts and regenerative tubular epithelial changes were seen in

some tubules. Mononuclear infiltration was detected in the interstisium. We considered that the proteinuria could be a side effect of everolimus and changed his medication to tacrolimus. Ten days after switching medication, his proteinuria decreased to 1.1 g/day, blood urea nitrogen level was 17 mg/dl and serum creatinine level was 1.91 mg/dl (Figure 1)

DISCUSSION

The crucial function of a healthy kidney is the ability to excrete urine that is essentially free of filtered protein (4). Persistent proteinuria is a manifestation and perhaps a cause of renal dysfunction and is associated with increased risk of graft loss. It therefore requires immediate and true evaluation (4,5). Appropriate therapy for proteinuria may delay the progression of renal failure. Causes of posttransplantation proteinuria include chronic allograft nephropathy, transplant glomerulopathy, glomerulonephritis (de novo or recurrent), CsA nephrotoxicity, and diabetic nephropathy (4).

Chronic allograft nephropathy is the main cause of renal graft loss (6-8).

The decline in function is often associated with hypertension and an increase in urinary protein secretion, elements of a clinical syndrome that has been called chronic allograft dysfunction. Kidney graft biopsies of these patients show fibrointimal thickening of arteries, interstitial fibrosis and tubular atrophy, lesions characteristic for CAN (7). Risk factors for the development of chronic allograft dysfunction include immune and nonimmune factors (6). Immune risk

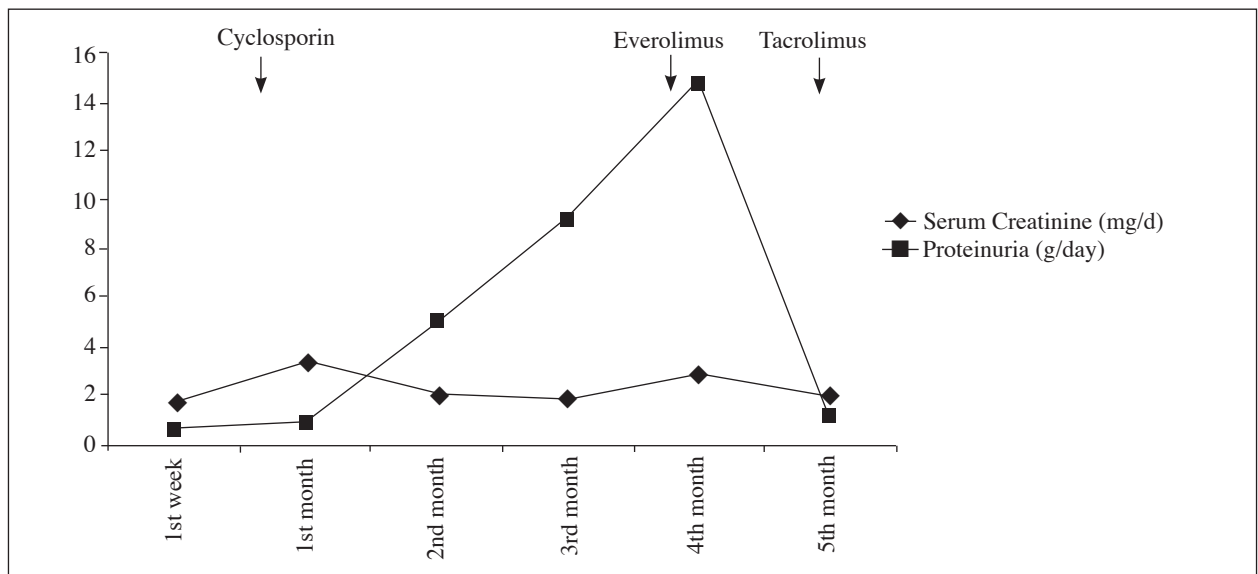


Figure 1: Levels of serum creatinine and proteinuria during follow-up.

factors for CAN include number of HLA mismatches, episodes of severe acute rejection, PRA level, presence of donor-specific anti-HLA antibodies, CMV infection, ischemic injury leading to increased expression of class II MHC molecules and cytokines, and suboptimal immunosuppression (6, 9-11). Nonimmunologic factors include ischemic damage at the time of transplantation, hypertension, hyperlipidemia, proteinuria, ATN, medication toxicity (cyclosporine, tacrolimus) donor and recipient ages, race, gender, donor organ quality, delayed graft function/ischemia reperfusion injury, hyperfiltration, and the number of nephrons in the transplanted kidney (6, 8, 12, 13).

Increasing creatinine levels were detected one month after the transplantation in our patient. It was thought to be CAN as a result of either CsA toxicity or ATN, because all other immunological or nonimmunological causes were excluded. We switched immunosuppressive therapy from CsA to everolimus. Angiotensin converting enzyme inhibitors or angiotensin receptor blockers were not used for the treatment of proteinuria because of the increased creatine levels.

As mentioned, one of the side effects associated with sirolimus is the exacerbation of the nephrotoxic effects of CsA and TAC when administered concomitantly. In general, adverse effects have been the major obstacle to wider sirolimus use as documented in several clinical trials. The most common reasons for interrupting sirolimus therapy include hyperlipidemia, diarrhea, thrombocytopenia, oral ulcers, impaired wound healing, lymphocele, and pneumonia (14-16). More recently, proteinuria has emerged as a worrisome complication of sirolimus therapy (17). De novo proteinuria (protein > 500 mg/dl) has been reported to occur in 37% of patients who converted from a CNI to SRL, with 12% showing nephrotic-range urinary protein excretion. The implication of proteinuria associated with sirolimus is unclear. It seems to develop more commonly when conversion from CNI to sirolimus therapy occurs in the setting of graft dysfunction (18).

Proteinuria in nephrotic ranges developed after everolimus therapy in our case. Proteinuria due to everolimus is reported as a result of tubular damage in literature. On the other hand glomerulosclerosis, interstitial fibrosis and glomerular inflammation can also cause proteinuria (19-21). In a study by Bertoni et al. (22) everolimus-induced proteinuria was shown to have a mixed tubular and glomerular origin. Our patient developed nephrotic-range proteinuria possibly due to everolimus which supports Bertoni et al.'s results. The difference of our case is the development heavy proteinuria (14g/day) in a long time such as two months.

A similar proteinuric effect of sirolimus was reported in the literature and CsA toxicity has developed before so we switched immunosuppressive regimen to tacrolimus (0.1 mg/kg/day). Proteinuria decreased from 14g/day to 1.1g/day following the alterations in the treatment regimen. We assumed that this reduction was related to everolimus. Biopsy was performed on the transplanted kidney to exclude the other causes of proteinuria. We considered the heavy proteinuria to be the result of glomerular sieving more than tubular damage. Our case therefore indicates that the cause of proteinuria related with everolimus has an unknown origin (22).

On the matter of the development of recurrent and de novo glomerular disease in the renal transplant patient; glomerulonephritis is responsible for approximately 15% to 20% of all cases of ESRD and recurrences are well documented in allografts (23). Recurrent glomerular disease registries have been developed in the United States, Australia, and the United Kingdom. The recurrence rate, clinical presentation, and effects on long-term renal function all depend on the original disease (24). On average, glomerular disease recurs in 10% to 30% of cases. In one study, recurrent glomerular disease led to the loss of 2.7% of all transplants, being responsible for 12% of all grafts lost (25). The percentage of grafts lost according to recurrent glomerular disease is time dependent, increasing from 0.6% in the first year to 8% by 10 years after transplantation (24). The most common recurrent primary diseases are focal segmental glomerulosclerosis (FSGS), membranoproliferative glomerulonephritis (MPGN), and membranous nephropathy.

Detection of proteinuria before the development of renal dysfunction may lead to renal biopsy and earlier diagnosis of certain disease. Diagnostic tools such as renal biopsy and appropriate therapy for proteinuric renal disease may delay the progression of renal failure. In the current era of potent immunosuppressive therapy, histological findings of acute graft rejection may be observed in the absence of clinical signs and symptoms or changes in renal function (4).

Biopsy was performed to examine the possible proteinuria etiologies; CAN, recurrent and de novo glomerular disease, everolimus toxicity, rejection. There was no sign of these conditions in the histopathological examination. Proteinuria was in the nephrotic range and rapidly decreased after switching everolimus to tacrolimus (14.8 g/day---1.1g/day). It was therefore assumed that it was a side effect related with everolimus. It is known that proteinuria develops in transplant patients due to sirolimus. Everolimus, a new immunosuppressive

agent which acts in the same way as sirolimus, may also cause proteinuria. Our case is important as it is one of the a few cases with serious proteinuria due to everolimus in the literature.

REFERENCES

1. Pohanka E: Conversion to everolimus in maintenance patients-current clinical strategies. *Nephrol Dial Transplant* 2006; 21 (suppl 3): 24-29
2. Pascual J, Boletis IN, Campistol JM: Everolimus (Certican) in renal transplantation: A review of clinical trial data, current usage, and future directions. *Transplantation Reviews* 2006; 20: 1-18
3. Nahsan B: The role of certican (Everolimus, Rad) in the Many pathways of chronic rejection. *Transplantation Proceedings* 2001; 33: 3215-3220
4. Kasiske BL, Vazquez MA, Harmon WE, Brown RS, Danovitch GM, Gaston RS, Roth D, Scandling JD, Singer GG: For the American Society of Transplantation: Recommendations for the outpatient surveillance of renal transplant recipients. *J Am Soc Nephrol* 2000; 11(suppl 15):1-86
5. Reichel H, Zeier M, Ritz E: Proteinuria after renal transplantation: Pathogenesis and management. *Nephrol Dial Transplant* 2004; 19:301-305
6. Pascual M, Theeruvath T, Kawai T, Tolkoff-Rubin N, Cosimi AB: Strategies to improve long-term outcomes after renal transplantation. *N Engl J Med* 2002; 346:580-590
7. Joosten SA, Sijpkens YWJ, Kooten CV, Paul LC: Chronic renal allograft rejection: Pathophysiologic considerations. *Kidney Int* 2005; 68: 1-13
8. Poul LC: Chronic allograft nephropathy: An update. *Kidney Int* 1999; 56:783-793
9. Nankivell BJ, Borrows RJ, Fung CL, O'Connell PJ, Allen RD, Chapman JR: The natural history of chronic allograft nephropathy. *N Engl J Med* 2003; 349(24):2326-2333
10. Allan JS, Madsen JC: Recent advances in the immunology of chronic rejection. *Curr Opin Nephrol Hypertens* 2002; 11:315-321
11. Almond PS, Matas A, Gillingham K, Dunn DL, Payne WD, Gores P, Gruessner R, Najarian JS: Risk factors for chronic rejection in renal allograft recipients. *Transplantation* 1993; 55(4):752-757
12. Opelz G, Wujciak T, Ritz E: Association of chronic kidney graft failure with recipient blood pressure. Collaborative Transplant Study. *Kidney Int* 1998; 53:217-222
13. Krieger NR, Becker BN, Heisey DM, Voss BJ, D'Alessandro AM, Becker YT, Odorico JS, Kalayoglu M, Pirsch JD, Sollinger HW, Knechtle SJ: Chronic allograft nephropathy uniformly affects recipients of cadaveric, nonidentical living-related, and living-unrelated graft. *Transplantation* 2003; 75(10):1677-1682
14. Gonwa T, Mendez R, Yang HC, Weinstein S, Jensik S, Steinberg S: Randomized trial of tacrolimus in combination with sirolimus or mycophenolate mofetil in kidney transplantation: Result at 6 months. *Transplantation* 2003; 75:1213-1220
15. Mendez R, Gonwa T, Yang HC, Weinstein S, Jensik S, Steinberg S, Prograf Study Group: A prospective, randomized trial of tacrolimus in combination with sirolimus or mycophenolate mofetil in kidney transplantation: Results at 1 year. *Transplantation* 2005; 80(3):303-309
16. Johnson RWG, Kreis H, Oberbauer R, Brattstrom C, Claesson K, Eris J: Sirolimus allows early cyclosporine withdrawal in renal transplantation resulting in improved renal function and lower blood pressure. *Transplantation* 2001; 72:777-786
17. Bumba V, Ribes D, Kamar N, Esposito L, Modesto A, Guitard J, Nasou G, Durand D, Rostaing L: Outcome of renal-transplant (RT) patients switched from calcineurin inhibitors (CNIs) to sirolimus (SRL) for chronic allograft dysfunction (CAD). *Am J Transplant* 2005; 5:463A(suppl 11;abstr 1202)
18. Diekmann F, Budde K, Oppenheimer F, Fritsche L, Neumayer HH, Campistol JM: Predictors of success in conversion from calcineurin inhibitor to sirolimus in chronic allograft dysfunction. *Am J Transplant* 2004; 4:1869-1875
19. Wittmann S, Daniel C, Braun A, Vogelbacher R, Shimizu F, Kawachi H, Hugo C: The mTOR inhibitor everolimus attenuates the time course of chronic anti-Thy1 nephritis in the rat. *Nephron Exp Nephrol* 2008; 108(2): 45-56
20. Vogelbacher R, Wittmann S, Braun A, Daniel C, Hugo C: The mTOR inhibitor everolimus induces proteinuria and renal deterioration in the remnant kidney model in the rat. *Transplantation* 2007; 84(11):1492-1499
21. Letavernier E, Legendre C: mTOR inhibitors-induced proteinuria: Mechanisms, significance, and management. *Transplantation Reviews* 2008; 22:125-130
22. Bertoni E, Bruschi M, Candiano G, Boccardi C, Citti L, Mangraviti S, Rosso G, Larti A, Rosati A, Ghiggeri GM, Salvadori M: Posttransplant proteinuria associated with everolimus *Transplant Proc* 2009; 41(4):1216-1217
23. U.S. Renal Data System: USRDS 2003 Annual data report: atlas of end-stage renal disease in the United States 2003. Bethesda: National Institutes of Health, National Institute of Diabetes and Digestive and Kidney Disease, 2003;1-56
24. Briganti EM, Russ GR, McNeil JJ, Atkins RC, Chadban SJ: Risk of renal allograft loss from recurrent glomerulonephritis. *N Engl J Med* 2002; 347(2):103-109
25. Ponticelli C, Villa M, Cesana B, Montagnino G, Tarantino A: 2002 Risk factors for late kidney allograft failure. *Kidney Int* 2002; 62(5):1848-1854