

Testicular Involvement in Wegener Granulomatosis: Case Report and Review of the literature

Wegener Granülomatozis'te Testis Tutulumu: Olgu Sunumu ve Literatür Taraması

ABSTRACT

Wegener granulomatosis (WG) is a type of necrotising vasculitis that affects mainly the respiratory tract, paranasal sinuses and the kidneys. Urogenital involvement is rare; mainly affecting the prostate gland. Testicular involvement in WG is exceptional. We report a 50-year-old male patient with hematuria, proteinuria and testicular pain and renal failure diagnosed as WG by testicular and kidney biopsy. We also provide a review of the literature

KEY WORDS: Wegener granulomatosis, Testis, Necrosis

ÖZ

Wegener Granülomatozis (WG) bir nekrotizan vaskülit çeşidi olup genellikle solunum yolları, paranasal sinüs ve böbreği etkiler. Ürogenital tutulum nadirdir ve genellikle prostat etkilenir. Testis tutulumu enderdir. Biz hematüri, proteinüri, böbrek yetmezliği ve testis ağrısıyla başvuran 50 yaşındaki erkek hastada böbrek ve testis biyopsisiyle WG tanısı koyduk. Lteratür bilgisi eşliğinde sunuyoruz.

ANAHTAR SÖZCÜKLER: Wegener granülomatozis, Testis, Nekroz

INTRODUCTION

Wegener granulomatosis (WG) is a type of necrotising vasculitis that affects mainly the respiratory tract, paranasal sinuses and the kidneys (1). It mostly presents with nonspecific symptoms in whites and/or males in the 4th or 5th decades of life. Rhinitis, malaise, fever, fatigue are the most common symptoms. It causes rapidly progressive glomerulonephritis in the kidneys and leads to chronic renal failure.

Inflammation and granuloma formation are the major findings in histological samples. Anti-neutrophilic cytoplasmic antibodies (ANCA) are considered to be responsible for the inflammatory status. Cytoplasmic ANCA (c-ANCA) titers are used as diagnostic tool. However, its positivity does not mean WG and negativity does not rule out the disease. c-ANCA levels are positive in 90% and 75% of the patients with generalized and localized WG, respectively. Both the criteria

of the American College of Rheumatologists and Chapel Hill Consensus Conference are used to describe WG (2). Steroid therapy and cyclophosphamide are the mainstay of therapy. WG may be associated with a fatal outcome if left untreated.

In less than 1% of the patients, other parts of the body such as the heart, central nervous system, parotid gland and the urogenital tract may be affected (3). Urogenital involvement is rare; mainly affecting the prostate gland. In a series by Huang and et al, only 8 patients of the 83 patients with WG had urogenital involvement (3 with prostate and 1 ovarian) (4).

Testicular involvement in WG is exceptional. In this case report, we report a patient with WG in whom the testicles were involved and provide a review of the literature.

Mehmet Nuri TURAN¹
Özkan GÜNGÖR¹
Fatih KIRÇELLİ¹
Erhan TATAR¹
Banu SARSIK²
Ebru OK SEVİNÇ¹
Gürhan GÜNAYDIN³
Ali BAŞÇI¹
Gülay AŞÇI¹

- 1 Ege University School of Medicine, Department of Nephrology, Izmir, Turkey
- 2 Ege University School of Medicine, Department of Pathology, Izmir, Turkey
- 3 Ege University School of Medicine, Department of Urology, Izmir, Turkey

Received : 17.01.2012

Accepted : 20.01.2012

Correspondence Address:

Özkan GÜNGÖR

Ege Üniversitesi Tıp Fakültesi,

Nefroloji Bilim Dalı, Izmir, Turkey

Phone : + 90 506 664 80 54

E-mail : ozkangungor@yahoo.com.tr

CASE

A 50 year old male was admitted to the emergency room with fever (39°C), malaise, hemoptysis, testicular pain for the last week and anuria.

His past history revealed 2 ureteral dilatations 3 years and 1 month ago. One week after second discharge, he started to have fever and was hospitalized. His serum creatinine level was 2.2 mg/dl (was normal at the last visit) and had 2.5 gram/day proteinuria. Empirical antibiotherapy was initiated; blood and urine cultures were negative. Despite antibiotherapy his fever could not be taken under control. Further investigation showed larger kidneys with increased echogenicity in renal ultrasonography and < 1.0 cm pericardial effusion in echocardiography. He also underwent genital ultrasonography for scrotal pain and suspected bilateral testicular mass or abscess formation was observed. He was sent to the nephrology outpatient clinic when he had progressive renal failure and needed dialysis.

At admission to our clinic, he had fever (38,5°C). His blood pressure was 130/80 mmHg and pulse rate 96 beats per minute on physical examination. He had tenderness on his left testicle at genital examination. His laboratory findings were: serum urea 72 mg/dl, creatinine 6.1 mg/dl, hemoglobin 9.8 g/dl, hematocrit 28.5%, platelet 207.000/mm³, hs-CRP 23 mg/dl. He also had hematuria and 4 gram/day proteinuria on spot urine sample. C3 level was 122 mg/dl (90–180) and C4 17 mg/dl (10–40). PR3-ANCA: 34 U/ml (<5) was positive, anti-nuclear antibody and p-ANCA were negative. Chest X-ray, renal ultrasonography and echocardiography were normal. A re-examination of the oropharyngeal system revealed no pathological findings. Chest CT and bronchoscopy were not performed while chest X-ray was normal and hemoptysis could not be justified. Urine and blood

cultures were normal. On scrotal Doppler ultrasonography, right testicle size was measured as 4,0x2,2x3,3 cm and left testicle 4,5x2,0x2,8 cm. Parenchyma and vascularity of the right testicle was normal. However, in the left testicle, two isoechogenic solid non-homogenous masses, one on the medial upper half with a size of 10x9x7 mm and another on the anterior of the lower half with a size of 7x5x4 mm were found. Whether it was a neoplasia or not could not be determined by scrotal ultrasonography. The patient was evaluated by an urologist and orchietomy was offered to the patient for diagnosis because AFP and b-HCG were normal.

At the same time, kidney biopsy was offered to the patient for renal failure and was performed after the patient accepted the procedure. Light microscopy showed fibro-cellular crescents and necrotizing areas in all of the 15 glomeruli and degenerative changes and interstitial inflammatory cell infiltrates in the tubules. Irregular C3 positivity (++) and no IgG, IgM, IgA, kappa, lambda, fibrinogen, C1q deposition were found in immunofluorescence staining. The final pathological diagnosis was small vessel vasculitis - WG (Figure 1).

Also, after approval of the patient to undergo orchietomy, left orchietomy was performed. Orchietomy material was 105 gram in weight, 8.5 cm in width and had a diameter of 1.8 cm. The outer surface was normal. A 0.6x0.4 cm hemorrhagic area with congestion and infarctions was observed near the rete testis. Histological analysis showed fibrosis by Masson Trichrome stain and abnormal vascular areas by Von Giesson stain (Figure 2). Final pathological diagnosis was testicular WG.

The patient was therefore considered as WG with renal and testicular involvement. 1000 mg/day pulse steroid for 3 days and a single 750 mg cyclophosphamide were given as initial

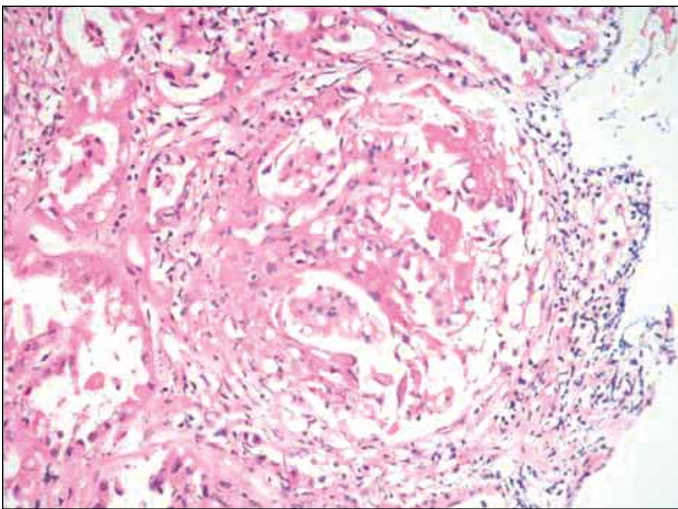


Figure 1: Magnification of a renal biopsy specimen (H&E stain, x 200) showing typical fibrinoid necrosis and crescent formation.

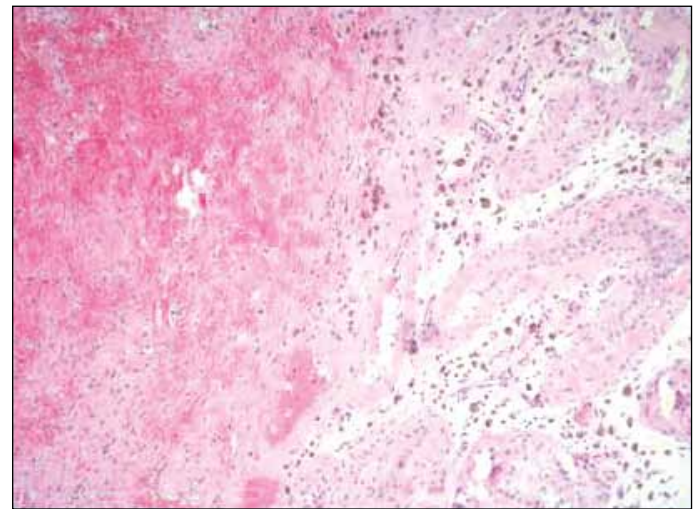


Figure 2: Photomicrograph of an orchietomy specimen (H&E stain, x 200) showing necrosis and haemorrhage adjacent to seminiferous tubules.

therapy after accessing the renal biopsy findings. In addition, 7 session plasma exchange were performed. Maintenance therapy consisted of 64 mg/day oral steroid and 100 mg/day oral cyclophosphamide. At follow-up, the fever resolved, diuresis started and serum creatinine levels decreased to 3.5 mg/dl and PR3-ANCA levels to 18 U/ml in the first month. The patient is still being followed at our outpatient clinic.

DISCUSSION

In this case report we present a rare involvement of WG in the testicles. WG is an autoimmune disease of unknown etiology. It is suggested that antibodies against ANCA are responsible for the inflammation. It is characterized by an initial or localized phase, usually followed by a generalized or systemic phase (5). The most common symptoms are rhinitis, malaise, fever and weight loss. Approximately 80% of the patients progress to generalized or systemic WG (6). ANCA positivity is the most common diagnostic tool used; however, it does not mean that the patient has WG. ANCA is positive in more than 90% of the patients. (7). The diagnosis of Wegener's granulomatosis is mainly made by the histological demonstration of vasculitis; granulomatous inflammation and necrosis in the involved organs. Current treatment protocols include cyclophosphamide and corticosteroids, supported by plasma exchange in case of severe renal vasculitis or pulmonary hemorrhage. Optimization of treatment protocols have led to remission rates of 70–90% in the first year and early mortality rates of 5–12% (8). However, 10% of patients remain refractory to treatment (9).

Differential diagnosis of a mass in testis includes neoplasms, torsion of the testis and infectious diseases. Rarely, it may be a part of a systemic disease. Although testicular involvement may occur in vasculitic diseases such as Behçet or granulomatous diseases, it is seldom the first manifestation (10). The gold standard is testicular biopsy or biopsy during orchiectomy. It is reported that Polyarteritis Nodosa is the most common cause of necrotizing vasculitis of the testis but urologists, nephrologists and pathologists should be aware of the rare testicular presentation of WG (11). The limited form of Wegener's granulomatosis involving the urogenital tract (scrotum, testis, bladder, prostate, urethra, epididymis and penis) is very rare, though it has been reported before. It may also be a part of the generalized WG. Davenport et al. presented eight patients with limited Wegener's granulomatosis localized to the urogenital tract; only two had testicular involvement (12). Di Comite et al. reported only 4% testicular involvement in 50 patients with WG (13). Others reported similar rates (14, 15). Even though WG primarily affects adults, Barber et al reported a unilateral testicular infarct in a 12-year-old child (16).

Testicular biopsy has never been mentioned as a potential site for tissue sampling in the medical literature. Its advantages are its easy access, not so invasive nature and relatively fewer and minor complications compared to biopsies from other sites

such as the lung (17). The most common complication local hematoma and the most serious is inadvertent biopsy of the epididymis. Orchiectomy shall be preferred in patients in whom malignancy can not be differentiated. Testicular localization of systemic disease does not change the general treatment.

In conclusion; we describe a rare case of WG with testicular involvement where the diagnosis was determined by testicular biopsy. A thorough physical examination is very important in patients with WG and examination of external genitalia should not be ignored even specific symptoms are not present.

REFERENCES

1. Schilder AM: Wegener's Granulomatosis vasculitis and granuloma. *Autoimmun Rev* 2010; 9: 483-487
2. Arend WP, Michel BA, Bloch DA, Hunder GG, Calabrese LH, Edworthy SM, Fauci AS, Leavitt RY, Lie JT, Lightfoot RW Jr: The American College of Rheumatology 1990 criteria for the classification of Takayasu arteritis. *Arthritis Rheum* 1990; 33: 1129-1134
3. Allende DS, Booth CN: Wegener's granulomatosis of the breast: A rare entity with daily clinical relevance. *Ann Diagn Pathol* 2009; 13: 351-357
4. Huong DLT, Papo T, Piette JC, Wechsler B, Bletry O, Richard F, Valcke JC, Godeau P: Urogenital manifestations of Wegener's granulomatosis. *Medicine* 1995; 74: 152-161
5. Langford CA, Hoffman GS: Rare disease 3: Wegener's granulomatosis. *Thorax* 1999; 54: 629-637
6. Sharaf PH, Yazici Y: Necrotizing vasculitis-a 2009 update. *Bull NYU Hosp Jt Dis* 2009; 67: 303-305
7. Langford CA: The diagnostic utility of c-ANCA in Wegener's granulomatosis. *Clev Clin J Med* 1998; 65: 135-140
8. Ozaki S: ANCA-associated vasculitis: Diagnostic and therapeutic strategy. *Allergol Int* 2007; 56: 87-96
9. Holle JU, Laudien M, Gross WL: Clinical manifestations and treatment of Wegener's granulomatosis. *Rheum Dis Clin North Am* 2010; 36: 507-526
10. Gillot JM, Brouillard M, Hatron PY, Devulder B: Testicular localization of systemic diseases. *Presse Med* 1995; 24: 691-694
11. Meeuwissen J, Maertens J, Verbeken E, Blockmans D: Case reports: Testicular pain as a manifestation of polyarteritis nodosa. *Clin Rheumatol* 2008; 27: 1463-1466
12. Davenport A, Downey SE, Goel S, Maciver AG: Wegener's granulomatosis involving the urogenital tract. *Br J Urol* 1996; 78: 354-357
13. Di Comite G, Bonavida G, Bozzolo E, Bianchi S, Ciboddo G, Tresoldi M, Praderio L, Sabbadini MG: Wegener's granulomatosis: An analysis of 50 patients. *Reumatismo* 2005; 57: 187-192

14. Lee SS, Tang SH, Sun GH, Yu CP, Jin JS, Chang SY: Limited Wegener's granulomatosis of the epididymis and testis. *Asian J Androl* 2006; 8: 737-739
15. Minnee RC, van den Berk GE, Groeneveld JO, van Dijk J, Turkcan K, Visser MJ, Vahl AC: Aortic aneurysm and orchitis due to Wegener's granulomatosis. *Ann Vasc Surg* 2009; 23: 15-19
16. Barber TD, Al-Omar O, Poulik J, McLorie GA: Testicular infarction in a 12-year-old boy with Wegener's granulomatosis. *Urology* 2006; 67: 9-10
17. Agraharkar M, Gokhale S, Gupta R: Wegener's granulomatosis diagnosed by testicular biopsy. *Int Urol Nephrol* 2003; 34: 559-564