

Cholesterol Embolization Syndrome Developing after Coronary Angiography in a Hemodialysis Patient

Hemodiyaliz Hastasında Koroner Anjiyografi Sonrası Gelişen Kolesterol Embolizasyon Sendromu

ABSTRACT

Cholesterol Embolization Syndrome (CES) is a systemic disorder due to cholesterol crystal embolization from atherosclerotic plaques of the aorta and its major branches to the small arterioles, resulting in local ischemia and organ damage. The diagnosis is mostly missed, especially in dialysis patients. There is no definite treatment available and the mortality is relatively high. We present a hemodialysis patient with cholesterol embolization syndrome who developed discoloration of the toes and necrotic ulcers after coronary angiography and whose diagnosis was confirmed with skin biopsy, and discuss the case with literature information.

KEY WORDS: Cholesterol embolization syndrome, Hemodialysis, Atherosclerosis, Chronic kidney failure

ÖZ

Kolesterol embolizasyon sendromu (KES), aorta ve major dallarının aterosklerotik plaklarından kaynaklanan kolesterol kristallerinin küçük arteriollerini tıkaması ile meydana gelen sistemik bir bozukluk olup, lokal iskemi ve organ hasarı ile sonuçlanır. Tanı çoğu zaman özellikle diyaliz hastalarında atlanmakta olup kesin bir tedavisi yoktur ve mortalitesi oldukça yüksektir. Burada koroner anjiyografi sonrası ayak parmaklarında morarma ve nekrotik ülsere yaraları gelişen ve cilt biyopsisi ile tanısı doğrulanan kolesterol embolizasyon sendromu olan hemodiyaliz hastası literatür bilgileri ile tartışılmıştır.

ANAHTAR SÖZCÜKLER: Kolesterol embolizasyon sendromu, Hemodiyaliz, Aterosklerozis, Kronik böbrek yetmezliği

INTRODUCTION

CES is a severe complication of atherosclerotic vascular disease and is caused by the cholesterol crystal embolization from atherosclerotic plaques to various organs. It may both occur as a consequence of various triggering procedures such as arteriography, vascular surgery, or anticoagulation, and may also emerge spontaneously (1-2). The damages in the organs and tissues are due to the combination of severe inflammatory reaction and the mechanically obstructive effect of the cholesterol crystals in the microcirculation. The basic predisposing factors are diabetes, hypertension and atherosclerosis. These emboli are mostly

forgotten in the differential diagnosis in dialysis patients and are rarely diagnosed (1,3-7). The clinical picture may range from completely asymptomatic to multi-systemic disease. Indicative signs of the disease are the presence of risk factors such as atherosclerosis; the characteristic findings of renal, skin and eye involvement; and laboratory findings such as hypereosinophilia and hypocomplementemia. In the absence of clinical evidences or when confirming the diagnosis, it is important to histopathologically detect the cholesterol crystals in the target organ and this is the only way to distinguish the disorder from systemic vasculitis (1).

Bülent KAYA¹
Eda ALTUN¹
İbrahim KARAYAYLALI¹
Saime PAYDAŞ¹
Neslihan SEYREK¹
Gülfiliz GÖNLÜŞEN²
Fatih YILDIZ³

- 1 Çukurova University Faculty of Medicine, Department of Nephrology, Adana, Turkey
- 2 Çukurova University Faculty of Medicine, Department of Pathology, Adana, Turkey
- 3 Çukurova University Faculty of Medicine, Department of Rheumatology, Adana, Turkey



Received : 28.04.2013

Accepted : 16.05.2013

Correspondence Address:

Bülent KAYA
 Çukurova Üniversitesi Tıp Fakültesi,
 Nefroloji Bilim Dalı, Adana, Turkey
 Phone : + 90 506 581 97 01
 E-mail : bulentkaya32@gmail.com

CASE REPORT

A 68-year-old male patient, who had suffered from hypertension and chronic obstructive pulmonary disease for 30 years and who had been receiving hemodialysis treatment 3 times a week through a right internal jugular tunnel-catheter at an external center for 7 months, presented to our clinic due to the bruises and necrotic ulcer lesions that had emerged on the toes of both feet.

Coronary angiography had been performed and a stent placed due to acute myocardial infarction 6 weeks before the patient applied to our clinic. He had been recommended to use painkillers and creams containing topical steroids at the hospitals he had gone to 15 days after the coronary angiography due to the bruises and wounds that had emerge on the toes of both feet. However, the complaints did not decrease with these treatments and he presented at our clinic.

Physical examination on presentation revealed blood pressure 150/90 mmHg, pulse rate 96/min, respiratory rate 22/min, fever 36,5°C, and general condition good. There were thin rales in bilateral lung basals of the patient with neck venous distension. The expirium was distinctly long and rhonchi were heard. Bilateral toes were cyanotic, the 1st and 5th distal phalanges of the right foot and the 3rd and 5th distal phalanges of the left foot were necrotic, the peripheral pulses were patent (Figure 1,2). Bilateral 2+ pretibial edema was present. The patient was anuric. Laboratory tests revealed glucose 110 mg/dl, BUN 105 mg/dl, creatinine 5.55 mg/dl, total protein 6 gr/dl, albumin 2.3 gr/dl, ALT 6 IU/L, AST 29 IU/L, ALP 61 IU/L, Ca 7.9 mg/dl, P 6.3 mg/dl, Na 138 mEq/L, K 4.1 mEq/L, total cholesterol 91 mg/dl, LDL cholesterol 55 mg/dl, HDL cholesterol 29 mg/dl, triglyceride 84 mg/dl, Hb 7.12 gr/dl, platelet 201,000/mm³, WBC 11400/ mm³,

Neutrophil 80%, lymphocyte 13.2%, monocyte 4.07, eosinophil 1%, Sedimentation 34 mm/h, TSH 2.4 mIU/L, C3 69.7 mg/dl, and C4 22.1 mg/dl.

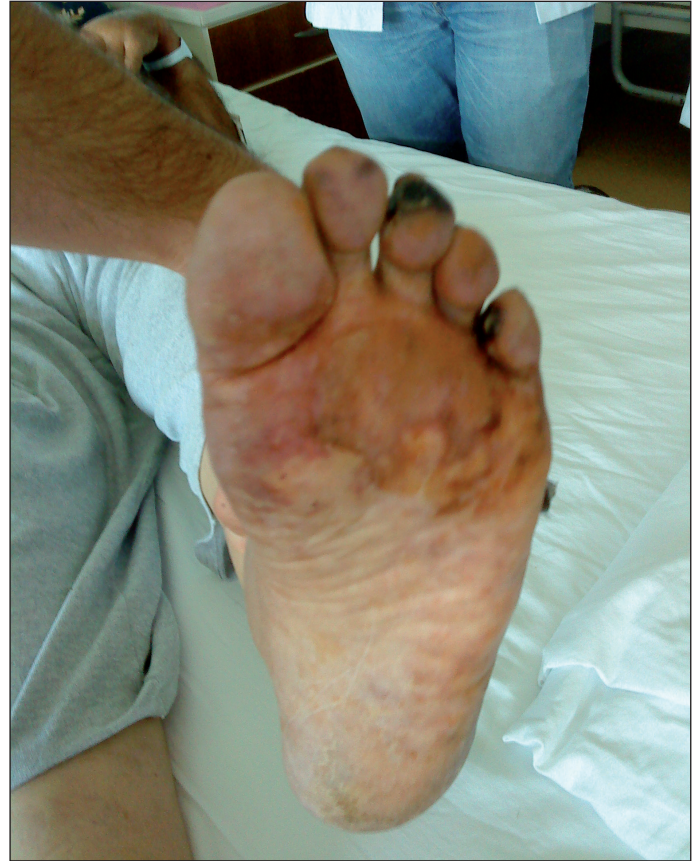

Figure 2: Cyanotic fingers of the right foot, the 1st and 5th distal phalanx view necrotic.

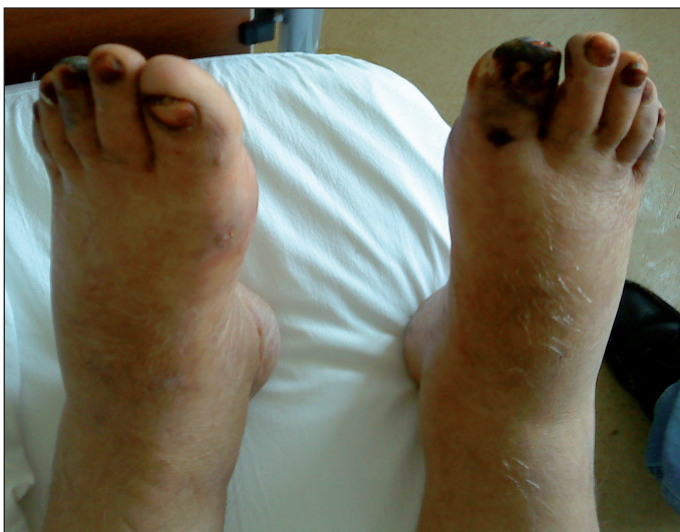

Figure 1: Bilateral toes were cyanotic, the 1st and 5th distal phalanges of the right foot and the 3rd and 5th distal phalanges of the left foot were necrotic.

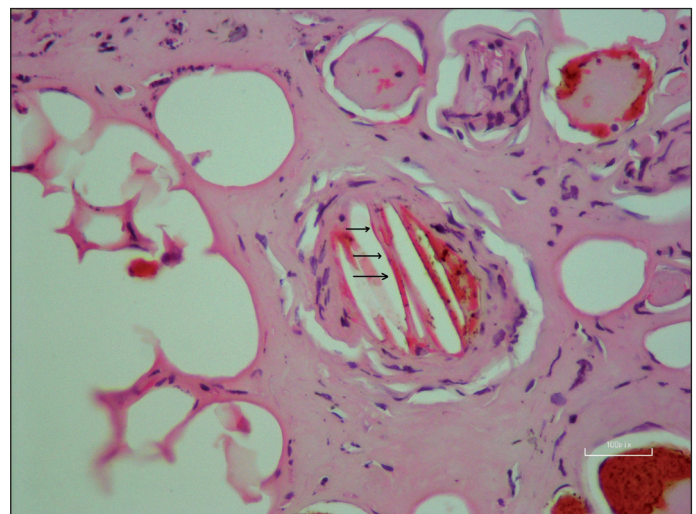


Figure 3: A skin biopsy from the periphery of the lesion on the right foot distal phalanx area showed an arteriole in the subcutis with typical needle-shaped (cholesterol) clefts.

Lower extremity Doppler ultrasound showed calcified plaques on the wall of lower extremity arteries but no thrombosis. Antinuclear antibody, anti-Double stranded DNA, Rheumatoid Factor, antineutrophil cytoplasmic antibody, and glomerular basal membrane antibody were negative. Echocardiography showed findings and symptoms of hypervolemia and cardiac insufficiency with EF % 45, IVS 15.5 mm, left atrium diameter 47 mm, left ventricular diffuse hypokinetic, diastolic dysfunction, mitral ¼ insufficiency, aorta ¼ insufficiency, and tricuspid ¼ insufficiency. There was no evidence of intracardiac mass, thrombus or vegetation. Antiaggregant and anti-ischemic treatment was recommended by the cardiology clinic. We aimed to reach the dry weight by applying frequent dialysis to the patient with cardiac insufficiency and hypervolemia and blood transfusions were used for the anemia. Hypocomplementemia was present but no eosinophilia was found. Fundus examination was normal. The patient was clinically thought to have CES. Skin biopsy from the 1st distal phalanx of the right foot showed cholesterol emboli (Figure 3).

Treatment with methyl prednisolone, iloprost, aspirin, amlodipine, pentoxifylline, and atorvastatin was administered. Iloprost was given as a 6-hour IV infusion with renal dose adjustment. On the 4th day of the treatment, myocardial infarction emerged 6 hours after the completion of the infusion and coronary angioplasty was decided on. However, the catheterization was unsuccessful and the patient died in the coronary intensive care unit a few hours after this procedure.

DISCUSSION

CES is a severe complication of atherosclerosis. Our patient had many of the known major risk factors for cholesterol embolization syndrome such as advanced age, male gender, acute coronary syndrome, hypertension, diabetes, cigarette smoking, abdominal aneurysm, and cerebrovascular disease. The triggering event can be invasive procedures such as angiography, angioplasty and arteriography to the aorta and major vessels, anticoagulant treatment, and thrombolysis (1,8-10). The lesions on the foot emerged 15 days after coronary angiography in our patient who had undergone dialysis treatment for 7 months.

Skin symptoms are common in cholesterol embolization. These symptoms include, in descending order, livedo reticularis, gangrene, cyanosis, skin ulcer, petechia and purpura, and painful erythematous nodules. The gangrene and ulcers typically affect the toes and may spread to involve the proximal lower extremity (11). CES was diagnosed with the skin symptoms. Bilateral toes were cyanotic, and the 1st and 5th distal phalanges of the right foot and the 3rd and 5th distal phalanges of the left foot were necrotic.

CES primarily affects the arcuate and interlobar arteries in the kidney. The cholesterol crystals can rarely cause embolization of the afferent arteriole and glomerulus. Due to the patch-like distribution of cholesterol crystal emboli in the kidney, renal

biopsy may not reveal the lesions (1). The primary manifestation of renal CES is an increase in serum creatinine, proteinuria and HT and may lead to acute or chronic kidney failure (11,12). Despite the high frequency of precipitating factors (diffuse cardiovascular disease, hypertension, dyslipidemia, diabetes), very few CES cases are reported in dialysis patients in the literature (13). Unfortunately, the diagnosis is generally missed in dialysis patients due to the fact that there is no diagnostic serological method and the disorder may not be considered in the differential diagnosis. In our case, the cause of the foot wounds that emerged after the angiography could not be determined by many physicians. The patient got diagnosed at our center approximately 6 weeks later.

Laboratory test results are generally non-specific and include leukocytosis, anemia, thrombocytopenia, increased sedimentation due to inflammatory markers, increased CRP and fibrinogen, and temporary hypocomplementemia and eosinophilia (8). Our case was found to have leukocytosis, anemia, increased CRP and low C3.

The definitive diagnosis of the disease is established through biopsy of the affected tissues and organs such as the skin, muscle and kidneys. The characteristic pathologic lesion of cholesterol crystals that lead to occlusion in the affected arteriole is observed as needle-like clefts in the lumen (11). In our case, the cholesterol embolization was confirmed by tissue biopsy (Figure 3). Furthermore, ophthalmoscopy can provide a non-invasive diagnostic method in the diagnosis of CES with the observation of characteristic Hollenhorst plaques (14). However, the fundus examination of our patient was normal.

The effects of aspirin, statin, cessation of anticoagulation, surgical correction of the source of emboli (15). There are reports that steroid treatment is useful and that the prostacyclin analog iloprost is useful in correcting the ischemia in the distal extremities and renal insufficiency (15,16). We started treatment with methyl prednisolone, iloprost, aspirin, pentoxifylline, and atorvastatin as soon as the diagnosis was made. We could not evaluate the effectiveness of treatment as the patient died due to a myocardial infarction.

When we first saw the patient and evaluated the risk factors, the skin lesions and the recent vascular intervention history, our first diagnosis was cholesterol embolization syndrome and this was confirmed via the skin biopsy. Since the patient was a hemodialysis patient, the renal findings were masked and therefore the previous centers to which he gone to before our clinic failed to notice the diagnosis. When we reviewed the literature, we saw that there are not large numbers of CES cases in hemodialysis patients. We are therefore publishing this case to emphasize that it is necessary to consider this condition in the differential diagnosis.

REFERENCES

1. Scolari F, Tardanico R, Zani R, Pola A, Viola BF, Movilli E, Maiorca R: Cholesterol crystal embolism: A recognizable cause of renal disease. *Am J Kidney Dis* 2000; 6: 1089-1109
2. Park S, Schroeter A, Park Y, Forston J: Purple toes and livedo reticularis in a patient with cardio-vascular disease taking coumadin. *Arch Dermatol* 1993; 129: 777-780
3. Harrington JT, Sommers SC, Kassirer JP: Atheromatous emboli with progressive renal failure. *Ann Intern Med* 1968; 68: 152-160
4. Mayo RR, Schwartz RD: Redefining the incidence of clinically detectable atheroembolism. *Am J Med* 1996; 100: 524-529
5. Carvajal JA, Anderson WR, Weiss L, Grismer J, Berman R: Atheroembolism: An etiologic factor in renal insufficiency, gastrointestinal hemorrhages and peripheral vascular diseases. *Arch Intern Med* 1967; 119: 593-599
6. Modi KS, Rao VK: Atheroembolic renal disease. *J Am Soc Nephrol* 2001; 12: 1781-1787
7. Gillerot G, Sempoux C, Pirson Y, Devuyt O: Which type of dialysis in patients with cholesterol crystal embolism? *Nephrol Dial Transplant* 2002; 17: 156-158
8. Fukumoto Y, Tsutsui H, Tsuchihashi M, Masumoto A, Takeshita A; Cholesterol Embolism Study(CHEST) Investigators: The incidence and risk factors of cholesterol embolization syndrome, a complication of cardiac catheterization: A prospective study. *J Am Coll Cardiol* 2003; 42(2):211-216
9. Machino-Ohtsuka T, Seo Y, Ishizu T, Sekiguchi Y, Sato A, Tada H, Watanabe S, Aonuma K: Combined assessment of carotid vulnerable plaque, renal insufficiency, eosinophilia, and hs-CRP for predicting risky aortic plaque of cholesterol crystal embolism. *Circ J* 2010; 74:51-58
10. Funabiki K, Masuoka H, Shimizu H, Emi Y, Mori T, Ito M, Nakano T: Cholesterol crystal embolization (CCE) after cardiac catheterization. A case report and a review of 36 cases in the Japanese literature. *Jpn Heart J* 2003; 44(5):767-774
11. Fine MJ, Kapoor W, Falanga V: Cholesterol crystal embolization: A review of 221 cases in the English literature. *Angiology* 1987; 38:769
12. Lye WC, Cheah JS, Sinniah R: Renal cholesterol embolic disease. Case report and review of the literature. *Am J Nephrol* 1993; 13:489-493
13. Piccoli GB, Fenoglio R, Colla L, Bilucaglia D, Mezza E, Burdese M, Bermond F, Segoloni GP: Cholesterol crystal embolism syndrome in dialysis patients: An emerging clinical diagnosis? *Blood Purif* 2006; 24(5-6):433-438
14. Gittinger JW Jr, Kershaw GR: Retinal cholesterol emboli in the diagnosis of renal atheroembolism. *Arch Intern Med* 1998;158(11):1265-1267
15. Elinav E, Chajek-Shaul T, Stern M: Improvement in cholesterol emboli syndrome after iloprost therapy. *BMJ* 2002;324(7332):268-269
16. Boero R, Pignataro A, Rollino C, Quarello F: Do corticosteroids improve survival in acute renal failure due to cholesterol atheroembolism? *Nephrol Dial Transplant* 2000;15(3):441