

Araştırma Makalesi

OSSIFICATION AND GROWTH OF THE RIBS AND STERNUM IN PREHATCHING PERIOD OF THE HUBBERT STRAIN BROILER*

Ş. Hakan ATALGIN¹, İbrahim KÜRTÜL², Sami ÖZCAN², Emine Ü. BOZKURT³

Geliş Tarihi : 01.06.2007

Kabul Tarihi : 12.12.2007

Kuluçka Döneminde Hubbert Irkı Broylerlerde Sternum ve Kostaların Kemikleşme ve Gelişiminin Belirlenmesi

Özet: Son yıllarda kanatlılar üzerinde yapılan deneysel embriyolojik çalışmalar özellikle iskelet mutasyonları, yapay ortamlarda embriyo kültürlerinin gelişimi ve yeni ilaçların teratolojik etkilerini içermektedir. Normal iskelet gelişimi verileri, bu çalışmaların yorumlanması ve doğrulanması için vazgeçilmez parametrelerdir. Araştırmada, inkubasyonun 10. gününden 20. güne kadar hergün 10 adet Hubbert (JV) ırkı embriyosu kuluçka makinesinden çıkartılarak sternum ve kostaların kemikleşmesi ve gelişimi gözlemlendi. %10'luk formaldehit solusyonunda ve % 95'lik etanolde tespit edilen embriyolar temizlenerek, kıkırdak ve kemik dokuların ayrı renklerde tespiti için alcian blue ve alizarin red ile boyandı. İskelet sisteminin gözlenmesi ve fotoğraf çekimleri, özellikle kıkırdaklaşma ve kemikleşme zamanları dikkate alınarak, stereoskopik mikroskopla yapıldı. Kostalarda ilk kemikleşme merkezi inkubasyonun 11. gününde saptandı. Sternumun kemikleşmesinin ise 15. günde başladığı gözlemlendi. Çalışmada, kostalarda bulunan Processus uncinatus'ların çok erken kıkırdaklaşma ve kemikleşme sürecine başladığı tespit edildi. Kemikleşmiş kısımların gelişiminin inkubasyonun 20. gününe kadar devam ettiği saptandı.

Anahtar Kelimeler: Broyler, Kosta, Kemikleşme, Sternum

Abstract: Recent researches in experimental embryology of avian species have particularly investigated skeletal mutations, development of cultured embryos under artificial conditions, and teratogenic consequences of new drugs. Data on the normal skeletogenous stages are also essential parameters to interpret and elucidate the data acquired on these studies. Accordingly, a number of 10 embryos were prepared every 24 h from 10 to 20 days of incubation, to report the ossification and growth of the ribs and sternum of the

* Preliminary results of this study have been presented in the 4th National Veterinary Anatomy Congress in Kayseri, 2006.

¹ Abant İzzet Baysal Üniversitesi Mudurnu Süreyya Astarıcı Meslek Yüksek Okulu, Mudurnu-Bolu.

² Kafkas Üniversitesi Veteriner Fakültesi Anatomi ABD, Kars.

³ Harran Üniversitesi Veteriner Fakültesi Anatomi ABD, Şanlıurfa.

Hubbert strain broiler (JV). The embryos fixed in 10% formaldehyde then 95% ethanol solutions were cleared and the skeletons of the embryos were stained *in toto* with Alcian blue&alizerin red for cartilage and ossified components, respectively. Observation of the skeletons photography were performed under a stereoscopic microscopy, paying particular attention to the timing of chondrification and ossification of the bones. The first occurrence of the ossification was observed in the ribs on the 11th day of incubation. Those in the sternum were seen on the 15th day. We observed in this study that the uncinat processes of the ribs showed very early chondrification and ossification. The ossified components continued to develop until the 20th day of incubation when the hatching took place.

Key Words: Broiler, ossification, rib, sternum

Introduction

Researches in experimental embryology of avian species have reached to extraordinary level. They focus particularly on natural skeletal development, teratological testing, and developmental engineering. Thus, teratological experiments using artificial *in vivo* cultures have been performed to create transgenic or chimeric birds from 1-cell or blastoderm stage (3, 10, 14, 15, 17). Current researches are designed also to investigate embryonic skeletogenesis (6), skeletal mutations (12, 20), and development of cultured embryos under artificial conditions (10) and to reveal teratogenic consequences of new drugs (6, 7).

Using avian embryo, as a model in embryological research, comprises incredible values including smaller body size, more and fast prolificness, and preciousness. Experimental embryology requires a list of natural embryonic developmental stages as the normal control to design and analyze the experiments. Hence, data on the normal skeletogenous stages are essential indicators and indispensable parameters to interpret and elucidate the data on the studies of experimental embryology, developmental engineering, and teratological experiments.

Researches have been accumulating on developmental stages of the bones in various avian species such as chicken and quail embryos (4, 11, 16, 21). They usually stain ossification centers of either partial or whole fetal skeletal components to document valuable basic knowledge to the experimental embryology so that related research may be more precise and efficient (5, 8, 11). This research, therefore, reported the ossification and growth of the bones of the thorax in the prehatching period of the Hubbert strain broiler (JV) which gains remarkable weight in a very short period of time. Thus, timing of appearance of the various ossification centers was revealed, pattern of the related bone growth was established, and the data were compared to the literature. The findings may well contribute to the data on normal skeletogenous stages in domestic chickens raised as broiler.

Materials and Methods

Fertilized eggs collected from a local broiler farm unit within 2 h after laying and stored at 15 °C, were put into an incubator (Brinsea Octagon 250, Sandford, England) within 3 days of laying. The temperature and relative humidity of the incubator were adjusted to 37.5±0.2 °C and 71%, respectively. Stages at 24-h intervals were taken to describe the external developmental occurrences of the embryos. A number of 10 embryos were prepared every 24 h from 10 to 20 days of incubation, so a total of 110 embryos were searched. The external description was evaluated in accordance with the data of Hamburger and Hamilton, 1951.

The embryos were fixed in 10% formaldehyde then 95% ethanol solutions. Subsequently, they were cleared and the skeletons of the embryos were stained *in toto* with Alcian blue (C.I 74240, Merck, Darmstadt, Germany) and alizarin red (C.I 58005, Merck Darmstadt, Germany) for cartilage and ossified components, respectively. The staining technique was modified from Peters, 1977 (18) and Nakane and Tsudzuki, 1998 (12), which dyes the cartilaginous tissue blue and the osseous tissue red. The technique displays the development of the cartilaginous components and localization of the early centers of the ossification areas in the bones.

Ossification centers were observed under a stereoscopic microscopy (Olympus Optical Co. Ltd. Tokyo. No: 20326), paying particular attention to the timing of chondrofication and ossification. Bone nomenclature was based on that described by Nomina Anatomica Avium 1993 (13).

Results

On the day 10, there was no red color staining in the ribs, indicating no ossification center even though hardly visible indistinct ossification areas were present in the dorsal 1/3 of the 4th and 5th vertebral ribs in one individual. Adversely, a number of three blue color staining areas demonstrating chondrotic tissue drafts were observed in the uncinat processes between the 2nd and 3rd, 3rd and 4th, 4th and 5th ribs. No fusion was seen between the chondrotic drafts of the sternal ribs and sternum.

On the day 11 (Fig. 1/A), red colored ossification centers were observed in the chondrotic drafts of the 3rd, 4th, 5th, and 6th vertebral ribs. Again, no fusion was yet observed between the chondrotic drafts of the sternal ribs and sternum. The chondrotic drafts of the uncinat processes between the 2nd and 3rd, 3rd and 4th, 4th and 5th ribs developed highly even though that between the 5th and 6th did not yet.

On the day 12, ossification began in the last 6 ribs. The chondrotic drafts of the uncinat processes extended proximally. Hence, a chondrotic draft of the 5th rib was appeared. No ossification center was observed in the sternum yet. The thoracic process of the sternum was determined to arise from the chondrotic drafts.

On the day 13 (Fig. 1/B), ossification commenced at the medial region of all the ribs even though it was not seen in the uncinat processes and sternum yet. It progressed and extended to both proximal and distal directions.

On the day 14, ossification was seen in the last 3 sternal ribs while a chondrotic draft was observed in the 1st one. The proximal edges of the chondrotic drafts of the vertebral ribs were divided into two components. The chondrotic drafts of the uncinat processes developed more, lying along the lengths of the sternal and vertebral ribs. They did not attach at least chondrotically to either cranial or caudal vertebral ribs.

The chondrotic drafts of the thoracic and caudal lateral processes of the sternum were present, and there was a clear ossification area where the sternum and coracoid bone articulated.

On the day 15 (Fig.1/C), the first 4 sternal ribs began ossifying. Very large chondrotic drafts were observed in the junction of the sternal and vertebral ribs. They were larger as located caudally, and were later joined the sternal ribs. At the same time, the divided chondrotic drafts of the vertebral ribs also began ossifying.

A rectangular ossification center was observed on the dorsal aspect of the carina of the sternum. Interestingly, another center was also present in the lateral caudal process of the sternum.

On the day 16, ossification started in the middle of the first 4 uncinat processes. They were attached loosely by a triangle chondrotic tissue to vertebral rib.

Ossification began also in the thoracic and lateral cranial processes before completion of the ossification in the body of the sternum. Most of the sternum was still a chondrotic draft. The ossified parts of the thoracic and lateral caudal processes were determined to fuse.

On the day 17, ossification centers in the uncinat processes of the 2nd, 3rd, 4th, and 5th ribs were apparent, continuing to develop. The ossification center in the dorsal aspect of the carina of the sternum was also prominent.

On the day 18 (Fig.1/D), a “V” shape ossification area was determined in the junction between the thorax and lateral caudal process.

On the day of 19, ossification areas in the sternal and vertebral ribs further extended both proximally and distally, and the lengths of the ribs increased. Likewise, the uncinata processes continued ossifying at both directions.

On the day of 20 (Fig. 1/E), the previously seen ossification area in the body of the sternum became very prominent. There were two more ossification centers observed in the junction between the sternum and coracoid bone. All the ossification centers that occurred in all the bones, resembled those of the gross structural shapes of the mature stages. Hereafter, the ossified components of the observed bones continued to develop until the 21st day of incubation when the hatching happened.

Discussion

Figure 1 photographically displays the timing of ossification in the ribs and sternum of the Hubbert strain broiler. Ossification pattern was equal bilaterally with time increase. As expected, the first ossification areas appeared on the 11th day of incubation in the medial region of the ribs and progressed to the proximal and distal regions, which coincides with the accumulating data (9, 10, 11). Literature reports indicate that ossification in the sternum of the avian species occurs at the later stage of development (1, 2, 11). Interestingly, ossification begins in the latero-caudal and latero-cranial processes of the sternum, and completion of the ossification of the body of the sternum occurs at and after hatching. It was also observed in this study that ossification in these processes began on the 14th day of incubation, and continued through hatching.

It has been well documented that birds display different postnatal growth rates, i.e. altricial species show higher postnatal growth rates than precocial birds do (1, 19). It is directly related to the degree of precocity of the new born chick. Altricial species experiencing higher postnatal growth rates allocate such rates particularly to rapid development of supply organs of the digestive trunk. The early fast development of these organs is at the expense of growth directed to demand organs such as muscles and skeletal features. Growth pattern of the components of the ribs and sternum in avian species also varies significantly (9, 10, 11). This system including ribs and sternum shows in general latest appearance of ossification as compared to those of skull, vertebrae, and forelimb and hindlimb. This was also the case in our study.

The growth rate differs significantly also among the different bones of the same individual (1, 2, 4, 5). There is a significant increase during the first few days of the development in the cartilaginous and ossified components of the bones. The development of the ossification continues throughout the hatching while that of the cartilaginous parts displays a plateau, followed by a steady decrease. This study focused only on the changes of the ossification. The ossification in the ribs and sternum began later and seemed to display a steady increase through the hatching.

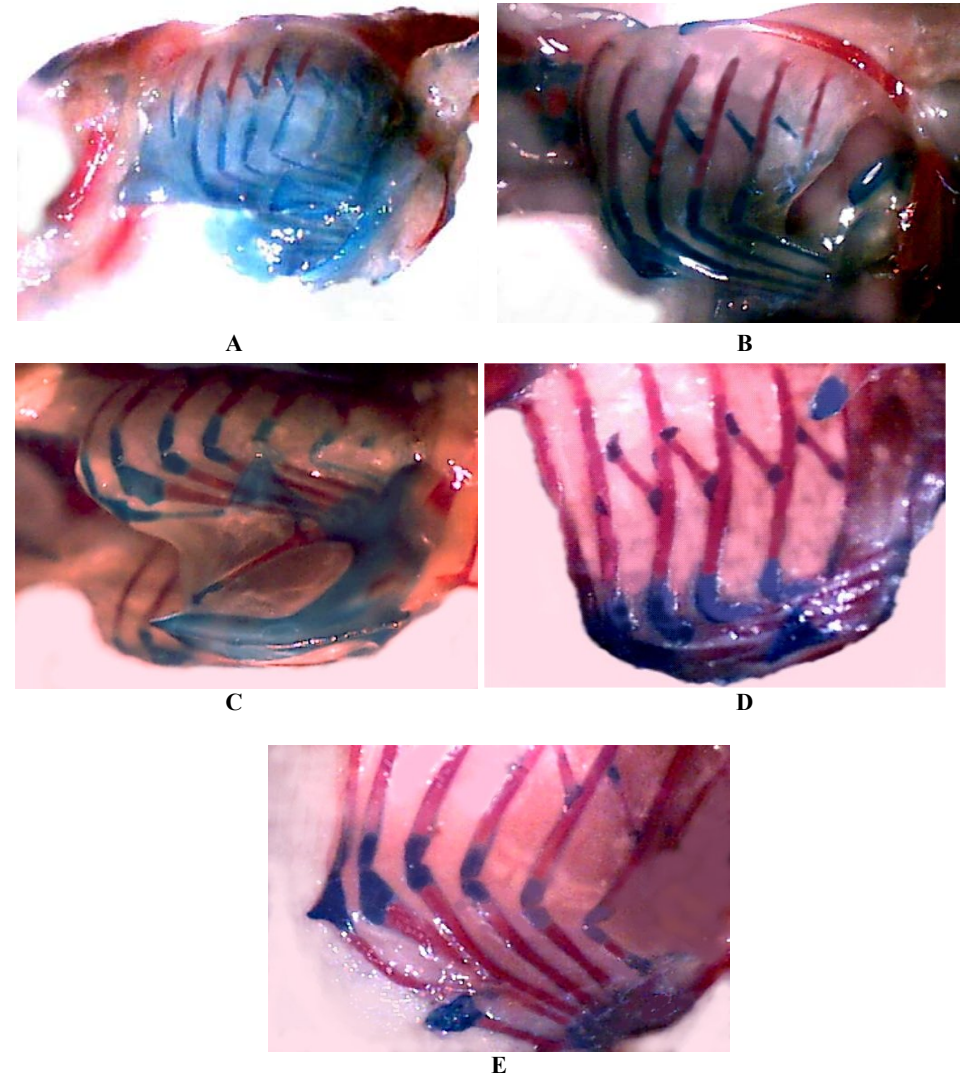


Fig. 1: Skeletal features of the thorax of the Hubbert strain broiler at various days of incubation. Detail explanations are in the text. (A), (B), (C), (D), (E) of 11th, 13th, 15th, 18th, 20th days of incubation.

Şekil 1: Hubbert ırkı broylerlerde inkubasyonun çeşitli günlerinde sternum ve kostaların kemiksel gelişimi. Detaylı bilgi metin içinde verilmiştir. A, inkubasyonun 11. gününü; B, 13. günü; C, 15. günü; D, 18. günü ve E, 20. gününü göstermektedir.

Chondrification and calcification usually begin from different regions of the skeletal system. Reports mentioned that they usually occurred in the medial region and progressed to the proximal and distal regions in the ribs (5, 11). They also indicated that the uncinat processes of the ribs in the Japanese quail appeared as cartilage tissue then ossified while those of the chicken were directly calcified without any chondrification. On the contrary, we observed in this study that the uncinat processes of the ribs in this study showed very early chondrification and ossification.

References

1. **Blom, J. and Lilja, C.:** A comparative study of embryonic development of some bird species with different patterns of postnatal growth. *Zool.* 2005; 108: 81-95.
2. **Blom, J. and Lilja, C.:** A comparative study of growth, skeletal development and eggshell composition in some species of birds. *J. Zool.* 2004. (London). 262: 361-369.
3. **Etches, R.J., Carsience, R.S., Clark, M.E., Fraser, R.A., Toner, A., Verrinder Gibbins, A. M.:** Chimeric chickens and their use in manipulation of the chicken genome. *Poult. Sci.* 1993; 72: 882-889.
4. **Hamburger, H. and Hamilton H.L.:** A series of normal stages in the development of the chick embryo. *J. Morphol.* 1951; 88: 49-92.
5. **Hamilton, H.L.:** Lillie's development of the chick: An introduction to embryology. Holt, Rinehart, Winston, New York. 1952.
6. **Hashizume, R., Noda, A., Itoh, M., Yamamoto, Y., Masui, S., Oka, M.:** A method for detecting malformations in chicken embryos. *Jap. Poult. Sci.* 1993; 30: 298-305.
7. **Hashizume, R., Noda, A., Itoh, M.:** Studies on teratological testing using chicken embryos: effects of solvents, injection sites and the age of the embryo. *Exp. Anim.* 1992; 41: 349-356.
8. **Jollie, M. T.:** The head skeleton of the chicken and remarks on the anatomy of this region in other birds. *J. Morphol.* 1957; 100: 389-436.
9. **Lilja, C., Blom, J., Marks, H.L.:** A comparative study of embryonic development of Japanese quail selected for different patterns of postnatal growth. *Zool.* 2001; 104: 115-122.
10. **Naito, M., Nirasawa, K., Oishi, T.:** Development in culture of the chick embryo from fertilized ovum to hatching. *J. Exp. Zool.* 1990; 254: 322-326.
11. **Nakane, Y. and Tsudzuki, M.:** Development of the skeleton in Japanese quail embryos. *Dev. Grow. Differ.* 1999; 41: 523-534.
12. **Nakane, Y. and Tsudzuki, M.:** Morphological and genetic studies for a new morphometric mutant of Japanese quail. *Proceedings, 6th Asian Pacific Poultry Congress*, 1998; 242-243.
13. **Julian J.B.:** *Nomina Anatomica Avium, Handbook of Avian Anatomy* Cambridge, Massachusetts. Published by The Nuttall Ornithological Club. No: 23, 1993.

14. **Ono, T., Matsumoto, T., Arisawa, Y.:** Production of donor-derived offspring by transfer of primordial germ cells in Japanese quail. *Exp. Anim.*, 1998; 47: 215-219.
15. **Ono, T., Murakami, T., Mochii, M.:** A complete culture system for avian transgenesis, supporting quail embryos from the single-cell stage to hatching. *Dev. Biol.* 1994; 161: 126-130.
16. **Padgett, C.S. and Ivey, W.D.:** The normal embryology of the coturnix quail. *Anat. Rec.* 1960; 137: 1-11.
17. **Perry, M.M.:** A complete culture system for the chick embryo. *Nature*, 1988; 331, 70-72.
18. **Peters, P.W.J., Neubert, D., Merker, H. J., Kwasogroch, T. E.:** Double staining of foetal skeletons for cartilage and bone. *Methods in prenatal toxicology.* George Thieme, Stuttgart, 1977.
19. **Ricklefs, R.E., Starck, J. M., Konarzewski, M.:** Internal constraints on growth in birds. *Avian growth and development. Evolution within the altricial-precocial spectrum.* pp. 266-287. In: Stack, J. M., Ricklefs, R. E. (eds.), Oxford University Press., Oxford. 1998.
20. **Tsudzuki, M., Nakane, Y., Wada, A.:** Hereditary multiple malformation in Japanese quail: A possible powerful animal model for morphogenetic studies. *J. Hered.*, 1998; 89: 24-31.
21. **Zacchei, A.M.:** Lo sviluppo embrionale della guaglia giapponese. *Arch. It. Anat. Embriol.* 1961; 66: 36-62.