

Evaluation of ST-Segment Duration and Morphology of Standard Base Apex Lead Electrocardiograms in Different Age Groups of Apparently Healthy Holstein Cattle

Mehrdad POURJAFAR^{1*}, Khalil BADIE¹, Aliasghar CHALMEH¹

¹Large Animal Internal Medicine, Department of Clinical Sciences, School of Veterinary Medicine, Shiraz University, Shiraz, Iran

*Corresponding Author: Mehrdad POURJAFAR Large Animal Internal Medicine, Department of Clinical Sciences, School of Veterinary Medicine, Shiraz University, P.O box: 71345, Shiraz, Iran
e-mail: dmp4m@yahoo.com, Tel: +98 711 6138700

Geliş Tarihi /Received: 18.04.2011

ABSTRACT

The present study was conducted to obtain electrocardiographic data regarding the values of ST-segment morphology and duration from 84 apparently healthy Holstein cattle in fourteen different age groups from newborn to 7 years old. We recorded electrocardiograms in standard base apex lead system with the paper speed 25 mm/sec. and calibration of 10 mm equal to 1 mV. The morphologic assessments of electrocardiograms showed that all groups had normal isoelectric ST-segment, except newborns. Elevation of ST-segment was detected in 64.2% of newborn calves. The magnitude of this up sloping was 0.10 ± 0.03 mV. The results of the comparison of ST-segment duration among different age groups showed that there were significant differences between the ST-segment duration of newborns (0.11 ± 0.02 , sec) and 5 years old (0.16 ± 0.03 , sec.), and also between 15 days (0.09 ± 0.03 , sec.) and 5 years old ($P < 0.05$). The results of the present study may be accepted as normal ST-segment duration and morphology in different age groups of healthy Holstein cattle which will provide a good basis for judging and interpreting electrocardiograms.

Key Words: Electrocardiography, ST-segment, morphology, Holstein cattle

ÖZET

FARKLI YAŞ GRUPLARINDA SAĞLIKLI OLARAK GÖZLENEN SİYAH ALACA SIĞIRLARDA BASE APEKS DERİVASYONUNDAKİ STANDART ELEKTROKARDİYOGRAMDA ST SEGMENT ARALIĞININ VE MORFOLOJİSİNİN DEĞERLENDİRİLMESİ

Bu çalışmada yeni doğandan 7 yaşına kadar 14 farklı yaş grubunda bulunan 84 adet sağlıklı Siyah Alaca sığırda ST segment morfolojisi değerlerine ait elektrokardiyoğrafik verilerin elde edilmesi amaçlanmıştır. Elektrokardiogramlar standart base apeks derivasyon sisteminde, 25mm/sn kağıt hızında ve 1mV'ye eşit 10mm kalibrasyonda kayıt edilmiştir. Elektrokardiogramların morfolojik değerlendirilmesi sonucunda yeni doğanlar haricinde tüm grupların normal izoelektrik ST segmentine sahip oldukları gözlenmiştir. Yeni doğanların %64,2'sinde ST segmentinde yükselme tespit edilmiştir. Bu yükselme miktarının eğimi $0,10 \pm 0,03$ mV olarak saptanmıştır. ST segment aralığının farklı yaş grupları arasında karşılaştırılması sonucu; yeni doğanlar ($0,11 \pm 0,02$ sn) ile 5 yaşındakiler ($0,16 \pm 0,03$ sn) ve

15 günlük ($0,09 \pm 0,03$ sn) ile 5 yaşındakiler arasında önemli bir farklılık belirlenmiştir ($P < 0,05$). Bu çalışmanın sonuçları, farklı yaş gruplarındaki sağlıklı Siyah Alaca sığırlarda ST segment aralığı ve morfolojisi normal olarak kabul edilerek, elektrokardiyogramların değerlendirilmesi ve yorumlanmasında iyi bir kaynak oluşturacaktır.

Anahtar Kelimeler: Elektrokardiyografi, ST-segment, morfoloji, Siyah Alaca sığır

Introduction

Electrocardiography is a noninvasive, inexpensive technique that yields useful information in classification of arrhythmias, diagnosing conduction abnormalities and it also is a valuable aid in prognostic and therapeutic considerations (Rezakhani and Papahn, 2002). The electrocardiogram (ECG) provides a record and measure of the time varying potential difference that occurs over the surface of the body as the result of electrical activity within the heart. This is associated with depolarization and repolarization of the myocardium that occurs in a definite pattern and sequence and then the ECG can be used to measure and time these events (Radostits et al., 2007). No single electrocardiographic lead system has been universally accepted for use in large animals. Bipolar leads (I, II, III, base-apex, X, Y and Z of the orthogonal lead system) and unipolar leads (aV_F , aV_R , aV_L , thoracic) have been described, but the amplitude, duration and configuration of the different wave forms vary widely, depending on an animal's breed, size, body type and sex. The lead system should be easy to apply and the tracing free of artifacts created by muscle tremors, skin movements, shifting of weight and change in limb position. For this purpose a single-channel machine can be used and the lead system chosen can be any that generates distinctive P, QRS and T complexes (Reef and McGuirk, 2009). Base apex lead have been used for large animals and it is shown to be an appropriate lead and ECGs recorded in this lead has clear and large waves and complexes and animal movement has a minimum effect on the recording (Deroth, 1980; Radostits et al., 2007; Santamarina et al., 2001). The potential use of electrocardiography in cattle is well recognized (Deroth, 1980). Evaluation of ST-segment in human is one of the diagnostic parameters in some of the cardiac (Ha'ggmark et al., 2005) and non-cardiac

(Gertsch, 2009) problems. The ST-segment connects the QRS complex and the T wave (Gertsch, 2009). Elevation and depression of this segment in human beings represent the disorders such as ischemia and infarction, electrolyte imbalances, conduction abnormalities, cardiac cavities and valves problems (Gertsch, 2009; Ha'ggmark et al., 2005). Knowledge of morphology of ST-segment may help veterinarians to detect some of the patient problems from the observation of ECGs. There is some information on ST-segment duration of bovine ECG (Deroth, 1980; GhiŃă et al., 2008b; Mendes et al., 2001). But the comprehensive information on ST-segment morphology was lacking. The present study was undertaken to record ECGs in different age groups, from neonates to 7 years old apparently healthy Holstein cattle, in order to provide useful information on normal ST-segment duration and morphology in base apex lead system of this breed.

Materials and Methods

The present study was carried out from July 2009 till February 2010 on 84 apparently healthy Holstein cattle around Shiraz (latitude $29^{\circ}33'N$ and longitude $052^{\circ}36'E$, 1486 m above sea level), southwest Iran. The animals were assigned into 14 groups, comprising newborn calves (18 to 72 hours), 15 days, 1, 2, 3, 6, 9 and 12 months and 2, 3, 4, 5, 6 and 7 years old. There were 6 animals in each study group. The animals were examined prior to ECG recordings and were proved to be clinically healthy. None of the animals used in this study had any clinical signs of heart diseases (edema, jugular distension or pulsation). The ECGs were recorded on a bipolar base apex lead, using limb lead I. Animals were kept in a standing position in a stock without sedation and minimal restraint. No clipping or shaving

was carried out for electrode attachment. When the animals were thought to be in a quiet state, the ECGs were recorded, using alligator-type electrodes which were attached to the skin after cleaning it with ethanol and applying electrocardiographic jelly. The positive electrode (left arm) of lead I was attached to the skin of the left thorax at the fifth intercostal space, immediately caudal to the olecranon, and the negative electrode (right arm) was placed on the jugular furrow in the caudal third of the left neck (Radostits et al., 2007). All ECGs were obtained on a single channel electrocardiographic machine (Kenz-line EKG 110, Suzuken Co., Ltd., Japan) with the paper speed 25 mm/sec. and calibration of 10 mm equal to 1 mV. Duration and morphology of the ST-segment were assessed from successive beats following the usual conventions. The precision of duration was 0.02 sec. and amplitude was 0.05 mV. The P wave, QRS complex and T wave are the recognizable deflections of the ECG tracing and indicate atrial depolarization (P), ventricular depolarization (QRS), and ventricular repolarization (T). The ST-segment is the portion of the tracing falling between the QRS complex and the T wave. During this time, the ventricle is contracting, but no electricity is flowing. The ST-segment is therefore usually even with the baseline (line drawn from P start to T end). It represents the

period of slow repolarization of the ventricles. ST-segment may be horizontal, elevated or depressed (Gertsch, 2009). Mean and standard deviation (SD) were calculated for ST-segment duration in different age groups. The comparison of this parameter in each group, with the same parameter in other age groups was analyzed by the one way ANOVA, using SPSS software (SPSS for Windows, version 11.5, SPSS Inc, Chicago, Illinois). For the purpose of this article, a p-value of less than 0.05 was considered statistically significant.

Results

The standard electrocardiographic ST-segment duration (Mean±SD) of base apex lead in different age groups was shown in Tables 1 and 2. The results of the one way ANOVA of ST-segment duration among different age groups showed that there were significant differences between the ST-segment duration of newborns (0.11±0.02, sec) and 5 years old (0.16±0.03, sec.), and also between 15 days (0.09±0.03, sec.) and 5 years old (P<0.05; Figure 1). The morphologic assessments of ECGs showed that all groups had normal isoelectric (horizontal) ST-segment, except newborns. Elevation of ST-segment (Figure 2) was detected in 64.2% of newborn calves (0.10±0.03 mV).

Table 1. Mean±SD of ST-segment duration (second) in base apex lead system electrocardiography of apparently healthy Holstein calves lesser than 12 months old.

Tablo 1. 12 aylık yaştan daha genç sağlıklı Siyah Alacaların standart base apex derivasyon sistemi elektrokardiyografisindeki ST segment aralığının (saniye) ortalama ± SD.

Ages (days)	≤3	15	30	60	90	180	270
ST-segment duration	0.16±0.02	0.11±0.03	0.13±0.03	0.14±0.05	0.13±0.04	0.09±0.02	0.11±0.03

Table 2. Mean±SD of ST-segment duration (second) in base apex lead system electrocardiography of apparently healthy Holstein cattle aged between 1 to 7 years old.

Tablo 2. 1 ile 7 yaş arasındaki sağlıklı Siyah Alacaların standart base apeks derivasyon sistemi elektrokardiyografisindeki ST segment aralığının (saniye) ortalama ± SD.

Ages (years)	1	2	3	4	5	6	7
ST-segment duration	0.16±0.01	0.15±0.02	0.16±0.01	0.15±0.04	0.16±0.03	0.13±0.02	0.16±0.07

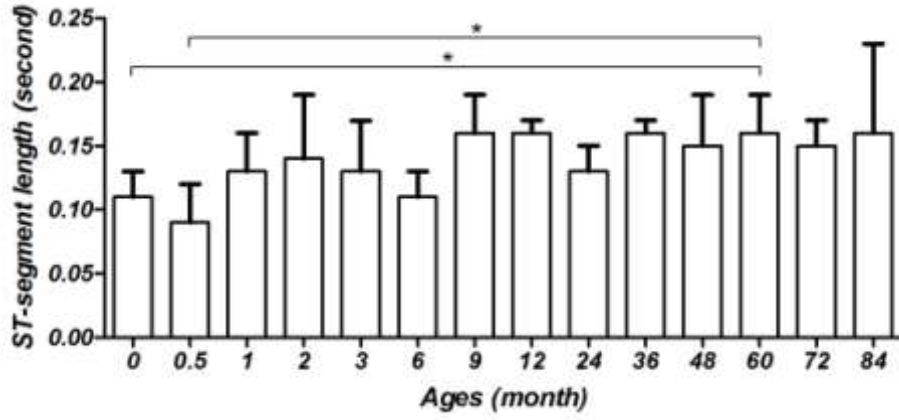


Figure 1. Mean±SD of ST-segment duration in different ages of apparently healthy Holstein cattle in base apex lead electrocardiography. Significant differences between different age groups are shown by (*) ($P<0.05$).

Şekil 1. Farklı yaşlardaki sağlıklı Siyah Alacaların standart base apeks derivasyon sistemi elektrokardiografisindeki ST segment aralığının (saniye) ortalama ± SD. Önemli olarak bulunan farklar (*) ile gösterilmiştir.

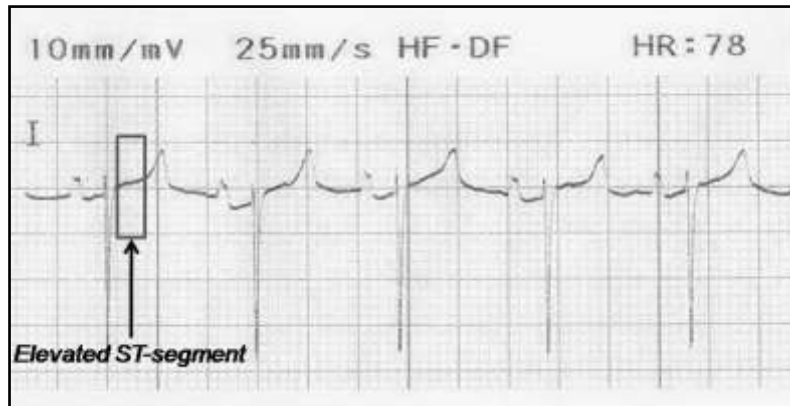


Figure 2. Elevation of ST-segment in electrocardiogram tracing from a newborn healthy Holstein calf (base apex lead, paper speed 25 mm/sec, sensitivity 10 mm/mV).

Şekil 2. Yeni doğan sağlıklı bir Siyah Alaca buzağıdan çekilen elektrokardiogramda ST segmentinin yükselmesi (base apeks derivasyonu, kağıt hızı 25mm/sn, hassasiyet 10mm/mV).

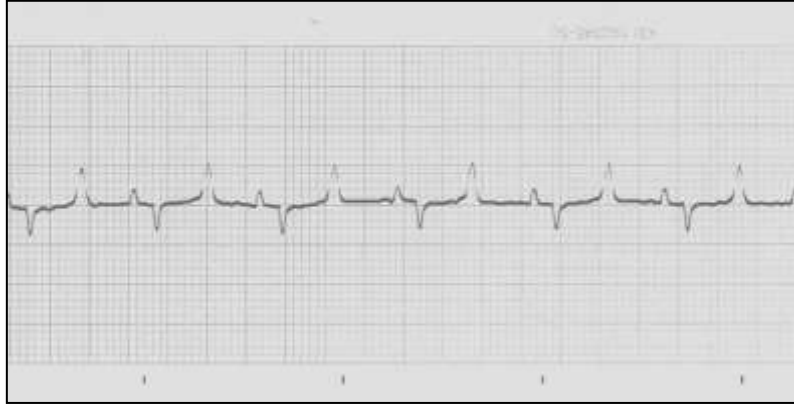

Figure 3. Horizontal ST-segment in electrocardiogram tracing from a 5 year old apparently healthy Holstein cattle (base apex lead, paper speed 25 mm/sec, sensitivity 10 mm/mV).

Şekil 3. 5 yaşında sağlıklı olarak gözlenen bir Siyah Alaca sığırdan çekilen elektrokardiyogramda horizontal ST segmenti (base apeks derivasyonu, kağıt hızı 25mm/sn, hassasiyet 10mm/mV).

Discussion

Electrocardiography is the clinical method of choice to evaluate cardiac problems associated with the initiation and conduction of waves of depolarization and repolarization (Santamarina et al., 2001). Compared with the numerous data available in the equine and especially the canine species, bovine electrocardiography has been scarcely touched and little information is available on electrocardiography in ruminants (Santamarina et al., 2001). The basic parameters of the standard bovine ECG which could be used as reference values are available in the consulted literature (Deroth, 1980; GhiNă et al., 2008a; Rezakhani and Moafpourian, 1993; Rezakhani et al., 2004). We did not find any report considering the assessment of ST-segment morphology.

The conductive properties of the body mass of ruminants, attributable to the volume of the gastrointestinal tract, also influence the distribution of body surface potentials comprising the ECG (Santamarina et al., 2001). This may explain the differences among different ST-segment duration between the calves and adult cows in our study (Figure 1). The results of the present study showed that ST-segment duration in 5 years old cattle was

significantly higher than newborn and also 15 days old calves (Figure 1). The length of the ST-segment shortens with increasing heart rate (Milhorn, 2008) and since the heart rate of calves is higher than adult cows, the duration of ST-segment in calves is shorter than adults.

The base apex lead appears to be most useful in measuring conduction times (i.e., durations of component deflections, intervals, and segments) because the origins and terminations of deflections could be identified easily (Santamarina et al., 2001). It seems that our study on ST-segment duration may be helpful in standardizing base apex lead in Holstein cattle of various ages. It has been reported that the base apex lead gave the least variable ECG tracings in all the animals; however, electrocardiography in larger ruminants such as cattle has shown greater values for duration of electrocardiographic parameters (Santamarina et al., 2001).

It may be proposed that as the mass of the heart in animals becomes larger in the process of growth, the duration of transfer of cardiac electrical activity also increases. The morphologic assessments of ECGs showed that all groups had normal isoelectric (horizontal) ST-segment (Figure 3), except newborns. Elevation of ST-segment (Figure 2) was

detected in 64.2% of newborn calves. Upward or downward shifts in the ST-segment are extremely important; elevation of the ST-segment from baseline in human beings, can indicate acute myocardial infarction, hyperthyroidism, left ventricular aneurysm, myocardial contusion, pericarditis and electrolyte imbalances (Gertsch, 2009; Haaggmark et al., 2005). Elevation of ST-segment in newborn calves may be explained by the electrolyte imbalances due to acidosis from parturition (Radostits et al., 2007). Hyperkalemia is a common problem associated with the acid-base and electrolyte disturbances that occur in neonatal calves having dystocia (Nagy, 2009). In human beings, hyperkalemia is also well recognized as a cause of ST-segment elevation (Wang et al., 2003). In some healthy young adult humans, a form of ST-segment elevation can be normal (Wang et al., 2003). Furthermore, abnormality of electrolytes may also affect the ST-segment length; however measurement of the length of the ST-segment alone is usually not of any clinical use. It has been stated that neonatal calf diarrhea may occur in dairy and beef herds. Many cases of diarrheic calves experience hyperkalemia in the course of the disease (Berchtold, 2009) and ST-segment elevation may be seen.

The results of the present study showed that the value of ST-segment duration in base apex lead of 5 years old Holstein cattle was 0.16 ± 0.03 sec. However, the magnitude of this parameter in adult Holstein cattle, reported by other researcher was 0.12 ± 0.02 sec. in base apex (Deroth, 1980) and 0.20 ± 0.00 sec. in Dubois leads (Ghiňă et al., 2008b). Mean of the ST-segment length in our study was 0.11 ± 0.02 sec. in newborns. However, the magnitude of this parameter in newborn calves, reported by other researcher in different leads, other than base apex, was 0.12 ± 0.02 sec. (standard bipolar, augmented unipolar and unipolar chest leads) (Mendes et al., 2001) and 0.11 ± 0.00 sec. (3 bipolar and 3 unipolar leads) (Ghiňă et al., 2008a). The results of the present study showed that Mean of ST-segment duration was 0.13 ± 0.03 sec. in 1 month old calves. Mendes et al. (2001) reported a level of 0.13 ± 0.02 sec.

for ST-segment duration in 1 month old Holstein calves in other leads than base apex (standard bipolar, augmented unipolar and unipolar chest leads).

There are independent studies which covered the normal ST-segment duration in healthy calves (Ghiňă et al., 2008a; Mendes et al., 2001) and adult cows (Deroth, 1980; Ghiňă et al., 2008b). The present study incorporated both Holstein calves and adult cows in a single comprehensive study in fourteen age groups to specifically clarify the ST-segment length differences. It seems that our data will provide a good basis for judging the ST-segment length and morphology of different age groups of Holstein cattle.

Acknowledgements

The authors would like to sincerely thank Dr. Amin Tamadon and Mr. Reza Chalmeh for statistical analysis of our data.

REFERENCES

- Berchtold, J., 2009.** Treatment of calf diarrhea. In: Intravenous Fluid Therapy. Veterinary Clinics of North America: Food Animal Practice 25, 73-99.
- Deroth, L., 1980.** Electrocardiographic parameters in the normal lactating Holstein cow. Canadian Veterinary Journal 21, 271-277.
- Gertsch, M., 2009.** Electrolyte imbalance and disturbances, In: The ECG Manual: An Evidence-Based Approach. Springer, pp. 177-190.
- Ghiňă, M., Cotor, G., Brăslasu, C., 2008a.** The values of ECG parameters in newborn calves. Bulletin UASVM, Veterinary Medicine 65, 473.
- Ghiňă, M., Cotor, G., Brăslasu, C., 2008b.** The values of some ECG components in dairy cows, using Dubois leads. Bulletin UASVM, Veterinary Medicine 65, 474.
- Haaggmark, S., Haney, M.F., Jensen, S.M., Johansson, G., Naöslund, U., 2005.** ST-segment deviations during pacing-induced increased heart rate in patients without coronary artery disease. Clinical Physiology and Functional Imaging 25, 246-252.

- Mendes, L.C.N., Camacho, A.A., Alves, A.L.G., Borges, A.S., Souza, R.C.A., Ferreira, W.L., 2001.** Standard electrocardiographic values in Holstein calves. *Arquivo Brasileiro de Medicina Veterinária e Zootecnia* 53, 641-644.
- Milhorn, H.T., 2005.** The electrocardiogram. In: *Electrocardiography for the Family Physician, the Essentials*. Brown walker press 11.
- Nagy, D., 2009.** Resuscitation and critical care of neonatal calves. *Veterinary Clinics of North America: Food Animal Practice* 25, 1-11.
- Radostits, O.M., Gay, C.C., Hinchcliff, K.W., Constable, P.D., 2007.** Diseases of the cardiovascular system, In: *Veterinary Medicine: A Text Book of the Diseases of Cattle, Horses, Sheep, Pigs and Goats*. 10th ed., Elsevier, pp. 399-438.
- Reef, V.B., McGuirk, S.M. 2009.** Diseases of the cardiovascular system, In: *Smith BP, Large Animal Internal Medicine*. 4th ed., Elsevier, pp. 453-489.
- Rezakhani, A., Moafpourian, A., 1993.** Studies on the electrocardiographic parameters of dairy cattle (Holstein). *Journal of Veterinary Faculty, University of Tehran* 47, 23-33.
- Rezakhani, A., Papahn, A.A., 2002.** Study on the prevalence of cardiac arrhythmias in dairy calves. *Iranian Journal of Veterinary Research* 3, 257-262.
- Rezakhani, A., Papahn, A.A., Shekarfroush, S., 2004.** Analysis of base apex lead electrocardiograms of normal dairy cows. *Veterinarski Arhiv* 75, 351-358.
- Santamarina, G., Espino, L., Suarez, L.M., 2001.** Electrocardiographic parameters of free-ranging roe deer (*Capreolus capreolus*). *Journal of Zoo and Wild Life Medicine* 32, 441-446.
- Wang, K., Asinger, R.W., Marriott, H.J.L., 2003.** ST-segment elevation in conditions other than acute myocardial infarction. *The New England Journal of Medicine* 349, 2128-2135.