

Mediastinal Neurenteric Cyst in a Child

Savaş Demirebilek*, Turan Kanmaz**, Muharrem Bitiren***, Selçuk Yücesan**

*İnönü University Faculty of Medicine, Department of Pediatric Surgery, Malatya, Turkey
**Harran University Faculty of Medicine, Department of Pediatric Surgery, Şanlıurfa, Turkey
***Harran University Faculty of Medicine, Department of Pathology, Şanlıurfa, Turkey

Neurenteric cysts are rare, with fewer than 35 cases presented in the literature. We report a case of posterior mediastinal neurenteric cyst in a 3-year-old boy presenting with respiratory distress, fever, and cough. Treatment consisted of excision of the cyst through a right posterolateral thoracotomy. Postoperative course was complicated with chylothorax and treated medically. The embryologic, diagnostic, therapeutic relationships of the case were discussed.

Key Words: Intestinal duplication, Neurenteric cyst, Mediastinal mass

Çocuk Olguda Mediastinal Nöroenterik Kist

Nöroenterik kistler nadirdir, literatürde 35 den az olgu bildirilmiştir. Bu raporda solunum sıkıntısı, ateş ve öksürük şikayetleri ile başvuran 3 yaşındaki bir olguda tespit edilen posterior mediastinal nöroenterik kist olgusu sunulmuştur. Kist sağ postreolateral mediastinal torakotomi sonrası eksize edilerek tedavi edilmiştir. Operasyon sonrası dönem şilotoraks ile komplike olmuştur, şilotoraks medikal olarak tedavi edilmiştir. Çalışmada kistin embriyolojik, tanısal ve tedavi yöntemleri tartışılmıştır.

Anahtar Kelimeler: İntestinal duplikasyon, Nöroenterik kist, Mediastinal kitle

Neurenteric cysts are duplication of the alimentary canal associated with a variety of malformations of the spinal column and cord. We describe a further case of posterior mediastinal neurenteric cyst.

CASE REPORT

A 3-year-old boy with a 7-day history of cough, fever, tachypnea, and a right upper pulmonary mass on plain radiograph of the chest was referred to our clinic for further investigation and treatment. Clinical examination revealed diminished breath sound and crackling rales on the right side. The past history revealed that he had undergone a posterior thoracic meningocele operation on his 6th postnatal day. Chest roentgenograms and CT showed a large right posterior cystic mediastinal mass (6x8x5 cm in diameter) and vertebral anomaly including scoliosis [Fig. 1A, B, Fig 2]. The mass was not connected to the spinal canal. Preoperative diagnosis of neurenteric cyst was made.

Figure 1. Anterior and lateral plain films of chest showing a large, right posterior mediastinal mass.

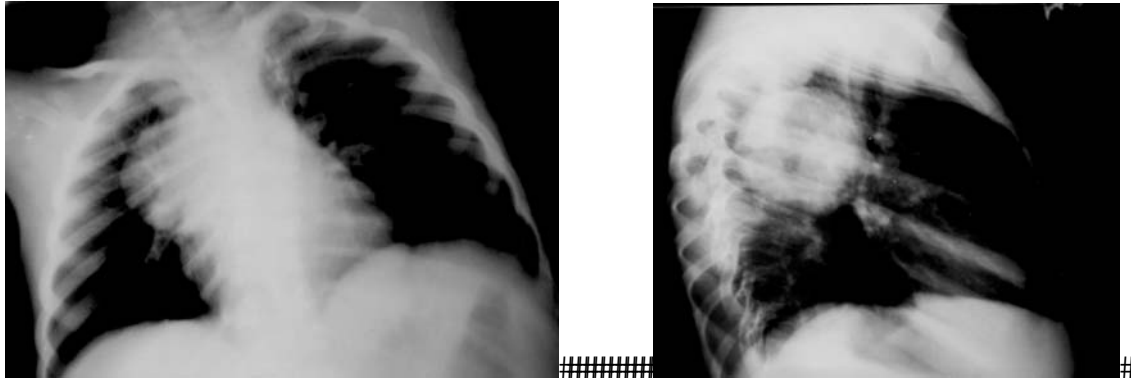
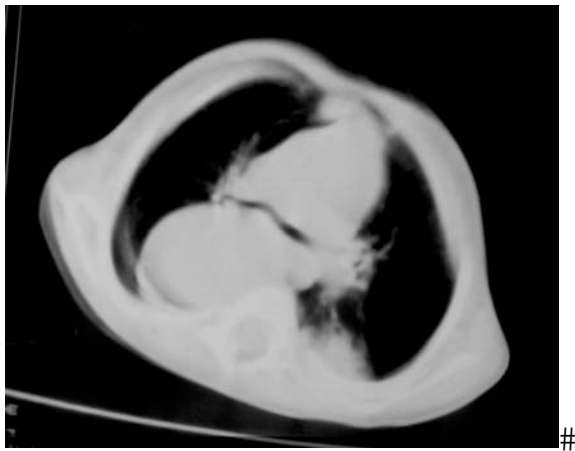


Figure 2. Computed tomography scan showing size and localization of the cystic mass



Immediate therapy included antibiotics and chest physiotherapy. Surgery was performed after the child was stabilised. Through a right 4th intercostal posterolateral thoracotomy, a large spheric shaped cystic structure was found. The cyst occupied the posterior mediastinum and attached to the adjacent structures firmly. Infected material was inspired from the cystic cavity. The mass was excised completely.

The child's recovery was complicated by chylothorax. Duct fistula was treated with TPN and withholding of oral intake for 2 weeks. He was discharged at the fourth post-operative week.

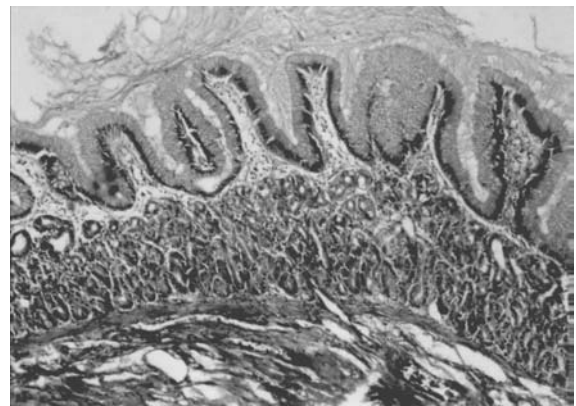
DISCUSSION

Neurenteric cysts are the least common types of the broncopulmonary foregut malformations. The embryologic explanation for these anomalies has become known as the split notochord theory.³ These posterior enteric remnants most likely result from incomplete failure of separation of the notochord from the foregut in the 3rd week of embryogenesis. It was Roth in 1842 who first reported vertebral column attachment to an enteric cyst, but McLetchie, Purves and Saunders coined the term "neurenteric".⁶ The cause of incomplete separation is attributed by Stevenson et al. [3] to an inadequate nutrient supply to the neural folds from avascular abnormality that predated the neural tube closure.

Neurenteric cysts are associated with cervical and upper thoracic abnormalities, such as hemivertebrae, anterior and posterior spina bifida, absence of vertebrae, scoliosis, and diastematomyelia.^{1,2,5,8,10} The cyst can penetrate the diaphragm and communicate with small bowel.^{1,4,5} Posterior thoracic meningocele and scoliosis was noted in our case.

Neurenteric cysts are composed of mucus-secreting columnar epithelium and also may contain areas of gastric glands, parietal cells, and layer of smooth muscle. Gastric mucosa was histologically proven in 60% of patients in one series.¹⁰ As seen in our case, intrathoracic neurenteric cysts are within the mediastinum, 90% located posteriorly, 60% superior to the carina and 66% on the right side.⁷ Microscopic section of cyst wall of our case demonstrated intestinal-like tunica mucosa, submucosa, and muscularis. Mucosal layer contained fundic type gastric glands and parietal cells (Fig. 3).

Figure 3. Histologic appearance of the cyst wall showing tunica mucosa, submucosa and muscularis layer containing fundic type gastric glands and parietal cells.



A clinical triad of respiratory distress, a chest x-ray demonstrating cervical or thoracic vertebral anomalies, and a posterior mediastinal cyst suggest the diagnosis of neurenteric cyst. Neurenteric cyst can present with a wide spectrum of symptoms and can be life-threatening. The most common symptoms were dyspnea, stridor, or persistent cough.^{1,4,5,8,10} When the cyst lined by gastric epithelium haemorrhage, anemia, and pain can be the chief complaints.⁵ More than half of the children with these cysts presents with central nervous symptoms of back pain, sensory or motor deficits, or gait disturbances.¹⁰ Perforation into the pleural cavity may be the initiating clinical event. Paraplegia and death owing to meningitis was presented in one case.¹⁰ These masses occasionally are discovered in asymptomatic children.¹⁰ Respiratory distress, fever and cough were the chief complaints of our case.

The radiological evaluation of neurenteric cysts has evolved with advances in technology. Prior to magnetic resonance imaging (MRI), computed tomographic metrizamide myelography has been the single best diagnostic study in the evaluation of neurenteric cyst.⁵ CT and MRI are precise, and either can define the problem well.

Mediastinal Neurenteric Cyst in a Child

#

The surgery of these lesions is fairly straightforward. If an asymptomatic lesion is discovered, elective excision is recommended unless operative risks are too great. If there are two components of involvement, total excision of neurenteric cyst at one operation can be accomplished. The options for handling the communication with the spinal cord include simple resection of the cyst from the dura with the resultant leak of cerebrospinal fluid into the pleural cavity, or primary closure of the dural defect.⁵ The symptomatic part should be excised first.¹⁰ As seen in our case, these cysts may be infected and excision can be difficult because of attachment to the adjacent structures.

REFERENCES

1. Alrabeeah A, Gillis Da, Giacomantonio M, Lau H. Neurenteric cyst-a spectrum. J Pediatr Surg 1988;23:752-754
2. Beardmore HE, Wigglesworth FW. Vertebral anomalies and alimentary duplication. Pediatr Clin North 1958 Am 5:457
3. Bentley JFR, Smith JR. Development posterior enteric remnants and spinal malformations: the split notochord syndrome. Arch Dis Child 1960;35:76-80
4. Fernandes ET, Custer MD, Burton EM, Boulden TF, Wrenn EL, Whittle AP, Edwards OP. Neurenteric cyst: surgery and diagnostic imaging. J Pediatr Surg 1991;26:108-110
5. Gilchrist BF, Harrison MW, Campbell JR. Neurenteric cyst: Current management. J Pediatr Surg 1990;24:1231-1233
6. McLetchie NGB, Purves JK, Saunders RL de CH. The genesis of gastric and certain intestinal diverticula and enterogenous cysts. Surg Gynecol Obstet 1954;99:135-139
7. Reed JC, Sabonya RE. Morphologic analysis of foregut cyst in the thorax. Am J Roentgenol Radium Ther Nucl Med 1974;120: 851-860
8. Rızalar R, Demirbilek S, Bernay F, Gürses N. A case of a mediastinal neurenteric cyst demonstrated by prenatal ultrasound. Eur J Pediatr Surg 1995;5:177-179
9. Stevenson RE, Kelly JC, Aylsworth AS, Pheloan MC. Vascular basis for neural tube defects: A hypothesis. Pediatrics 1987;80:102-106
10. Superina RA, Ein SH, Humphreys RP. Cystic duplications of the esophagus and neurenteric cysts. J Pediatr Surg 1984;19:527-530

Corresponding Address:

Doç.Dr.Savaş Demirbilek, MD
Assoc. Prof. of Pediatric Surgery
Department of Pediatric Surgery,
İnönü University School of Medicine,
44069, Malatya, Turkey
GSM : 0532 6539699
E-mail : sdemirbilek@inonu.edu.tr

#