

## A Huge Hydatid Cyst of Liver : A Case Report

Adnan Hasanoğlu MD<sup>1</sup>, Ertan Bülbüloğlu MD<sup>1</sup>, Tamer Baysal MD<sup>2</sup>, Mustafa Şahin MD<sup>1</sup>,  
Ertuğrul Ertaş MD<sup>1</sup>

*Hydatid disease of the liver and lungs are both common in Turkey and it's mostly because of Echinococcus granulosus. 32-year-old woman who had a huge hydatid cyst (30x20 cm) of liver is reported since hepatic hydatid cyst rarely grows this much. Obstructive jaundice was the only complication without a bilier communication. Following albendazole treatment for a period of one month, she underwent partial cystectomy and omentoplasty operation. [Journal of Turgut Özal Medical Center 1996;3(2):127-129]*

**Key Words:** Hydatid cyst, liver, complication, treatment

### Dev karaciğer kist hidatiği : olgu sunumu

*Türkiye'de karaciğer ve akciğerlerde kist hidatik hastalığı çok yaygındır ve en çok Echinococcus granulosus ile oluşur. Karaciğerinde, nadiren bu kadar büyük boyuta ulaşan (30x20cm) kist hidatiği olan 32 yaşındaki bayan hasta sunuldu. Bilier ilişkisi olmayan bası nedeniyle gelişmiş sarılık, hastadaki tek komplikasyondur. Bir aylık albendazol tedavisinden sonra parsiyel kistektomi ve omentoplasti operasyonu uygulandı. [Turgut Özal Tıp Merkezi Dergisi 1996;3(2):127-129]*

**Anahtar Kelimeler:** Kist hidatik, karaciğer, komplikasyon, tedavi

Hydatid disease is a common problem in regions where Echinococcosis is endemic. There are two forms of echinococcosis that effect the liver of humans, *Echinococcus granulosus* and *Echinococcus multilocularis*. The latter is rare and forms 1%-2% of all hydatidosis (1).

The definitive hosts are carnivores and rodents, where human and sheep serve as intermediate hosts. The adult tapeworm lives in the intestine of the definitive host. It is as large as 5 mm and consists of a scolex and the proglottides which contain the eggs. The proglottides or eggs are passed in the stools and may contaminate the food and might be ingested by intermediate host. In the intestine of the intermediate host, sheep or humans, the outer layer of the ovum dissolves and becomes larva and penetrates the intestinal wall and reaches

the liver through the portal circulation. In the liver, it may grow to develop into a primary hydatid cyst (2).

The clinical presentations of hydatid disease of the liver are nonspecific. The disease may be symptomless, but chronic right upper quadrant pain with enlargement of the liver is the most common presentation. Although it is uncommon, patients with hydatid disease of the liver may be admitted to the hospital with complications such as rupture of the cyst into the peritoneal cavity, anaphylactic reactions, secondary infection and biliary obstruction with jaundice.

In this study, a huge hydatid disease of the liver complicated by obstructive jaundice without biliary communication is reported.

<sup>1</sup> İnönü University School of Medicine Department of General Surgery, Malatya

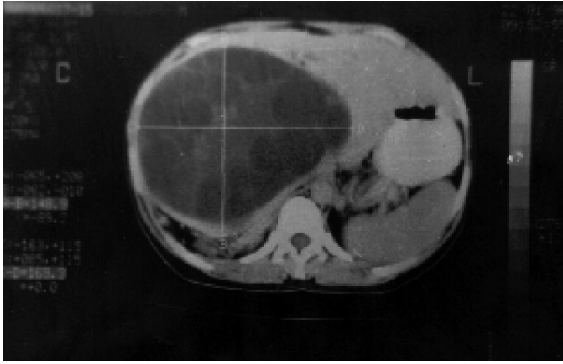
<sup>2</sup> İnönü University School of Medicine Department of Radiology, Malatya

## CASE REPORT

A 32-year-old woman was admitted to the hospital with abdominal pain. Physical examination revealed jaundice and a palpable abdominal mass occupying right hypochondrium and epigastrium. Her sedimentation rate was 56 mm/hr, and liver enzymes were mildly elevated (SGOT 41 IU/L, SGPT 49 IU/L, GAGT 163 IU/L), Alkalen phosphatase was 222 IU/L. Total bilirubin was 3 mg/dl and direct bilirubin was 1.6 mg/dl. Ultrasonography and abdominal Computed Tomography (CT) revealed a 20x30 cm cystic lesion in the liver with septal lobulations and dilatation of the intrahepatic bile ducts. Following antihelminthic drug therapy with daily 800 mg of Albendazole for a period of one month, she underwent cholecystectomy, partial cystectomy and omentoplasty.

## DISCUSSION

Hydatid disease remains to be an important medical problem especially in the sheep-raising regions such as, Australia, New Zealand, South Africa, Far East, Middle East and Mediterranean countries (1). Hydatid disease of the liver and lungs are both common in Turkey and it's mostly



**Figure 1.** Computed tomographic (CT) scan displays a large hydatid cyst in the right hepatic lobe

because of *Echinococcus granulosus*. Hydatid disease incidence in Turkey is 0.002%. Although hydatid disease of the liver is common in Turkey, it rarely grows more than 20 cm in diameter without any complication (3).

The liver hydatid cyst may remain asymptomatic for years or it may be diagnosed due

to its complications such as rupture, infection or systemic hypersensitivity reactions (1,3).

Hydatid immunoelectrophoresis (HEP) and enzyme-linked immunosorbent assay (ELISA) are used in diagnosis. Ultrasonography (US) and computed tomographic (CT) scan appear to be the techniques of choice to diagnose the cyst, to establish relationships between cysts and major biliary or vascular structures and to follow up the patients for recurrence. Endoscopic retrograde cholangio pancreaticography (ERCP) is another method to demonstrate the biliary communications (4).

Although medical treatment of hydatid disease has been used for many years, adequate drug therapy is still lacking. Long-term (one month before operation) or short-term albendazole prophylactic therapy is recommended in order to achieve sterile cysts and reduce the risk of spillage (5).

Uncomplicated cases of liver hydatid disease can be managed successfully by conservative surgery. The methods of surgical treatment of hydatid disease of the liver include evacuation of the cyst with scolicedal irrigation, and either excision or external drainage. The cavity can be reduced by capitonnage, introflection or omentoplasty (6-8).

The adequate radiological evaluation of the biliary system in cases of jaundice is important in the management of these patients, since surgical approach will include exploration and evacuation of the common bile duct in cases of biliary communication. The cyst in the liver, as a mass forming lesion infrequently erodes the adjacent bile ducts and communicates with the biliary system and vesicles in the major bile ducts may cause obstructive jaundice. Jaundice may also be the result of compression of major bile ducts by hydatid cyst as in our patient. The cause of jaundice in our patient was compression of the major bile ducts by hydatid cyst in the liver without any biliary communication and surgical treatment consisted of partial cystectomy and omentoplasty. Cholecystectomy was performed because of close relation and adhesions to the cyst wall.

**REFERENCES**

1. Munzer D. New perspectives in the diagnosis of echinococcus Disease. J Clin Gastroenterol 1991; 13(4):415-23.
2. Hamamcı EO, Ercan F, Özcan B, Berberoğlu M, Korkmaz A. Karaciğer hidatik kistinde cerrahi tedavi. Çağdaş Cerrahi Dergisi 1995; 9: 203-7.
3. Doğan R, Yüksel M, Çetin G, Süzer K et. al. Surgical treatment of hydatid cysts of the lung: Report on 1055 patients. Thorax 1989; 44:192-9.
4. Kumar A, Chattopadhyay TK Management of hydatid disease of the liver. Postgrad Med J 1992; 68, 853-6.
5. Gil-Grande LA, Caaberio FR, Prieto JG, Sanchez-Ruano JJ et. al. Randomised controlled trial of efficacy of albendazole in intra-abdominal hydatid disease. Lancet 1993; 342:1269-72.
6. Mentis A, Yüzer A, Özbal O, Çoker A, Ilter T, Musoğlu A. omentoplasty versus introflexion for hydatid liver cysts. J R Coll Surg. Edinb 1993; 38: 82-5.
7. Dawson JL, Stamatakis JD, Stringer MD, Williams R. Surgical treatment of hepatic hydatid disease. Br J Surg 1988; 75: 946-50.
8. Golematis BC, Peveretos PJ. Hepatic Hydatid disease: current surgical treatment the mount sinai. J Medicine 1995; 62: 71-6.

**Correspondence address:**

Adnan HASANOĞLU, MD

İnönü Üniversitesi Tıp Fakültesi

Genel Cerrahi ABD

Kampüs, MALATYA 44100

**Phone & Fax :** + (422) 341-0565**Email address:** ahasanoglu@ihlas.net.tr