

BILATERAL HYDROURETERONEPHROSIS SECONDARY TO PRIMARY APPENDICEAL ABSCESS: CASE REPORT

Uğur YILMAZ, M.D. *
Oğuz EKMEKÇİOĞLU M.D. **
İbrahim GÜLMEZ, M.D. **

It has been demonstrated that appendiceal abscess could result in urinary obstruction in pediatric patients. The presented case with an appendiceal abscess causing bilateral ureteral obstruction draws attention to the possibility of discovering appendiceal abscess as the primary etiology of bilateral hydronephrosis especially in cases with concomitant intrapelvic mass.

Key words: Appendiceal abscess, appendix vermiformis, intrapelvic mass, hydronephrosis

Primer Apendiks Absesine Bağlı Bilateral Hidroüreteronefroz

Apendiks vermiformis abselerinin pediatrik hastalarda üriner sistem obstrüksiyonu yapabileceği gösterilmiştir. Primer apendiks absesine bağlı intrapelvik kitle nedeniyle gelişen bilateral hidroüreteronefroz olgusu sunulmuştur. Özellikle intrapelvik kitlesi olan bilateral hidronefrozlu pediatrik vakalarda apendiks absesi öntanısının da gözönünde bulundurulması gerekmektedir.

* Inonu University School of Medicine,
Department of Urology
MALATYA
** Erciyes University School of Medicine,
Department of Urology
KAYSERİ

Anahtar kelimeler: Apendiks absesi, apendiks vermiformis, intrapelvik kitle, hidronefroz

Correspondence address:

Uğur YILMAZ, M.D.
Inonu University School of
Medicine, Department of
Urology
MALATYA

Appendicitis is one of the common causes of acute abdomen in emergency departments. Urologists are not usually consulted for appendiceal abscess except for the cases with urinary symptoms. Appendiceal abscesses causing urinary obstruction were first reported by Gerald T. Cook in 1969.¹ Since then, only three cases have been reported to be surgically proven 'primary appendiceal abscess' causing bilateral hydronephrosis. In this report, a case with appendiceal abscess causing bilateral ureteral obstruction is presented.

CASE

A 13-year-old boy presented with abdominal and flank pain lasting for three weeks. The pain had started from the left flank and had spread all the abdomen and the contralateral side. He had significant frequency and nocturia. In the physical examination, he had a fever of 38°C, left costovertebral angle and suprapubic tenderness and voluntary abdominal rigidity. The urinary sediment, the levels of blood urea nitrogen and creatinine were normal.

Intravenous pyelography (IVP) demonstrated bilateral hydronephrosis and an image of pelvic mass compressing the lower parts of ureters and the bladder (Figure 1). Computerized tomography showed 6x6x4cm retrovesical cystic mass (Figure 2). Ultrasonographically, there were bilateral hydronephrosis manifesting more in the left side and a pelvic mass.

The patient was immediately admitted to the hospital; double-J ureteral stents were placed bilaterally; and, empirical antibiotic treatment was initiated. After the stabilization of vital findings, a laparotomy was performed. In the exploration, a fecaloid of 2x1x3cm was found in the abdomen near the perforated appendix vermiformis. After cleaning the inflammatory collection in the pelvis, appendectomy was performed and the ureteral stents were endoscopically removed. The patient had an uneventful recovery. In the third month of follow-up, the control IVP was normal.

DISCUSSION

Appendiceal abscess is usually seen in the pediatric patients. It has been reported that urinary symptoms appear after intestinal symptoms and they may even mislead the physician to a misdiagnosis of a urological disease.¹ In our case, the patient had no abdominal symptoms except for an abdominal pain radiating from the left lumbar region. The complaint of urinary frequency had also

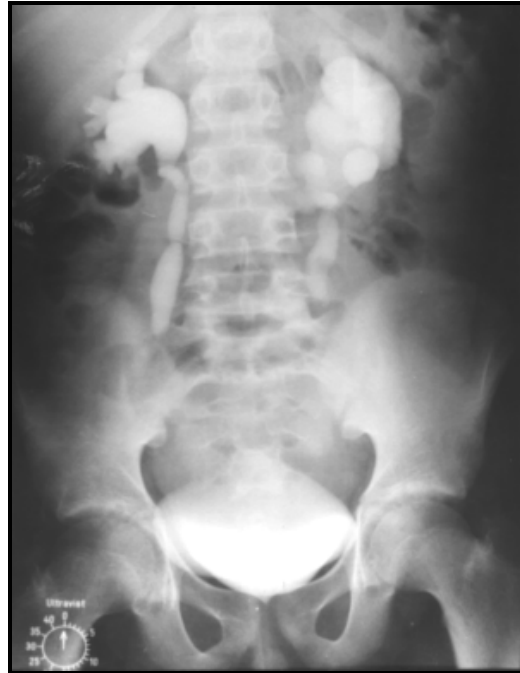

Figure 1. IVP demonstrating a silhouette of pelvic mass compressing the bladder and lower parts of the ureters resulting bilateral hydronephrosis.

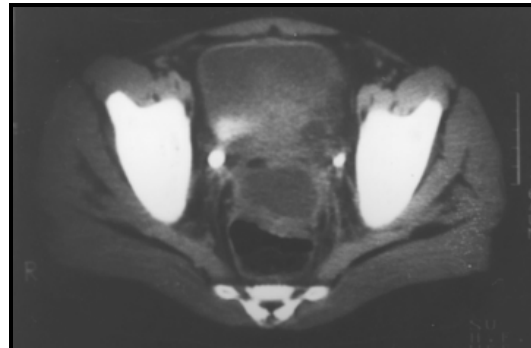


Figure 2. Computerized tomography showing a 6x6x4cm retrovesical cystic mass.

started with the onset of the flank pain. The presence of bilateral hydronephrosis together with cystic pelvic mass in computerized tomography suggested the diagnosis of an infected pelvic mass. Therefore, an elective operation was performed following the clinical healing. If appendiceal abscess had been thought in the differential diagnosis, interval appendectomy would have been the appropriate treatment of choice.²

Bilateral Hydrourteronephrosis Secondary To Primary Appendiceal Abscess: Case Report

Until now, bilateral hydronephrosis secondary to primary appendiceal abscess was reported in five cases who underwent no previous appendectomy procedure.¹⁻⁴ In one of these cases, appendiceal abscess was thought as a differential diagnosis in the excretory urography, but the treatment was not reported.¹ The present case is the fourth 'surgically proven primary appendiceal abscess' causing bilateral hydronephrosis.

REFERENCES

1. Cook GT. Appendiceal abscess causing urinary obstruction. J Urol 1969; 101:212.
2. Tripp BM, Homsy YL, Kiruluta G. Bilateral ureteral obstruction secondary to a perforated appendiceal abscess. J Urol 1995; 154:1158.
3. Sanderman J, Hansen LS. Bilateral ureteral obstruction as a complication to a perforated appendix. Report of a case. Acta Chir Scand 1983; 149:535.
4. Green JT, Pham HT, Hollowell CP, Krongrad A. Bilateral ureteral obstruction after asymptomatic appendicitis. J Urol 1997; 157:2251.