

THE MANAGEMENT OF RENAL CANDIDIASIS IN A NEWBORN INFANT WITH POSTERIOR URETRAL VALVE

Faruk ÖKTEM*, İlmay BİLGE*, İzzet ROZANES**, Sevİnç EMRE*,
Aydın ŞİRİN*, Orhan ZIYLAN***

SUMMARY

Renal candidiasis with fungal bezoars in the newborn infant is rarely encountered. We report a newborn with renal candidiasis and posterior uretral valve treated by local irrigation of the kidneys (three weeks) with amphotericin B via percutaneously inserted nephrostomy catheter, in combination with intravenous flucanazol (four weeks). Renal function subsequently improved and fungal bezoars disappeared sonographically. No side effects were observed during the follow up. We suggest that local irrigation with amphotericin B in combination with systemic flucanazol may be the initial treatment of renal candidiasis, aiming at both the restoration of renal function and the eradication of the fungal infection.

Key words: Renal candidiasis, Posterior urethral valve, Newborn child, Percutaneous nephrostomy, Amphotericin B

INTRODUCTION

Fungal infection of the kidney, particularly with candidal bezoars of the urinary tract is a rare phenomenon among neonates (1,2). Predisposing factors include obstructive uropathy, prematurity, long term in situ catheters, prolonged use of broad-spectrum antibiotics, total parenteral nutrition and the presence of immunosuppressive conditions (2-5). *Candida albicans* is the most common causative organism of mycotic infections, although other *Candida* spp. such as *C. parapsilosis*, *C. tropicalis*, and *C. galabrata* have also been increasingly reported (6,7). Diagnosis of renal candidiasis is based on the history of patient, ultrasound images, urinalysis and eradication. Therapy modalities of renal candidiasis are not well standardized in neonate patients (2,3).

We report a term neonate with posterior urethral valve, urinary tract candidiasis, renal fungal bezoars and acute renal failure, successfully managed by using systemic and local antifungal agents.

CASE REPORT

A 3.6-kg male neonate was born vaginally to a 26 year old women at 39 week of gestation. The patient had history of antenatal bilateral hydronephrosis and oligohidramnios. He was brought to the pediatric nephrology department at the 13th day of life. On admission, the patient had impaired renal function (serum creatinine: 9.2 mg/dl) and glob vesicale. Since urethral catheterization could not be done, the passage of urine flow was provided by via a percutaneous suprapubic catheter.

Voiding cystourethrogram (VCUG) showed bilateral grade V vesicoureteral reflux and posterior uretral valve (Figure 1). The patient had fever, vomiting and weight loss. Urine culture yielded *Candida albicans*, *Enterococcus* and *Pseudomonas aeruginosa*. Oral fluconazol (6 mg/kg per day for 10 days), parenteral vancomycin (40 mg/kg/day for 3 weeks) and meropenem (90 mg/kg/day for 4 weeks) were given to the patient. After treatment of urinary tract infection (UTI)

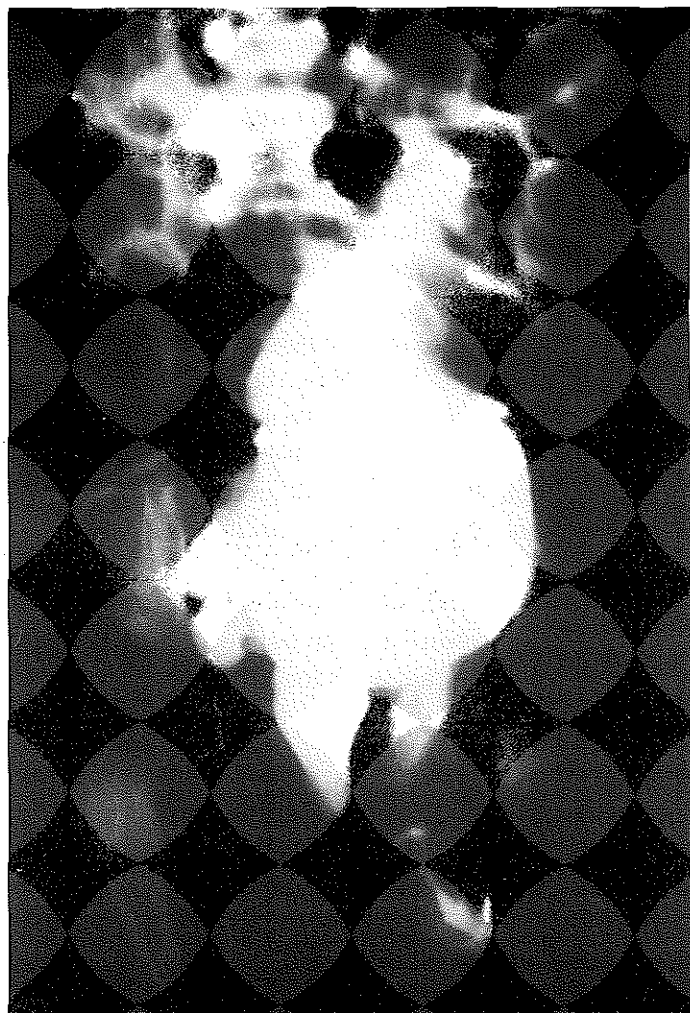Received for publication: May 26, 2003

* Istanbul University, Istanbul Faculty of Medicine, Department of Pediatric Nephrology, Çapa, Istanbul, Turkey

** Istanbul University, Istanbul Faculty of Medicine, Department of Radyology, Çapa, Istanbul, Turkey

*** Istanbul University, Istanbul Faculty of Medicine, Department of Pediatric Urology, Çapa, Istanbul, Turkey

Fig. 1. Voiding cystourethrogram demonstrating posterior urethral dilatation and disturbed bladder



control urine cultures became sterile and his serum creatinin level increased to 2.8 mg/dl. At the 25th day of life endoscopic urethral valve resection was performed and urine passage was maintained through a urethral catheter for 7 days. Repeated voiding cystourethrogram showed disappearance of urethral dilatation (Figure 2). Urethral catheter was removed during follow up period and normal urinary passage was achieved. At the 36th day the child was found to have restlessness, poor feeding and vomiting and ultrasound examination revealed left hydronephrosis and hyperechogenic renal opacities (fungal bezoars) in caliceal system. Meanwhile serum creatinin level increased

to 3.8 mg/dl. Microscopic examination of the urine showed many white cells and candida spors. *Candida albicans* grew from the urinary culture once again. Radio-nuclide scan with MAG3 showed evidences of concentration defect at lower pole of the left kidney and partial obstruction of left ureter. Leucocytosis and high C-reactive protein (CRP) levels were noted. Left percutaneous nephrostomy tube was inserted under ultrasound guidance at the 40th day of patient's life. *Candida albicans* grew in the purulent specimen obtained directly by percutaneous puncture.

Blood cultures yielded no organisms. The patient was accepted as left renal candidiasis with fungal bezoars and intravenous fluconazol (3 mg/kg/day) was used for 4 weeks of period. In addition, the patient was treated by daily irrigation of the left kidney via percutaneously inserted nephrostomy catheter using amphotericin B (1 mg/dl in normal saline solution; twice a day for 3 weeks). Seven days after the treatment, control

urine cultures grew no organism and renal ultrasound revealed resolution of hydronephrosis and hyperechogenic opacities, and glomerular filtration ratio was 35 ml/min per 1.73 m² (serum creatinin: 0.6 mg/dl). Nephrostomy tube was removed at the 40th day. We did not observe any undesired adverse effects of drugs during the follow up period. The last evaluation of the patient at the 20th month of age, displayed average growth and glomerular filtration ratio was 55 ml/min per 1.73 m². Now he is on antibiotic prophylaxis (cefaclor, 10 mg/kg/day) for the prevention of UTI.

DISCUSSION

Although bacterial infections are more frequent in the neonatal period, fungal infections have also been increasingly seen at this age. Common use of intensive care facilities may be a basis for the disseminated fungal infections bearing high morbidity and mortality risks to these children. Systemic candida infections may be in two major forms in the neonatal period. The first form is multiple organ involvement with systemic candidiasis. The second form is candidemia with an isolated renal involvement, with a less serious clinical picture ⁽⁹⁾. Predisposing factors for the development of neonatal renal fungal infections are long-lasting use of broad-spectrum antibiotics, granulocytopenia, being in the intensive care unit, application of total parenteral nutrition, prematurity; the existence of intravascular and urethral cath-

eterization, obstructive lesions that disturb normal urine flow, dilated urinary tract, surgical procedures and damage to mucosal barrier ^(2,3). The infant with renal candidiasis described in this report had a severe uropathy and many risk factors for the development of renal fungal infection including prolonged application of broad-spectrum antibiotics, in situ catheters, obstructive uropathy, urinary dilatation and thus qualifies as a high-risk patient. Renal candidiasis may develop through ascendant way or via haematogenous spreading routes. Fungal pathogens originating from skin and gastrointestinal tract may colonise urinary tract via ascendant route and additional risk factors will predispose to renal candidiasis in this manner. In experimental studies in order to form a systemic candidiasis a number of organisms must be given parenterally to the rats,

although for isolated renal involvement intravenous giving of a little number of fungi becomes enough to cause transient fungemia ⁽¹⁰⁾. This situation can explain the development of renal candidiasis during transient candidemia. Hypertonic or acidic urine, urinary stasis, urogenital anomalies, delayed renal inflammation response, the role of tubular lumen providing an appropriate environment for candida multiplication may predispose to development of the renal candida infections ^(4,5).

Isolated renal candida infections may show a clinically silent course or may be present with fever, deterioration in the general health status, poor renal functions, poor feeding and intractable pyuria ⁽⁵⁾. High-risk patient groups for the development of renal candidiasis must be followed up cautiously. Fungal balls may cause a urinary tract ob-

Fig. 2. Voiding cystourethrogram showing normal urethral urine stream after valve ablation


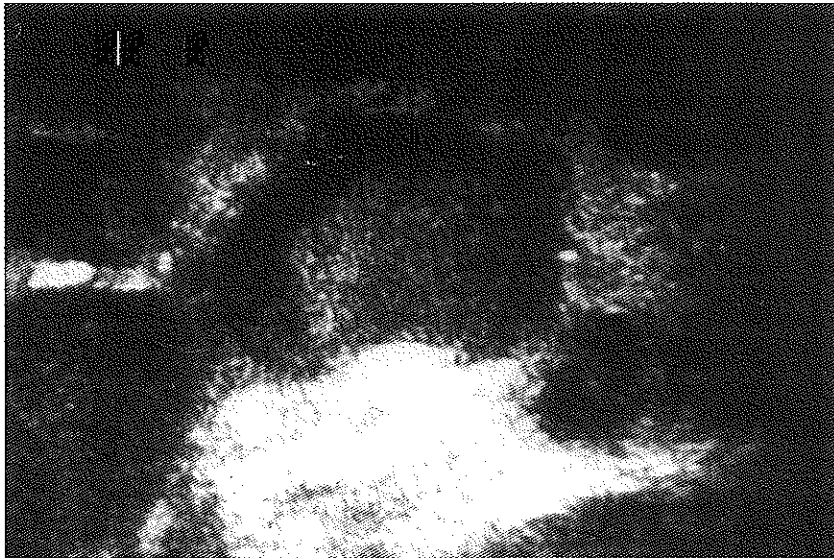


Fig. 3. Renal ultrasound showing hyperechoic masses in the lower calyces of the left kidney resembling fungal bezoar



struction and hydronephrosis or may worsen a pre-existing urinary tract obstruction (1,4). Whenever one suspected from renal candidal infection, appropriate cultures of urine, blood and catheters must be obtained and renal ultrasound must be performed. *Candida* has been difficult to demonstrate in blood cultures of the children with systemic candidiasis (varying between 35% - 52%), but candiduria and pyuria are quite common (8). Urine cultures with colony counts 1500 /ml show significant growth of *Candida* (11). But despite the severity of the renal involvement only 37% of the infants had a positive urine culture (12). This emphasizes the importance of direct renal access for culture in suspected cases of candidiasis, the simplest method to obtain it, is by a percutaneous puncture. Although the sonographic features of renal candidiasis are nonspecific, high-resolution sonography can make a valuable contribution to the early diagnosis of fungal bezoars. Two sonographic patterns may be seen: a dilated collecting system with echogenic masses (snowballs, fungus balls, fungal bezoars) within renal pelvis and/or bladder, or enlarged kidneys with homogenous echo-

genity and loss of architecture (2,13). In our patient, the diagnosis of renal candidiasis was made based on the patient's history, urine culture result, the microscopic finding of mycelium and leucocyte in the urine sediment and typical round-shaped hyperechoic masses in the renal collecting system on ultrasonography.

There is no standard therapeutic regimen for the management of renal mycotic infections and various therapeutic approaches are tried (2,3,14-16). Since fungal balls of renal candida infections can lead to partial or total urinary obstruction, treatment with systemic antifungal agents alone may be ineffective (1). Surgical procedures for the extraction of fungal bezoars from the renal collecting system are controversial. While, some authors suggest evacuation of bezoars and insertion of a drain by open surgical procedures; others recommend percutaneous nephrostomy under the guidance of ultrasound in order to both maintain drainage and apply local antimycotics (14,15,17). Although some candidal infections were reported, to have been treated only by using systemic antifungal agents

(14), generally for successful management drainage by an invasive intervention, irrigation by local antifungal application and systemic usage of antimycotic drugs were recommended (2,3,15). In those studies local irrigation with fluconazol, amphotericin B and methylene blue have been used and additional systemic fluconazol, 5-fluorocytosine and amphotericin B are given. Visser et al. suggested that prompt local irrigation of the kidney and bladder with amphotericin B via percutaneously inserted nephrostomy catheter, in combination with intravenous fluconazol were successful. Üçsel et al. (3) reported successful results by using combined amphotericin B irrigation via percutaneous nephrostomy and intravenous amphotericin B. Here we first applied intravenous fluconazol treatment but after short follow up period there was no improvement in the clinical and ultrasound findings. So we performed percutaneous nephrostomy drainage under the guidance of ultrasound and irrigation with amphotericin B was applied. In this case of complicated renal candidal infection healing was provided without remaining sequel and without using open surgical intervention. In conclusion, complicated renal candidiasis, as a rare condition, can be managed effectively and reliably by systemic and local use of antifungal agents and drainage by nephrostomy catheters. With this approach, the morbidity and mortality associated with renal candidiasis will be reduced.

REFERENCES

1. Hari P, Srivastava A, Gupta AK, Srivastava RN: Neonatal renal failure due to obstructive candidal bezoars. *Pediatr Nephrol* 1997; 11:497.
2. Rebhandl W, Saadi S, Horneth AM, Presleri E, Kurosh P, Wandl-Vergesslich K, Horcher E: Successful conservative treatment of severe renal candidiasis with fungus balls. *Pediatr Nephrol* 1999; 13:688.
3. Üçsel R, Çoban A, Metin F, et al: The management of renal candidiasis in the newborn. *Turk J Pediatr* 1996; 38:239.
4. Baley JE: Neonatal candidiasis The current challenge. *Clin Perinatol* 18:263 (1991).
5. Pappu LD, Purchit DM, Bradford BF, Turner WR, Levkoff AH: Primary renal candidiasis in two preterm neonates. Report of cases and review of literature on renal candidiasis in infancy. *Am J Dis Child* 1984; 138:923.
6. Butler KM, Bajer CJ: Candida: an increasingly important pathogen in the nursery. *Pediatr Clin North Am* 1988; 35:543.
7. Hughes PA, Lepow ML, Hill HR: Neonatal candidiasis. In: Bodey GP (eds) *Candidiasis: pathogenesis, diagnosis and treatment*. New York: Raven 1993; 261.
8. Phillips JR, Karlowicz MG: Prevalence of Candida species in hospital-acquired urinary tract infections in a neonatal intensive care unit. *Pediatr Infect Dis J* 1997; 16:190.
9. Noe HN, Tonkin ID: Renal candidiasis in the neonate. *J Urol* 1981; 127:517.
10. Hurley R, Winner HI: Experimental renal moniliasis in the mouse. *J Pathol Bacteriol* 1963; 86:75.
11. Kozinn DJ, Taschdjian CL, Goldberg PK, Wise GJ, Toni EF, Seeling MS: Advances in the diagnosis of renal candidiasis. *J Urol* 1978; 119:184.
12. Keller MA, Sellers BB, Melish MF, Kaplan GW, Miller KE, Mendoza SA: Systemic candidiasis in infants. A case presentation and literature review. *Am J Dis Child* 1977; 131:1260.
13. Cohen HL, Haller OJ, Schlechler S, Slovis T, Merola R, Eaton D: Renal candidiasis of the infant: ultrasound evaluation. *Urol Radiol* 1986; 8:17.
14. Aktuğ T, Olguner M, Akgür FM, Aldırmaz C, Hoşgör M, Yuluğ N: A new ancient irrigation therapy for childhood renal candidiasis. *Int Urol Nephrol* 1998; 30:127.
15. Visser D, Monnens L, Feitz W, Schmickrot B: Fungal bezoars as a cause of renal insufficiency in neonates and infants-recommended treatment strategy. *Clin Nephrol* 1998; 49: 198.
16. Schware R, Penk A, Pittrow L: Administration of fluconazole in children below 1 year of age. *Mycoses* 1999; 42:3.
17. Yoo SY, Namkoong MK: Acute renal failure caused by fungal bezoar: a late complication of Candida sepsis associated with central catheterization. *J Pediatr Surg* 1995; 30:1600