

**PNEUMOMEDIASTINUM: UNUSUAL AND RARE COMPLICATIONS  
OF ASTHMA IN A 2 YEARS OLD GIRL:  
A CASE REPORT AND REVIEW OF THE LITERATURE**

***PNÖMOMEDIASTİNUM: 2 YAŞINDA BİR KIZ ÇOCUKTA ASTİMİN ALIŞILMAMIŞ  
VE NADİR BİR KOMPLİKASYONU OLARAK BİR OLGU SUNUMU VE LİTERATÜRÜN  
GÖZDEN GEÇİRİLMESİ***

Hülya ERCAN, Özlem KESKİN, Mevlüt CAN, Bülent ŞEKEREL\*

**ABSTRACT**

Pneumopericardium is a rare condition, less common than either isolated pneumothorax or pneumomediastinum. Acute hemodynamic deterioration in a patient with pneumopericardium should prompt further investigation and cardiac tamponade should be actively ruled out. Pneumopericardium is a rare but important complication of asthma. In this paper, 2-year-old boy is described who presented with acute respiratory distress and diagnosed as asthma, egg allergy and pneumopericardium.

**Key words:** Allergy, asthma, children, pneumopericardium

**ÖZET**

Çocuklu çağında izole pnömomediastinum veya pnömotoraksa göre pnömoperikardiyum nadir görülen bir komplikasyondur. Kardiak tamponat gibi hemodinamiğin ani olarak bozulabileceği komplikasyonlar açısından çok iyi izlenmesi gerekir. Astım tanısı almış hastalarda pnömoperikardiyum nadir ancak önemli bir komplikasyondur. Bu olguda, 2 yaşında bir erkek hastada yumurta allerjisine bağlı akut astım atağı tanısının ilk kez solunum sıkıntısı ve pnömoperikardium ile ortaya çıkması sunulmaktadır

**Anahtar kelimeler:** Allerji, astım, çocuk, pnömoperikardiyum

**INTRODUCTION**

Pneumopericardium is a rare condition, less common than either isolated pneumothorax or pneumomediastinum (3) and has been reported to result from barotrauma such as acute asthma, coughing, bronchiolitis (9). Pneumopericardium is a condition air completely surrounds the epicardium and it thus visible in the pericardial sac between the central tendon of the diaphragm and inferior heart border in chest radiographs (4). Acute hemodynamic deterioration in a patient with pneumopericardium should prompt further investigation and cardiac tamponade should be actively ruled out.

In this paper, we describe a 2 year old boy with asthma and egg allergy presented with pneumopericardium.

**CASE**

A 2 year old boy was presented with respiratory distress to the

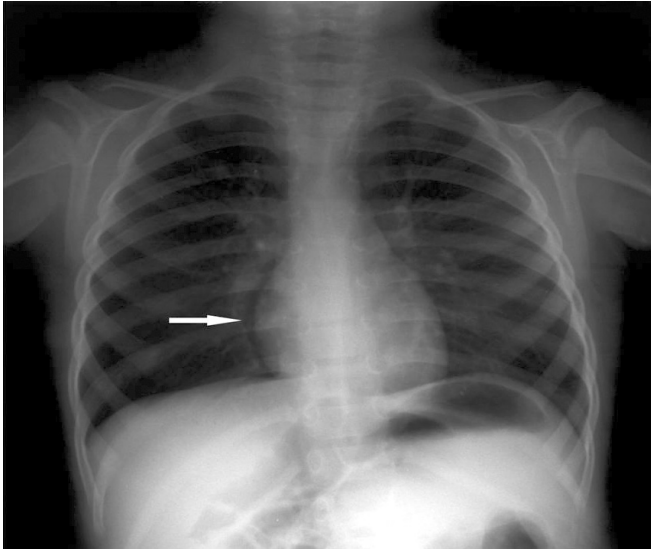
emergency unit. He had productive wheezy cough, dyspnea and clear rhinorrhea of two days duration. Although, he did not have similar symptoms previously. His parent's reported that he refused to eat egg and egg containing foods.

Physical examination revealed body temperature of 36,5°C, heart rate of 156/min, respiratory rate of 60/min, and a normal blood pressure (85/50 mmHg). He had intercostal /subcostal retractions and auscultation revealed sibilant rhonchi and wheezes, with prolongation of the expiratory phase of breathing. Pulse oximetry determination was 85-88 %.

Laboratory findings were as follows: White blood cell 13,600/mm<sup>3</sup> with the predominance of polymorph nuclear leukocytes; eosinophilia (7.7 %). Chest radiography revealed hyperinflated lungs with pneumopericardium (figure 1A). His ECG was normal.

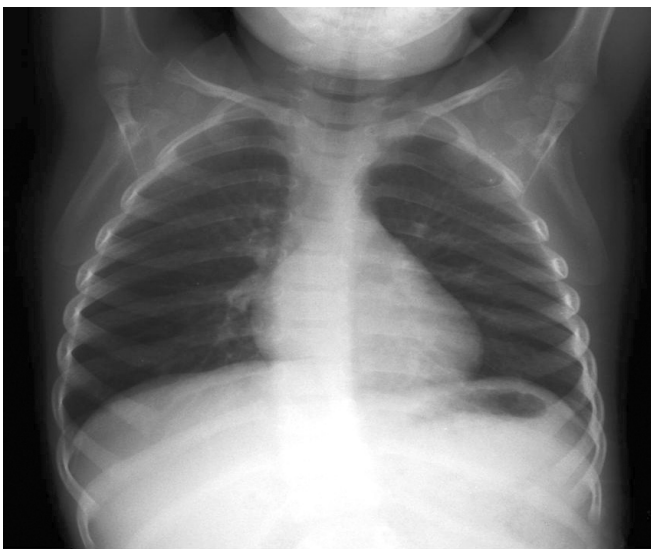
Date received / Dergiye geldiği tarih: 18.08.2006

\* Hacettepe University, Hacettepe Faculty of Medicine, Child Allergy and Asthma Unit, Ankara  
(İletişim kurulacak yazar: hulya\_ercan@yahoo.com)



**Figure 1.A. Chest radiography revealed hyperinflated lungs with pneumopericardium. Subpericardial radiolucent demonstrated pneumopericardium.**

He was hospitalized because of the risk of pericardial tamponade, and cardiovascular deterioration. He was treated with repetitive doses of nebulised salbutamol, oral corticosteroid and nasal oxygen. His dyspnea and wheezing improved gradually and oxygen saturation increased to 94%-96% and the diagnosis of asthma was done. There was a little radiological sing of pneumopericardium at chest x-ray at the second day of treatment. One month after treatment there was no radiological sing of pneumopericardium at chest x-ray (figure 1B). His



**Figure 1.B. A repeat chest x-ray examine one month after treatment revealed resolution of the subpericardial radiolucency.**

allergy work-up revealed a positive specific IgE to egg white (>100 kU/I, CAP-Class 6 respectively) and high total serum IgE level (805 IU/l).

#### DISCUSSION

Pneumopericardium is a rare but important complication of asthma. Symptoms such as radiation of pain towards the shoulders, the back, or the epigastrium, as well as dyspnoea and palpitations, are not always present. Clinical signs such as distant heart sounds, shifting pericardial tympany, and a succussion splash with metallic tinkling and ECG findings such as low voltage, ST segment changes, and T wave inversion are non-specific and unreliable (10). In posteroanterior chest radiographs, a continuous thin radiolucent rim of air follows the cardiac silhouette and is outlined by a fine line representing the pericardial sac (figure 1A) (1). Pneumopericardium usually results from alveolar rupture after chest trauma, barotrauma, invasive procedures, fistulas to the pericardium and pericardial infections (3). After intrapulmonary alveolar rupture, air can dissect through the perivascular sheaths and other soft tissue planes toward, the hilum and enter the mediastinum (2). Air spreading peripherally along the pulmonary arteries and veins dissecting through the pericardium along these vessels can result in pneumopericardium (9). In our patient we hypothesise that barotrauma during coughing and acute asthma might have caused pneumopericardium. Pericardial tamponade due to accumulation of pericardial gas may impair right ventricular filling (6). Even pneumopericardium developed in our case, he had no sign of pericardial tamponade and cardiovascular deterioration.

Pneumomediastinum and pneumopericardium are very rare complications of asthma, in a recent report it has been found as 0.3% (8). Because, he had signs and symptoms of asthma and eosinophilia, we oriented to his allergic history. Then, we learned that he doesn't like eating egg. Total Ig E and egg specific IgE levels were high. He had neither positive family history nor diagnosis of asthma before. Our case was the first presentation of an asthma attack and egg allergy. So, he has been followed for his asthma with egg allergy in our allergy clinic.

Wheezing occurs in about 25% of IgE-mediated food allergic reactions, but only 5-10% of asthmatic patients have food-induced respiratory symptoms. Food allergy is a risk factor for persistent asthma (2). Coexisting asthma is more strongly associated with a severe reaction than the severity of previous reactions. The food allergic child with asthma may be at higher risk (5). Poorly controlled asthma and food allergy are significant risk factors for life-threatening asthma. More intensive management of this high-risk group of children might help to reduce future morbidity and mortality (7).

In conclusion in the light of this case we should think of allergic diseases like asthma and food allergy in wheezy infant who presented with serious complications such as pneumopericardium. And also we want to mention that early diagnosis and effective treatment of wheezy infant should be done to prevent serious complications.

## REFERENCES

1. Bejvan SM. Pneumomediastinum: Old signs and new signs. Am J Roentgenol 1996;9:187-189.
2. Behrman, Kliegman, Jenson, Winnie GB. Pneumomediastinum. Nelson textbook of pediatrics Philadelphia, London, New york, St. Louis, Sydney, Tronto: WB Saunders; 17th ed., 2004; 1465.
3. Brander L, Ramsay D, Dreier D, Peter M, Graeni R. Continuous left hemidiaphragm sign revisited:a case of spontaneous pneumopericardium and literature review. Heart 2002; 88: 5 (1-4).
4. Fletcher BD. Diagnostic imaging of respiratory tracts. In: Chernick V, Boat T, editors. Kending's disorders of respiratory tract in children. 6th ed. Philadelphia: WB Saunders, 1998.
5. Macdougall CF, Cant AJ, Colver AF. How dangerous is food allergy in childhood ? The incidence of severe and fatal allergic reactions across the incidence of severe and fatal allergic reactions across the UK and Ireland. Arch Dis Child 2002; 86:236-239.
6. Reed JR. Hemodynamics of progressive pneumopericardium in the dog. Am J Vet Res 1984; 45:301-307.
7. Roberts G, Patel N, Levi-Schaffer F, Habibi P, Lack G. Food allergy as a risk factor for life-threatening asthma in childhood: A case-controllrd study. J Allergy Clin Immunol 2003; 112:168-174.
8. Stack AM, Caputo GL. Pneumomediastinum in childhood asthma. Pediatr Emerg Care 1996; 12:98-101.
9. Toledo TM, Moore WL Jr, Nash DA, North RL. Spontaneous pneumopericardium in acute asthma: case report and review of the literature. Chest 1972; 62:118-120
10. Tucker WS Jr. Symtoms and signs of syndromes associated with mill Wheel murmurs. N C Med J 1988; 49:569-572.