

Incidence and morphology of the zuckerkanđl's tubercle: An anatomic dissection study

Bülent Yalçın, Süleyman Murat Tağıl, Necdet Kocabıyık, Hasan Ozan

Department of Anatomy, Gülhane Military Medical Academy, Ankara, Turkey

Ozet

Zuckerkanđl tüberkülünün insidansı ve morfolojisi: anatomik diseksiyon çalışması

Çalışmamızda Zuckerkanđl tüberkülünün insidansı ve morfolojisi araştırıldı. Yaşları 40 ile 89 arasında değişen 24'ü erkek 16'sı kadın 40 kadavranın (80 taraf) tiroid bezleri diseke edildi. 9 tarafta (%11,25) çıplak gözle farkedilemeyen tüberkül (grade 0), 16 tarafta (%20) grade 1 tüberkül gözlemlendi. 45 tarafta (%56,25) ise grade 2 tüberkül gözlemlendi. Bu tüberküller dairesel (bezelye şeklinde) ve üçgen şekilli olarak tanımlandı. Tüberküllerin çoğunun tiroid lobunun posterior'unda, 3 tarafta ise posterolateral'inde yerleştiği gözlemlendi. 10 tarafta (%12,5) grade 3 tüberkül gözlemlendi. Bu tüberküller de üçgen (okbaşı şeklinde) ve dikdörtgen şekilli olarak tanımlandı. Bu tüberküllerin genellikle tiroid lobunun lateralinde ve trachea ile oesophagus'un arasında yerleştikleri gözlemlendi. Sadece 2 tarafta retroösofageal yerleşimli tüberküle rastlanıldı. Grade 2 ve 3 tüberküle tarafların %68,75'inde rastlanıldı. Bu tüberküllerin genellikle tiroid lobunun posterior'unda yerleştiği gözlenmekteyken birkaç tanesinin de posterolateralde yerleştiği tespit edildi. Çalışmamızda Zuckerkanđl tüberkülünün yerleşimi ve morfolojisinin anlaşılabilmesi için bulgular yüksek çözünürlüklü fotoğraflar ile ortaya konuldu.

Anahtar kelimeler: tiroid bezi - Zuckerkanđl tüberkülü - nervus laryngeus inferior - bası semptomları - ösofagus

Abstract

The purpose of this study was to investigate incidence and morphology of the Zuckerkanđl's tubercle. Forty specimens (80 sides) were examined for this project, including 24 males and 16 female Turkish cadavers between the ages of 40 and 89 years at death. Unnoticeable tubercle (grade 0) was observed in 9 sides (11.25%), while grade 1 was found in 16 sides (20%). Grade 2 was observed in 45 sides (56.25%). Its shape was circular, similar to a pea or triangular. The tubercle extended postero-lateral to the thyroid lobe in 3 sides, while posterior to it in most sides. Grade 3 was found in 10 sides (12.5%). Its shape was also triangular, like a large arrowhead, or quadrangular. The grade 3 tubercle was generally located at lateral of the thyroid gland and between the trachea and esophagus. Retro-esophageal location was found only in two sides. We found grade 2 and 3 Zuckerkanđl's tubercle in 68.75% sides of 40 cadavers. They were generally located posterior to the thyroid lobe, while a few postero-lateral. To be understood the position and morphology of the Zuckerkanđl's tubercle, we have documented our findings in the form of high-resolution photographs.

Key words: thyroid gland - Zuckerkanđl's tubercle - inferior laryngeal nerve - impression symptom - esophagus

Introduction

The Zuckerkanđl's Tubercle (ZT) is a lateral or posterior projection from the lateral thyroid lobe, which indicates the point of embryologic fusion of the ultimobranchial body and principal median thyroid process (1). In 1902, Emil Zuckerkanđl had referred to the tubercle as "processus posterior glandulae thyroideae" (2). To the mid 1980s, the ZT was of no

interest to surgeons and anatomists. However after the date, it have attracted attention of some surgeons. They have referred it as an anatomical landmark for the location of the inferior laryngeal nerve and parathyroid glands (1, 3). Additionally, Hisham and Aina (4) presented a paper about compression symptoms and Zuckerkanđl's tubercle. Because of the importance of the tubercle we aimed to investigate it in detail and to document our findings in the form of high-resolution photographs, which may be useful for the thyroid surgeon.

Address for correspondence: Bülent Yalçın, MD,
Gülhane Askeri Tıp Akademisi (GATA),
Anatomi AD, 06018 Etlik-Ankara
Tel: 312 304 3506 Fax: 312 304 2150
E-mail: byalcin@gata.edu.tr; drbyalcin@yahoo.com

Material and Methods

Forty specimens (80 sides) were examined for this project, including 24 males and 16 female Turkish cadavers between the ages of 40 and 89 years at death. Medical records for the subject included no histories of neck or superior mediastinum disorders during life. Cause of death was unrelated to the organs of head and neck, which were carefully examined to be sure that they showed no signs of trauma, deformities, tumors, or significant volume loss. The study was performed at the Department of Anatomy, Gülhane Military Medical Academy during a one year, between September 2004 and October 2005. Dissection was performed from the lateral lobe of the thyroid gland to the posterior of the pharyngo-esophageal region under a Zeiss-OPMI (Oberkochen, Germany) dissection microscope ($\times 4-6$ magnification). The fascia of the lateral lobe was entirely removed to clearly expose the tubercle. Finally, it was documented in the form of high-resolution photograph by using a Canon PowerShot G5 digital camera.

Results

Recognizable ZT was identified in 68.75% of 80 sides. They generally extended beyond the posterior to the posterior border of the lateral lobe of the thyroid gland. For morphometric classification, we used the grading system of Pelizzo et al. (3): grade 0, unrecognizable; grade 1, only a thickening of the lateral edge of the thyroid lobe; grade 2, smaller than 1 cm; grade 3, larger than 1 cm. The ZT was located not only at the level of the ligament of Berry but also at the upper and lower third of the lateral lobe of the thyroid gland. Unrecognizable ZT (grade 0) was observed in 6 right and 3 left sides (11.25%, Figure 1A), while grade 1 was found in 7 right and 9 left sides (20%, Figure 1B).

Grade 2 was observed in 18 right and 27 left sides (56.25%). Its shape was circular, similar to a pea (Figure 2A) or triangular (Figure 2B). The ZT extended postero-lateral in 3 sides (Figure 2C), while it coursed only posterior in most sides.

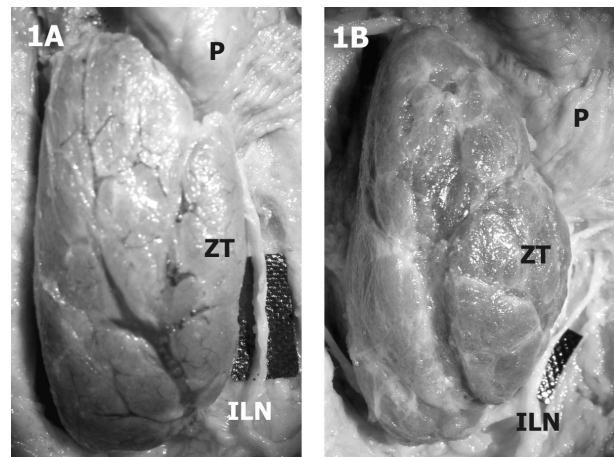


Figure 1. (A), Unrecognizable (grade 0) and (B), grade 1 Zuckerkandl's tubercle (ZT) were observed in 25 of 80 sides. Pharynx (P), Inferior Laryngeal Nerve (ILN)

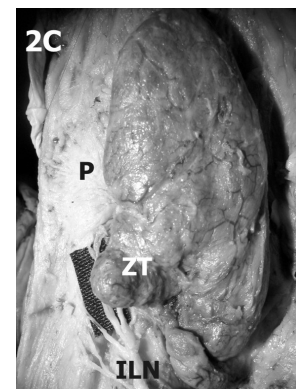
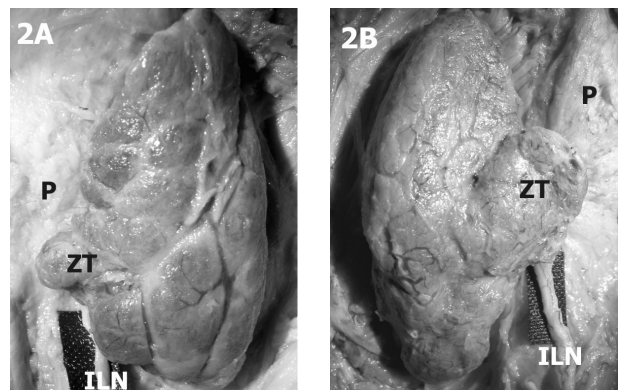


Figure 2. Grade 2 Zuckerkandl's tubercle (ZT) was observed in 45 of 80 sides. Its shape was (A) circular or (B) triangular. (C), The ZT extended postero-lateral in 3 sides. Pharynx (P), Inferior Laryngeal Nerve (ILN)

Grade 3 was found in 6 right and 4 left sides (12.5%). Its shape was also triangular, like a large arrowhead (Figure 3A), or quadrangular (Figure 3B). The grade 3 ZT was generally located lateral to the lateral lobe of the thyroid gland and between the trachea and esophagus. Retro-esophageal location was found only in two sides.

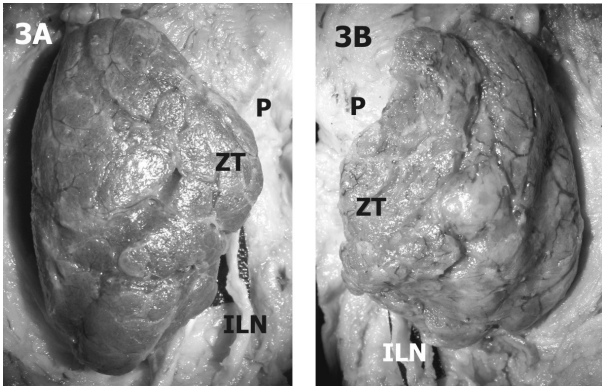


Figure 3. Grade 3 Zuckerkandl's tubercle (ZT) was found in 10 of 80 sides. Its shape was (A) triangular or (B) quadrangular. Pharynx (P), Inferior Laryngeal Nerve (ILN)

Statistical analysis showed that there were no relationship between the incidences of the Zuckerkandl's tubercles in the right and left sides, and between the tubercles and sex.

Discussion

Embryology of the thyroid gland was summarized as follows: "The thyroid gland develops from two anlagen: the larger median anlage, and the paired smaller lateral anlagen. The median anlage, recognizable by the end of the third week, forms the bulk of the thyroid gland. It presents histologically as an epithelial thickening in the ventral pharyngeal wall, in an area known as the tuberculum impar, at the level of the second branchial arch. Its first appearance is (variably) as a shallow depression with thickened epithelium, as a single diverticulum, or as a paired diverticulum. Division into lateral lobes, if not present from the beginning, occurs so early that it is impossible to say whether the human thyroid arises singly or as a paired organ. The lateral thyroid anlage, which originates from the ventral portion of the fourth pharyngeal pouch, becomes attached to the posterior surface of the thyroid during the fifth week. It is estimated that the lateral thyroid anlage contributes perhaps 1% to 30% to the thyroid weight. The causes of the fusion of the median and lateral anlagen are unknown." (5). The lateral thyroid component is particularly relevant to discussion about the ZT (1).

In recently published data, Pelizzo et al. (3) investigated the ZT in 104 sides of Italian patients during lobectomy. They found grade 0 in 24 (23.0%), grade 1 in 9 (8.6%), grade 2 in 56 (53.8%) and grade 3 in 15 (14.4%) sides. Hisham and Aina (4) found grade 0 and 1 in 19 (19.8%) of 96 sides of Malaysian patients. Twenty-four (25%) had grade 2 whereas

grade 3 was seen in 53 (55.2%) sides. Gauger et al. (1) found grade 0, 1, or 2 in 55%, and grade 3 in 45% Australian patients. In comparison, we found grade 0 in 11.25%, grade 1 in 20%, grade 2 in 56.25% and grade 3 in 12.5% of Turkish cadavers. As seen in table I, incidence of the grade 3 ZT was lower than in that of Hisham and Aina (4) and Gauger et al. (1).

Table 1. Incidence of the Zuckerkandl's tubercle

	Grade 0	Grade 1	Grade 2	Grade 3
Pelizzo et al.(3) %	23	8.6	53.8	14.4
Hisham and Aina (4) %	19,8		25	55.2
Gauger et al. (1) %	37	18		45
Present study %	11.25	20	56.25	12.5

Conceivably, this discrepancy may have been influenced by geographical or environmental factors, genetic or ethnic factors. Recognizable ZT (particularly grade 2 or 3) has clinical importance because it is used as an anatomic landmark for the inferior laryngeal nerve and has compression symptoms. Pelizzo et al. (3) published an article and with the title "Zuckerkandl's tuberculum: an arrow pointing to the recurrent laryngeal nerve (constant anatomical landmark)" and advised that the best way to locate the nerve is the identification and careful mobilization of the tubercle. Hisham and Aina presented a paper about compression symptoms and ZT. Eighty-one percent of their patients with grade 3 tubercle had compression symptoms. They advised that in relatively small-sized goitres the ZT might cause significant pressure symptoms (4).

In conclusion, we found grade 2 and 3 ZT in 68.75% sides of 40 cadavers. They were generally located posterior to the thyroid lobe, while a few posterolateral. Knowledge of its incidence and importance in thyroid surgery has been recognized, but has not been widely disseminated among practicing surgeons. The size and perhaps more importantly the position, of the ZT may have an unpredictable relationship to preoperative symptoms of compression (1). To be understood the position and morphology of the tubercle, we have documented our findings in the form of high-resolution photographs.

References

1. Gauger PG, Delbridge LW, Thompson NW, Crummer P, Reeve TS. Incidence and importance of the tubercle of Zuckerkandl in thyroid surgery. *Eur J Surg* 2001; 167: 249-254
2. Zuckerkandl E.. Nebst Bemerkungen uber die Epithelkorperchen des Menschen. *Anat Hefte* 1902; LXI: 61
3. Pelizzo MR, Toniato A, Gemo G. Zuckerkandl's tubercle: an arrow pointing to the recurrent laryngeal nerve (constant anatomical landmark). *J Am Coll Surg* 1998; 187: 333-336
4. Hisham AN and Aina EN. Zuckerkandl's tubercle of the thyroid gland in association with pressure symptoms: A coincidence or consequence? *Aust NZJ Surg* 2000; 70: 251-253
5. Mirilas P, Skandalakis JE. Zuckerkandl's Tubercle. *Hannibal ad Portas. J Am Coll Surg* 2003; 196: 796-801