

Azygos vein system abnormality: case report

Necdet Kocabiyik (*), Tunç Kutoğlu (**), Soner Albay (*), Bülent Yalçın (*), Hasan Ozan (*)

Summary

Variations seen in the thoracic vein system are related to the development of these veins. During the dissection from the posterior mediastinum of the 60-year-old male cadaver, it was observed that there was no complete accessory hemiazygos vein, and both posterior intercostal veins and hemiazygos vein (above T10 level) drained bilaterally to the azygos vein. Considering these types of variations is important during imaging this region and surgical operations.

Key words: Azygos vein, hemiazygos vein, superior vena cava, venous anomaly

Özet

Azygos ven sistem anomalisi: olgu sunumu
Toraks ven sisteminde görülen varyasyonlar, embriyolojik olarak bu venlerin gelişimiyle ilgilidir. Altmış yaşındaki erkek kadavranın posteriyor mediastenindeki diseksiyon sırasında; v.hemiazygos accessoria'nın tam olarak oluşmadığı, iki taraflı posteriyor interkostal venlerin ve v.hemiazygos'un (T10 düzeyinde) v.azygos'a drene olduğu gözlemlendi. Bölge ile ilgili görüntüleme ve cerrahi girişimlerde bu tür varyasyonların bilinmesi önem arz eder.

Anahtar kelimeler: vena azygos, vena hemiazygos, vena cava superior, venöz anomali

Introduction

Abnormalities related to the azygos system are not rare (1). In a series of 200 cases, Bergman et al. have reported the incidence of this anomaly 26% (2). These abnormalities are generally explained by the embryological development. Venous branching of the azygos vein varies (3). There are two origins of the azygos and hemiazygos veins. By union of these origins and regression of some parts, azygos system comes into its final status (4). Different types of structures may occur when these veins develop. Abnormalities about azygos system and especially the variations of the hemiazygos veins are not clearly described in the literature. In this presentation absence of the accessory hemiazygos vein and possible causes of these types of variations are discussed in view of the embryological development.

Case Report

During the dissection of the posterior mediastinum of a 60-year-old male cadaver; it was observed that there was no complete accessory hemiazygos vein in the azygos vein system, and posterior intercostal veins drained bilaterally to the azygos vein. Right ascending lumbar vein formed azygos vein and left ascending lumbar vein formed hemiazygos vein. After left subcostal vein opened to the hemiazygos vein, hemiazygos vein joined to the azygos vein at the level of T10 vertebra. The 10th posterior intercostals vein joined to the azygos vein by contacting with hemiazygos vein. Left 7, 8 and 9th posterior intercostals veins conjugated and opened to the azygos vein after forming one single root (Figure 1). Inferior vena cava and superior vena cava were normal and their courses were usual.

Discussion

The cardinal venous complex that constitutes the main venous drainage system of the embryo appears in the third week of intrauterine growth as two big vessels. These vessels, called anterior cardinal vein and posterior secondary, drain cranial and caudal part of embryo. These two

* GATA Anatomi AD

**Trakya Üniversitesi Tıp Fakültesi Anatomi AD

Ayrı basım isteği: Dr. Necdet Kocabiyik, GATA Anatomi AD, Etlik-06018, Ankara

E-mail: nkocabiyik@gata.edu.tr

Makalenin geliş tarihi: 19.09.2005

Kabul tarihi: 15.06.2006

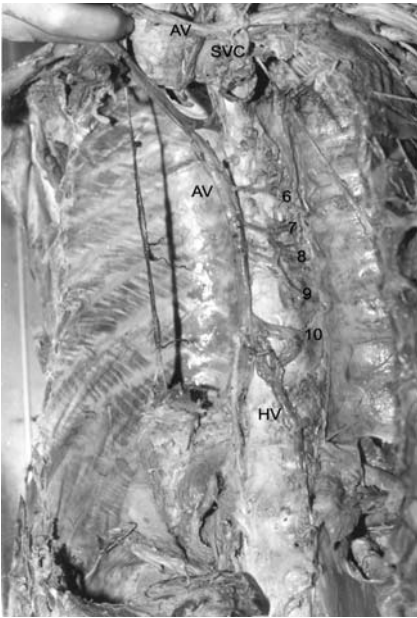


Figure 1. Azygos and hemiazygos veins. AV, azygos vein; SVC, superior vena cava; HV, hemiazygos vein; (6,7,8,9,10), posterior intercostal veins

veins meet both at two sides and constitute common cardinal vein, which opens to sinus venosus. In the eight week of embryo an oblique anastomosis occurs between two anterior cardinal veins. This connection becomes left brachiocephalic vein when the caudal part of left anterior cardinal vein degenerates. Right anterior cardinal vein and right common cardinal vein constitute superior vena cava. The left anterior cardinal and the left common cardinal veins, which are in the caudal part of left brachiocephalic vein are mostly regressed (4). Left common cardinal vein constitutes left oblique vein of atrium (5). The beginning part of the left superior intercostals vein generates from the cranial point of the postcardinal vein, and drains second, third and mostly fourth intercostal veins. In adults both of posterior cardinal veins constitute the root of azygos vein and common iliac vein. The cardinal vein and supracardinal vein gradually take place of posterior cardinal vein. Both of the supracardinal veins are the last grown vein

packed. The vein, which is at the left side of these veins degenerates in the caudal part of kidney and the vein, which is at the right side constitutes postrenal part of inferior vena cava (4).

The azygos and hemiazygos veins have two origins (1). The first one is the terminal part of posterior cardinal vein, which combines with superior vena cava, and the second one is the right supracardinal vein. This embryologic vessel gives rise to right ascending lumbar vein. The left ascending lumbar vein is composed of the left supracardinal vein. The left superior intercostal vein and accessory hemiazygos vein originate from the left posterior cardinal vein and this vein simultaneously forms the upper part of the azygos vein. The part that connects hemiazygos vein to azygos vein is actually remainder of the anastomosis between the left and the right posterior cardinal veins (6). Azygos veins embryologically generate from subcardinal veins. The right subcardinal vein forms azygos vein and the left subcardinal vein forms hemiazygos vein.

A transverse anastomosis is formed between them approximately at sixth and seventh thoracic vertebrae in adults. At the left side, cranial part of this anastomosis is partially atrophied or it remains as accessory hemiazygos vein. In our case accessory hemiazygos vein did not exist due to total regression of the left subcardinal vein and atrophy of veins forming hemiazygos and accessory hemiazygos veins that were embryologically above anastomosis of right and left postcardinal veins because of this, the left posterior intercostal veins drained into the azygos vein.

Bergman et al. have reported the incidence of incomplete formation of hemiazygos and accessory hemiazygos veins as 15% (2). If the hemiazygos is underdeveloped, its branches

open directly into the azygos vein as observed by Bergman et al. In the case we reported there were underdeveloped veins, and the posterior intercostal veins opened into the azygos vein.

In the case reported by Caggiati and Barberini, two venous structures that had to be derived from right supracardinal veins were not seen (6). Thus in forming venous structure, there was no main vessel collecting right intercostals veins, and venous drainage was collaterally provided by the only vessel that was longitudinally moving at the left part. That vessel opens to superior vena cava from left (6).

In our case, hemiazygos vein joined azygos vein at the level of T10 vertebra, so that there was one main vessel. In Mezzogiorno and Passiatore's case there were both of the vessels and there was a transverse connection between them (1). In the case of Özbek et al. hemiazygos vein was absent (7). Fifth and sixth left posterior intercostal veins with third and fourth opened to left superior intercostals vein. In the case of Özdemir et al., in addition to absence of hemiazygos vein, there were superior intercostal veins that drained this region and the connection vein with the azygos and accessory hemiazygos veins (8). In both of the cases azygos vein opened to superior vena cava.

Cossina et al. have reported two azygos veins that continue with inferior vena cava (9). This case can be accounted for by embryological persistence of both supracardinal veins. Continuing with inferior vena cava of azygos system is associated with the anomalies of superior vena cava and azygos system, congenital heart disease, aspleny and polispleny syndromes, and abdominal situs anomalies (10-12). Congenital heart disease should be searched in cases with this kind of anomaly.

It is important to determine the variations of the azygos system especially in the computed tomography and magnetic resonance imaging of mediastinum. The anomalous azygos venous system may easily be confused with aneurysm, lymphadenopathy and other anomalies like tumor (7,13,14). It is important to keep in mind this kind of variations in the mediastinal operations or surgery of large vessels.

References

1. Mezzogiorno A, Passiatore C. An atypic pattern of the azygos venous system in man. *Anat Anz* 1988; 165: 277-281.
2. Azygos vein. Bergman RA, Afifi AK, Miyauchi R. <http://www.anatomyatlases.org/anatomicvariants/cardiovascular/text/veins/Azygos.shtml> (last accessed 17.10.2006)
3. Davis RA, Milloy FJ, Anson BJ. Lumbar, renal and associated parietal and visceral veins based upon a study of 100 specimens. *Surg Gyn Obstet* 1958; 107: 3-18.
4. Standring S. *Gray's Anatomy. The Anatomical Basis of Clinical Practice.* 39th ed. Churchill Livingstone, 2005: 1025-1027, 1045-1050.
5. Ozan H. *Anatomi.* 2. baskı. Ankara: Klinisyen Tıp Kitapevleri, 2005: 192-194.
6. Caggiati A, Barberini F. Partial agenesis of the azygos vein: a case report. *Ann Anat* 1996; 178: 273-275.
7. Özbek A, Dalçık C, Çolak T, Dalçık H. Multiple variations of the azygos venous system. *Surg Radiol Anat* 1999; 21: 83-85.
8. Özdemir B, Aldur MM, Çelik HH. Multiple variations in the azygos venous system: a preaortic interazygos vein and the absence of hemiazygos vein. *Surg Radiol Anat* 2002; 24: 68-70.
9. Coscina WF, Arger PH, Mintz MC, Coleman BG. Concurrent duplication and azygos continuation of the inferior vena cava. *J Comput Tomogr* 1986; 10: 287-290.
10. Minniti S, Visentini S, Procacci C. Congenital anomalies of the venae cavae: embryological origin, imaging features and report of three new variants. *Eur Radiol* 2002; 12: 2040-2055.
11. Vijayvergiya R, Bhat MN, Kumar RM, Vivekanand SG, Grover A. Azygos continuation of interrupted inferior vena cava in association with sick sinus syndrome. *Heart* 2005; 91: e26.
12. Churchill RJ, Wesby G, Marsan RE, Moncada R, Reynes CJ, Love L. Computed tomographic demonstration of anomalous inferior vena cava with azygos continuation. *J Comput Assist Tomogr* 1980; 4: 398-402.
13. Smathers RL, Lee JKT, Heiken JP. Anomalous preaortic interazygos vein. *J Comp Assist Tomogr* 1983; 7: 732-733.
14. Takasugi JE, Godwin JD. CT appearance of the retroaortic anastomoses of the azygos system. *AJR* 1990; 154: 41-44.