

Fertility following conservative management of stage I borderline tumor of the ovary

Murat Dede (*), Tolga Çiftınar (*), Tansu Küçük (*), Müfit Cemal Yenen (*), Murat Muhçu (*), İskender Başer (*)

Summary

Ovarian epithelial tumors do not prevent reproduction if they are diagnosed at an early stage. Conservative surgery preserving normal ovarian tissue is necessary for future fertility. We present a case of borderline ovarian tumor detected in a 25-year-old nulliparous woman. Following the conservative surgery of serous borderline tumor she underwent an intracytoplasmic sperm injection cycle, and delivered full-term twins with cesarean section.

Key words: Borderline tumor, conservative management, in vitro fertilization, ovary

Özet

Overin evre I sınırdaki tümörlerinde konservatif yaklaşım sonrası fertilitate durumu

Overin epitelyal tümörleri eğer erken evrede tanı konulup tedavi edilebilirse üreme için bir engel değildir. Gelecek fertilitate beklentisi olanlarda normal over dokusunu bozmamak için koruyucu cerrahi önemlidir. Bu yazıda 25 yaşında nullipar bir bayandaki borderline over tümörü sunulmaktadır. Seröz sınırdaki tümör saptandıktan sonra yapılan fertilitate koruyucu cerrahi sonrası hastaya intrasitoplazmik sperm enjeksiyonu uygulandı

ve hasta daha sonra sezaryen ile termde ikiz bebek doğurdu.

Anahtar kelimeler: Sınırdaki tümör, konservatif yaklaşım, in vitro fertilizasyon, over

Introduction

Borderline ovarian tumors are known as low malignancy potential tumors. They constitute 10-15% of all epithelial ovarian malignancies. Since approximately 80% of these tumors are diagnosed at stage I or II and the malignancy potency is low, the prognosis is better than other ovarian malignancies. Because they are seen in the reproductive period, preservation of fertility is an important issue in the management of these tumors. We present a case of borderline ovarian tumor managed conservatively for future fertility.

Case Report

Twenty five-year-old nulliparous, white female, married for 7 years admitted to a center with irregular menstrual bleeding. Her findings and laboratory results in this first visit are not available. She was given a long course of oral contraceptive. After 2 years of treatment, at the control examination she was told to have an

ovarian cyst and she was advised to continue oral contraceptive treatment. In 2000 she admitted to another clinic with desire of fertility. Sonographic examination revealed a septated cystic mass at the left ovarian region. Results of diagnostic work up are not available. She was offered a diagnostic laparoscopy but she did not accept. In the year 2001, she admitted to the same center, this time she accepted the diagnostic laparoscopy. At that time, laboratory work-up revealed CA 125: 104 U/ml, beta hCG: 0.8 IU/ml, CEA: 0.7 ng/ml, AFP: 0.3 IU/ml. At the operation, a cystic mass in left ovary was seen. Instead of removing the cyst, the operator preferred to get only a biopsy. Histopathologic examination of the biopsy taken from the cyst was reported as borderline serous papillary tumor. Peritoneal washing was positive for tumor cells.

She was referred to a tertiary center for laparotomy. In February 2001, she had undergone a staging laparotomy consisting bilateral tumor resection and ovarian reconstruction. In 2002, she was operated again for a tumor of 12 cm on the right ovary. Tumor was resected and ovarian reconstruction was performed. His-

*Department of Obstetrics and Gynecology, Gülhane Military Medical Academy

Reprint request: Dr. Murat Dede, Department of Obstetrics and Gynecology, Gülhane Military Medical Academy, Etlik-06018, Ankara, Turkey
E-mail: mdede@gata.edu.tr

Date submitted: June 06, 2006

Accepted: August 09, 2006

topathologic examination was reported as Grade I borderline tumor as seen in Figure 1.

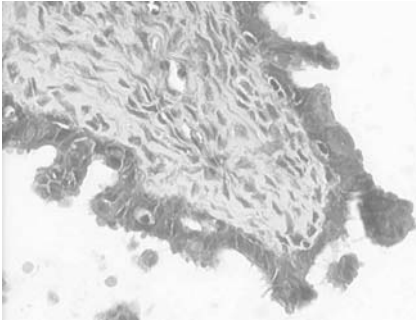


Figure 1. Papillae with cellular fibrous stroma and lined by stratified epithelium, HEx200

Fifteen months after the second laparotomy, she admitted to our infertility center with the desire of fertility. In April 2003 she was applied an IVF-ICSI protocol. Although her previous surgery might have caused a dense pelvic adhesion, we made a complete investigation for infertility evaluation. At the third day of the menstrual cycle the basal FSH was 2.14 and E2 was 175.75, indicating adequate ovarian reserve. She was applied an ICSI cycle because of male factor infertility.

She was given a long GnRHa protocol using triptorelin asetat 0.1 (Decapeptyl, Erkim) for pituitary suppression. After ten days of COH using recFSH (Puregon, Organon) we retrieved 11 mature oocytes. Sperm concentration was 1×10^6 with zero progressive motile sperm, 30% motile sperm. Using ICSI we got 4 embryos. At the third day Grade I, 4 embryos (8,7,6,6 blastomer) were transferred with Wallace Embryo Transfer catheter. The vaginal ultrasonography at the seventh week showed two intrauterine gestational sacs. The pregnancy was uneventful. At January 18, 2004 she gave birth with cesarean section at the 36th week of gestation. She has twins. One of them was 2450 g girl; the other was 2800 g girl. In cesarean section both

of two ovaries were seen normally. We preferred cesarean section since this was a multiple pregnancy after IVF procedure.

After all she was called for control examinations for three months, and she was wanted to apply to the oncology clinic for the control of the tumor.

Discussion

Borderline ovarian tumors account for 10-15% of all ovarian tumors. Studies have consistently demonstrated the favorable prognosis of these tumors. The overall 10-year survival rate is 83-91%. Even patients with stage III disease have a good prognosis, with survival rates of 50-86%. The borderline ovary tumors tend to occur more frequently during the reproductive age of the woman. These tumors are seen in women younger than 35-40 ages. For the patients at these ages, the reproductivity is one of the most important medical problems. In the study of Seracchioli et al, there were six spontaneous pregnancies, and all went to term (1). Despite the good outcomes, this approach cannot be broadly recommended because of the lack of complete staging to include pelvic and para-aortic lymph node sampling. In such patients early surgical treatment may provide a long-term control for serous borderline tumor of the ovary (1,2).

As reported in the study of Donnez et al, an early and a well done fertility sparing conservative surgery may provide no recurrence in tumor and will bring pregnancy (2). Unilateral salpingo-oophorectomy must be considered as the first choice of conservative treatment in most patients, because it seems to be associated with lower recurrence rates. In their study, all the patients conceived spontaneously, and the rate of pregnancy is 63.6%. In our case we used assisted

reproductive technology with IVF-ICSI long protocol because of male factor. In the study of Camatte et al, they used IVF protocol for persistent infertility (3). They reported that of 17 women with stage II or III borderline ovarian tumor treated with fertility-preserving surgery, only two women recurred and there were no deaths at a median follow-up of 60 months. The same group reported on pregnancy outcomes among their entire cohort of 44 women treated conservatively for borderline ovarian tumors. There were 17 pregnancies in 14 women. Fifteen were spontaneous, one patient was treated with clomiphene citrate, and one woman conceived after in-vitro fertilization (IVF) (3).

As has already been discussed, patients with borderline ovarian tumors tend to be younger than women with invasive ovarian cancer. For many of these patients, fertility is an important issue. Previous studies have suggested the safety of conservative surgery with unilateral salpingo-oophorectomy or cystectomy for patients with stage I borderline ovarian tumors. This observation has been confirmed and even expanded to include women with advanced-stage disease. Zanetta et al. studied 339 women who were treated for borderline ovarian tumors. Although the recurrence rate was higher for women undergoing fertility-sparing surgery (35/189 cases, 18.5%) compared with women undergoing hysterectomy and bilateral salpingo-oophorectomy (seven out of 150 cases, 4.7%) all but one women with a recurrence of borderline tumor or progression to carcinoma after conservative surgery were salvaged (4).

The preceding studies emphasize the safety of conservative management for women with borderline ovarian tumors, as long as fertility-preserving surgery can remove all of

the patient's visible disease. Whether infertility treatment is safe in these women is less clear, as too few women have been studied to draw valid conclusions (5).

Unilateral cystectomy may have more chance of preserving a woman's fertility compared to adnexectomy because of the removal of less ovarian tissue. Its greatest danger is the risk of inadvertently leaving behind some malignant cells (2).

In most of the borderline tumors including both of the ovaries, the recurrence rate is high. It was the same in our case. Approximately one and a half year after the surgery, we found recurrence in the tumor. The standard procedure for these tumors is bilateral adnexectomy, hysterectomy and associated with often radiotherapy and chemotherapy as same as their invasive counterparts. However we made a conservative surgery. We tried to preserve the ovaries with extracting only the lesion and by making a reconstruction to the ovaries.

Young patients with ovarian tumors of low malignant potential

usually undergo conservative surgery because of the excellent prognosis of these tumors. Patients wishing to conceive after diagnosis occasionally require ovulation induction, but data regarding the safety of assisted reproductive technologies in this situation remains unclear. In the study of Beiner et al it is seen that ovulation induction is a choice for pregnancy after the diagnosis of a borderline ovarian tumor (5).

If we have a pregnancy chance even in the advanced tumors, as reported in the study of Hoffman et al (6), we have more advantages in early stage ovarian serous borderline tumors with conservative management and assisted reproductive technology.

In a very recent paper by Fasouliotis et al, 3 term births out of 5 borderline tumor cases were presented (7). We wanted to add more data pertinent to this issue.

References

1. Seracchioli R, Venturoli S, Colombo FM, Govoni F, Missiroli S, Bagnoli A. Fertility and tumor recurrence rate

after conservative laparoscopic management of young women with early-stage borderline ovarian tumors. *Fertil Steril* 2001; 76: 999-1004.

2. Donnez J, Munschke A, Berliere M, et al. Safety of conservative management and fertility outcome in women with borderline tumors of the ovary. *Fertil Steril* 2003; 79: 1216-1221.
3. Camette S, Morice P, Pautier P, Atallah D, Duvillard P, Castaigne D. Fertility results after conservative treatment of advanced stage serous borderline tumor of the ovary. *J Obstet Gynecol* 2002; 109: 376-380.
4. Zanetta G, Rota S, Chiari S. Behavior of borderline tumors with particular interest to persistence, recurrence and progression to invasive carcinoma. *J Clin Oncol* 2001; 19: 2658-2664.
5. Beiner ME, Gotlieb WH, Davidson B. Infertility treatment after conservative management of borderline ovarian tumors. *Cancer* 2001; 92: 320-325.
6. Hoffman JS, Laird L, Benadiva C, Dreiss R. In vitro fertilization following conservative management of stage 3 serous borderline tumor of the ovary. *Gynecol Oncol* 1999; 74: 515-518.
7. Fasouliotis SJ, Davis O, Schattman G, Spandorfer SD, Kligman I, Rosenwaks Z. Safety and efficacy of infertility treatment after conservative management of borderline ovarian tumors. *Fertil Steril* 2004; 82: 568-572.