

Bicuspidization: a case report

Mehmet Dalkız (*), Altuğ Çilingir (*), Bedri Beydemir (*)

Summary

The increased desire of patients to maintain their dentition has forced conservative dentistry to conserve the teeth in the mouth which are planned to be removed. In the light of this finding it is known that periodontally compromised teeth with severe bone loss at furcation area may well be retained of their roots. In this case report bicuspidization of the right first mandibular molar with a simple procedure and subsequent prosthetic treatments are presented.

Key words: Bicuspidization, furcation defects, root separation

Özet

Bikuspidizasyon: olgu sunumu

Hastaların kendi dişlerinin sağlıklı bir şekilde korunmasına gösterdikleri özenin giderek artması sonucunda, koruyucu diş hekimliği çekimi düşünülen dişlerin ağızda tutulması için değişik tedavi alternatifleri aramaktadır. Bu düşüncenin ışığında, furkasyon bölgesinde aşırı kemik kaybı olan dişlerin çeşitli tedavi yöntemleri kullanılarak ağızda tutulduğu bilinmektedir. Bu makalede alt sağ birinci molar dişin basit bir yöntemle biküspidizasyonu ve sonrasında uygulanan protetik tedaviler sunulmaktadır.

Anahtar kelimeler: Biküspidizasyon, furkasyon defektleri, köklerin ayrılması

Introduction

The treatment, management and long-term retention of mandibular molar teeth exhibiting furcation invasions (FI) have always been a challenge to the discerning general dentist or dental specialist. The treatment may involve combining restorative dentistry, endodontics and periodontics so that the teeth are retained in whole or in part. Such teeth can be useful as independent units of mastication or as abutments in simple fixed bridges. Continued periodontal breakdown may lead to total loss of tooth unless these defects can be repaired or eliminated and health of the tissues restored. Thus tooth separation and resection procedures are used to preserve as much tooth structure as possible rather than sacrificing the whole tooth (1).

The term "tooth resection" denotes the excision and removal of any segment of the tooth or a root with or without its accompanying crown portion. Various resection procedures described are: root amputation, hemisection, radisection and bisection. Bisection or bicuspidization is the separation of mesial and distal roots of mandibular molars along with their coronal portion, where both segments are then retained individually (2,3).

Several authors have listed the following indications and contraindications for bicuspidization (4-8):

Periodontal indications

* Severe bone loss affecting one or more roots untreatable with regenerative procedures

* Class II or III furcation invasions or involvements

* Severe recession or dehiscence of a root

Endodontic or conservative indications

* Inability to successfully treat and fill a canal

*Department of Prosthetic Dentistry, Dental Sciences Center, Gülhane Military Medical Academy

Reprint request: Mehmet Dalkız, Department of Prosthetic Dentistry, Dental Sciences Center, Gülhane Military Medical Academy, Etilik-06018, Ankara, Turkey

E-mail: mdalkiz@yahoo.com

Date submitted: February 21, 2007

Date accepted: May 15, 2007

- * Root fracture or root perforation
 - * Root caries of the furcation area
- Prosthetic indications
- * Severe root proximity inadequate for a proper embrasure space
 - * Root trunk fracture or decay with invasion of the biological width
- General contraindications to periodontal surgery
- * Systemic factors
 - * Poor oral hygiene
- Factors associated with local anatomy
- * Fused roots
 - * Unfavorable tissue architecture
- Endodontic factors
- * Retained roots endodontically untreatable
 - * Excessive endodontic instrumentation of retained roots
 - * Excessive deepening of pulp chamber floor
 - * Severe root resorption
- Restorative factors
- * Internal root decay
 - * Presence of a cemented post in the remaining root
- Strategic considerations
- * Consider adjacent teeth available for conventional prosthetic restoration
 - * Consider removable prosthesis
 - * Consider implants

Advances in dentistry, as well as the increased desire of patients to maintain their dentition, have lead to treatment of teeth that once would have been separated. In order to carry out this present day mandate, periodontally diseased teeth with severe bone loss at furcation area may well be retained by separation of their roots. This article describes a simple procedure for bicuspidization in mandibular molar and its subsequent restoration.

Case Report

A 64-year-old female presented with the complaint of pain of right mandibular first molar with a full metal crown. On examination, the tooth was sensitive to percussion. On probing the area, there was a 7-mm-deep periodontal pocket around the furcation area.

On radiographic examination, severe vertical bone loss was evident at the furcation area. The bony support of both roots was completely intact. But apical lesion was investigated around each root. There was also an apical lesion at the second premolar. After the removal of full metal crown root canal treatments of both second premolar and first molar were finished (Figure 1).

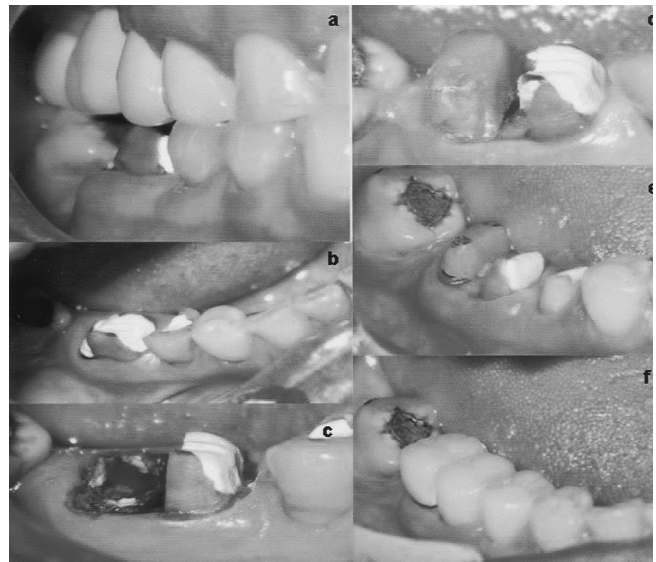


Figure 1. Vertical bone loss around the furcation area is shown by the radiographs. The canals were obturated and the chamber was filled. The tooth was separated. The fixed crown restorations involving each root and mandibular second premolar were cemented

The working canal length was determined and the canals were biomechanically prepared using step back technique. The canals were obturated with lateral condensation method and the chamber was filled with glass-ionomer cement.

Under local anesthesia, the vertical cut method was used to separate the crown. A long shank tapered fissure carbide bur was used to make vertical cut toward the bifurcation area. The distal part of the crown had a severe loss of dentine, then a prefabricated post was inserted and a core was built (Figure 2).

The furcation area was trimmed to ensure that no residual debris were present that could cause further periodontal irritation. Scaling and root planning of the root surfaces, which became accessible on separation was done.

The occlusal table was minimized to redirect the forces along the long axis of each root. After healing of the tissues, a fixed partial denture involving each root and mandibular second premolar was given (Figures 3,4).

Discussion

Another approach to treating a Class III FI of a mandibular molar is called "bisectioning." The clinician splits the mandibular molar vertically through the furcation, without removing either half, leaving two separate roots that then are treated as bicuspid (a procedure termed "bicuspidization"). Farshchian and Kaiser have reported the success of a molar bisection with subse-

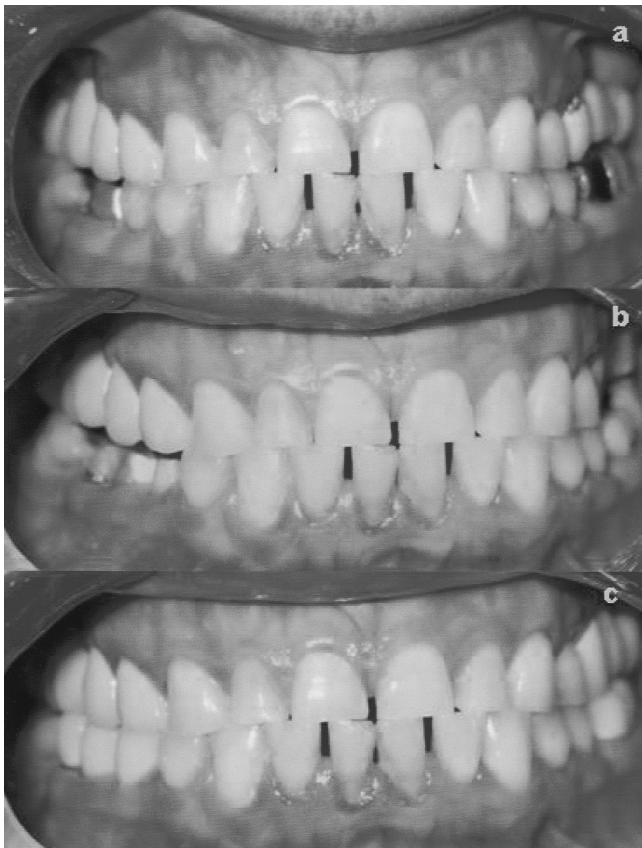


Figure 2. Furcation involvements and clinical procedures are shown at the photographs. Vertical cut at the bifurcation area. Distal part of the crown had a severe dentinal tissue loss. A pre-fabricated post was inserted and a core was built. A final view of the metal ceramic restoration of separated molar and second premolar

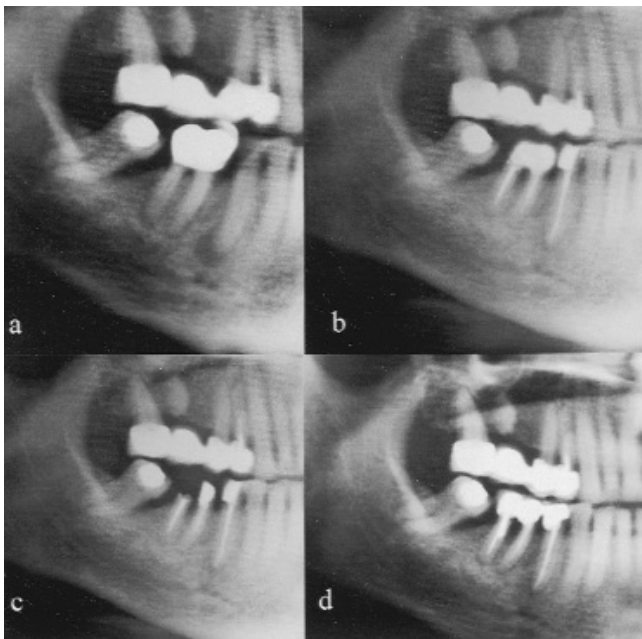


Figure 3a. Buccal view of the prepared roots. **b.** Buccal view of the final restoration. **c.** Occlusal view of the final restoration. **d.** Full view of mandibular model. **e.** Occlusal view of both maxillary and mandibular models

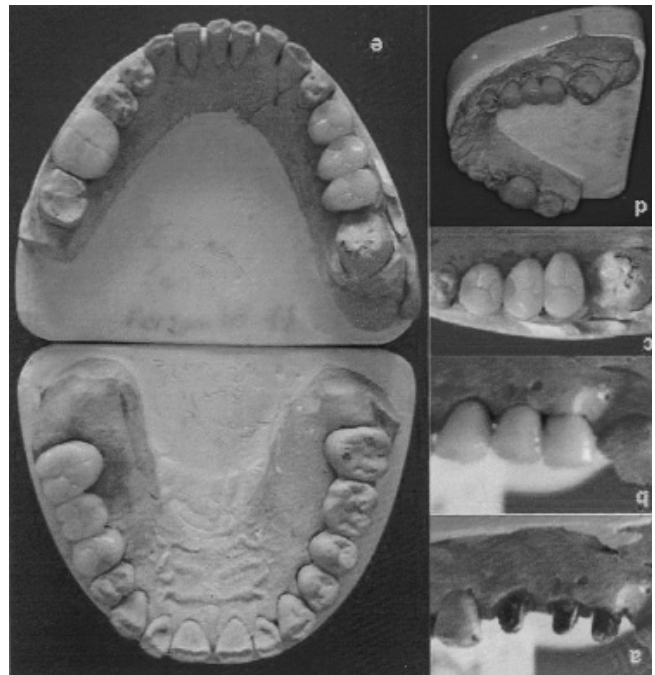


Figure 4. Buccal views of separated right mandibular molar and the final view of restorations

quent bicuspidization (9). They stated that the success of bicuspidization depends on three factors:

1. Stability of, and adequate bone support for, the individual tooth sections
2. Absence of severe root fluting of the distal aspect of the mesial root or mesial aspect of the distal root
3. Adequate separation of the mesial and distal roots, to enable the creation of an acceptable embrasure for effective oral hygiene

According to Newell the advantage of the amputation, hemisection or bisection is the retention of some or the entire tooth (10). However, the disadvantage is that the remaining root or roots must undergo endodontic therapy and the crown must undergo restorative management. The need for endodontic care before root resectioning or sectioning (bisectioning) has a long history in dentistry. It has remained today as a necessity in treating mandibular molars before the partial removal of their roots or separation of their crowns (11). However, failure to perform endodontic treatment first is not a contraindication for root resectioning, if it can be determined that a successful root canal filling is practical and possible (12). It has been shown that vital root resections are possible, especially in the maxilla, with symptoms not being manifested until several weeks after the placement of a sedative dressing of choice (13).

Success of root resection and separation procedures depends, to a large extent, on proper case selection. It is

important to consider the following factors before deciding to undertake any of the root separation and resection procedures.

* Advanced bone loss around furcation area acceptable level of bone around the remaining roots

* Angulations and position of the tooth in the arch. A molar that is buccally, lingually, mesially or distally tilted, can not be separated and resected

* Divergence of the roots - teeth with divergent roots is easier to resect. Closely approximated or fused roots are poor candidates

* Length and curvature of roots - long and straight roots are more favorable for root separation and resection than short, conical roots

* Feasibility of endodontics and restorative dentistry in the root/roots to be retained

Root separation or resection has been used successfully to retain teeth with furcation involvement. However, there are few disadvantages associated with it. As with any surgical procedure, it can cause pain and anxiety. Root surfaces that are reshaped by grinding in the furcation or at the site of hemisection are more susceptible to caries. Often a favorable result may be negated by decay after treatment. Failure of endodontic therapy due to any reason will cause failure of the procedure. In addition, when the tooth has lost part of its root support, it will require a restoration to permit it to function independently or to serve as an abutment for a splint or bridge. Unfortunately, a restoration can contribute to periodontal destruction, if the margins are defective or if non-occlusal surfaces do not have physiologic form. Also, an improperly shaped occlusal contact area may convert acceptable forces into destructive forces and predispose the tooth to trauma from occlusion and ultimate failure of root separation and resection (14,15).

In the case reported, various aspects of occlusal function such as location and size of contacts and the steepness of cuspal inclines may have played a significant role in causing mobility before treatment. During treatment, occlusal contacts were reduced in size and repositioned more favorably. Lateral forces were reduced by making cuspal inclines less steep and eliminating balancing incline contacts.

The prognosis for root separation or resection is the same as for routine endodontic procedures provided that case selection has been performed correctly and the

restoration is of an acceptable design relative to the occlusal and periodontal needs of the patient. Root separation and resection should be considered as other treatment options for the dental surgeons, determined to retain and not remove the natural teeth. With recent refinements in endodontics, periodontics and restorative dentistry, root separation and resection have received acceptance as a conservative and dependable dental treatment and teeth so treated have endured the demands of function.

References

1. Vandersall DC, Detamore RJ. The mandibular molar Class III furcation invasion. A review of treatment options. *JADA* 2002; 133: 55-60.
2. Tarnow D, Fletcher P. Classification of the vertical component of furcation involvement. *J Periodontol* 1984; 55: 283-284.
3. Waerhaug J. The furcation problem: etiology, pathogenesis, diagnosis, therapy and prognosis. *J Clin Periodontol* 1980; 7: 73-95.
4. Parmar G, Vashi P. Hemisection: a case-report and review. *Endontology* 2003; 15: 26-29.
5. Saxe SR, Carman DK. Removal or retention of molar teeth: the problem of the furcation. *Dent Clin North Am* 1969; 13: 783-790.
6. Gantes BG, Synowski BN, Garrett S, Egelberg JH. Treatment of periodontal furcation defects: mandibular Class III defects. *J Periodontol* 1991; 62: 361-365.
7. Lindhe JK. *Clinical Periodontology and Implant Dentistry*. 4th ed. Oxford: Blackwell Publishing Ltd, 2003: 705-730.
8. Ross IF, Thompson RH. A long term study of root retention in the treatment of maxillary molars with furcation involvement. *J Periodontol* 49: 238-244.
9. Farshchian F, Kaiser DA. Restoration of the split molar: bicuspidization. *Am J Dent* 1988; 1: 21-22.
10. Newell DH. The role of the prosthodontist in restoring rootresected molars: a study of 70 molar root resections. *J Prosthet Dent* 1991; 65: 7-15.
11. Gerstein KA. The role of vital root resection in periodontics. *J Periodontol* 1977; 48: 478-483.
12. Highfield JE. Periodontal treatment of multirrooted teeth. *Aust Dent J* 1978; 23: 91-98.
13. Smukler H, Tagger M. Vital root amputation: a clinical and histological study. *J Periodontol* 1976; 47: 324-330.
14. Garrett S, Gantes B, Zimmerman G, Egelberg J. Treatment of mandibular Class III periodontal furcation defects: coronally positioned flaps with and without expanded polytetrafluoroethylene membranes. *J Periodontol* 1994; 65: 592-597.
15. Detamore RJ. Ten-year report of a bifurcated mandibular first molar. *J Ind Dent Assoc* 1983; 62: 17-18.