

Coexistence of pulmonary hydatid cyst and tuberculosis in a patient: a case report

Orhan Yücel (*), Sezai Çubuk (*), Ali Fuat Çiçek (**), Onur Genç (*), Ömer Deniz (***)

SUMMARY

In this article, we report a patient with pulmonary hydatid cysts with coexisting tuberculosis and review the literature. A 21-year-old male was admitted to our department with a history of pulmonary hydatid cysts. In further investigation of the pulmonary lesions, computed tomography of the chest showed bilateral pulmonary multinodular lesions. Open lung biopsy was performed, and histopathological examination revealed pulmonary hydatid cysts and pulmonary tuberculosis. Postoperative course was uneventful and he was discharged with anti-tuberculosis treatment. This case emphasizes the importance of considering the coexistence of echinococcosis and tuberculosis in endemic areas.

Key words: Pulmonary hydatid cyst, pulmonary tuberculosis, thoracic hydatid cyst

ÖZET

Akciğer kist hidatik ve tüberkülozunun birlikte görüldüğü bir hasta: olgu sunumu

Çalışmamızda, pulmoner kist hidatiğe eş zamanlı eşlik eden pulmoner tüberkülozlu bir olgu sunulmuş ve literatür bilgileri gözden geçirilmiştir. Yirmi bir yaşında erkek hasta, pulmoner kist hidatik öyküsüyle kliniğimize başvurdu. Pulmoner lezyonların toraks bilgisayarlı tomografi ile ileri incelemesinde bilateral pulmoner multinodüler lezyonlar saptandı. Açık akciğer biyopsisi uygulandı ve histopatolojik inceleme pulmoner kist hidatik ve tüberküloz varlığını gösterdi. Postoperatif dönemde komplikasyon gelişmeyen olgu, anti-tüberküloz tedaviyle taburcu edildi. Bu olgu endemik bölgelerde ekino-kokkozis ve tüberküloz birlikteliğinin görülebileceğini göstermesi açısından önemlidir.

Anahtar kelimeler: Akciğer kist hidatiği, akciğer tüberkülozu, torasik kist hidatik

Introduction

The most common causes of pulmonary hydatid cysts and tuberculosis are echinococcus granulosus and mycobacterium tuberculosis, respectively (1,2). Pulmonary hydatid cyst with tuberculosis is very rare (1). Pulmonary hydatid cyst has an important differential diagnosis from other diseases in areas where echinococcosis is endemic, such as Asia, North Africa and the Middle East (1-3). While searching this coexistence, we found that only a few cases have been reported. In this article, we report a patient with pulmonary hydatid cysts with coexisting tuberculosis, and review the literature.

Case Report

A 21-year-old male was admitted to our department with a history of pulmonary hydatid cysts. In the last year before admission, he had been diagnosed by a transthoracic fine needle biopsy (TTFNB) and treated with a 6-month course of albendazol (800 mg/day). After this treatment, the course of the patient did not regress clinically and radiologically. The patient presented with cough, fever and hemoptysis. The sputum microscopy and cultures for acid-fast bacilli were negative 4 times. ELISA test was positive. The chest radiograph revealed bilateral pulmonary multinodular lesions. For further investigation of the lesions, computed tomography (CT) of the chest was ordered, which showed bilateral pulmonary multinodular lesions (Figure 1).

This kind of lesions is unexpected for pulmonary hydatid cysts. So we thought that he was misdiagnosed or he had another disease. Then, TTFNB was performed. Histopathological diagnosis was not achieved. The fiberoptic bronchoscopic examination was normal. Hydatid cyst indirect hemagglutination titration was 220 (normal range: 1/100). Open lung biopsy was performed, and histopathological exami-

* Department of Thoracic Surgery, Gulhane Military Medical Faculty

** Department of Pathology, Gulhane Military Medical Faculty

*** Department of Chest Diseases, Gulhane Military Medical Faculty

Reprint request: Dr. Orhan Yücel, Department of Thoracic Surgery, Gulhane Military Medical Faculty, Ankara, Turkey

E-mail: orhanyucel@gmail.com

Date submitted: March 07, 2008 • **Date accepted:** May 27, 2008

nation revealed pulmonary hydatid cysts and pulmonary tuberculosis (Figure 2).

Postoperative course was uneventful and he was discharged with anti-tuberculosis treatment. Anti-tuberculosis treatment including isoniazid, rifampicin, pyrazinamide and ethambutol was given. Albendazole was not added because he received hydatid cyst therapy. The patient showed clinical improvement after 6 months of anti-tuberculosis treatment, and was well after a 12-month follow-up.

Discussion

The pulmonary parenchyma may be affected by a great number of parasites and infectious diseases (1,4). The most common parasitary disease, known as hydatidosis, has been acknowledged as a clinical entity since ancient times (4). Hydatidosis remains as a significant health problem in endemic areas (2,3). In addition, the more significant pulmonary parenchymal infectious disease is tuberculosis (5). Pulmonary hydatid cyst and tuberculosis have an important differential diagnosis from other diseases as they increase the risk of morbidity and mortality (3,6,7). Delays in the diagnosis of tuberculosis and hydatidosis may result in increased morbidity and mortality (3,7,8). Patients without respiratory symptoms are misdiagnosed more frequently than those with symptoms. Hino et al. have aimed to describe tuberculosis-related mortality in Brazil. This study has shown that deaths are related to late diagnosis (7). In our case, the reasons of delay in diagnosis were unexpected finding of chest radiography and thoracic computed tomography, atypical presentations and negative acid-fast smears culture results. Improved clinical acumen and

development of rapid diagnostic tests are desirable to control pulmonary tuberculosis.

Diagnosis of pulmonary hydatidosis is usually based on chest radiography, ultrasonography and computed tomography scan, and immune diagnosis may help in suspicious cases (2,4). Diagnosis of an intact hydatid cyst is usually based on a suspicion resulting from an unexpected finding on routine chest radiographs (2,3). Radiographically the hydatid cyst appears as a homogeneous spherical opacity with definite edges (2). The radiologic picture depends mainly on the size and location of the cyst (2,3). A small cyst may appear as a small "vesicle" and is difficult to recognize until it grows large enough to present a clear image on the chest radiograph (6). The presence of hydatid disease should be considered in a patient who presents with a well-explained spherical density of the lung, particularly in a patient who has been living in an endemic area (2,6). On the contrary, pulmonary tuberculosis produces a broad spectrum of radiographical appearance (7,9). In our case, the chest radiograph and computed tomography showed bilateral pulmonary multinodular lesions. This kind of lesions is unexpected for pulmonary hydatid cysts. Moreover, after a 6-month albendazol treatment, the patient did not show a clinical and radiological regression. So we thought that he was misdiagnosed or he had another disease.

Pulmonary hydatid cyst has no characteristic symptoms (2). The clinical manifestations depend on the site and size of the lesions, whether the cyst is intact or ruptured (2,10). For example small and peripherally located lesions are usually asymptomatic, but large central lesions may manifest with symptoms (3,6). Moreover, the clinical manifestations of pulmonary

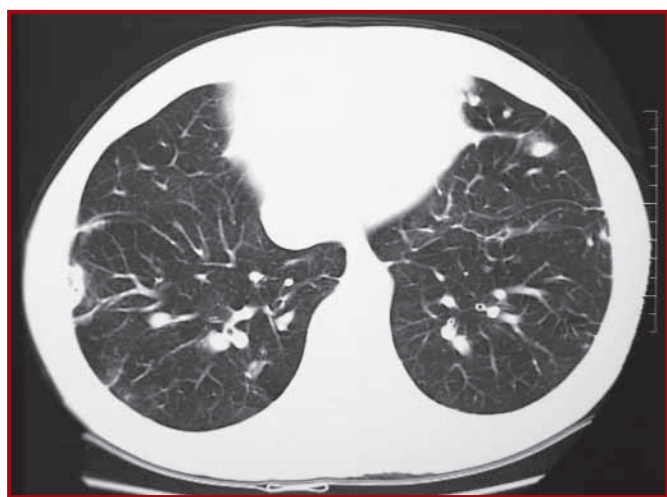

Figure 1. Computed tomography showed bilateral pulmonary multinodular lesions

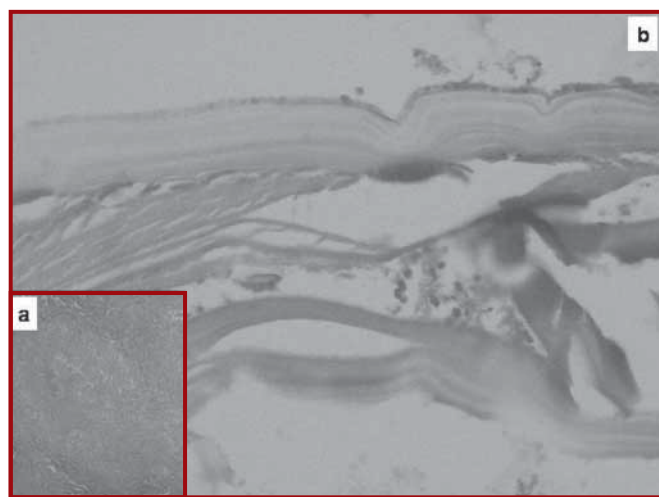


Figure 2. Histopathological examination revealed **a.** granulomatous inflammation, and **b.** germinal membrane (Low magnification-H&E staining)

tuberculosis are highly varied and unspecific, and can be superimposed on that of any other bacterial infection that affects the same organs (5,9). Our case presented with cough, fever and hemoptysis. This type of symptoms is not diagnostic for pulmonary tuberculosis and hydatid cyst.

The laboratory diagnosis of hydatidosis and tuberculosis is complementary to the clinical and radiological methods (1-3). For example, serological tests can be used for diagnosis of pulmonary hydatidosis. These serological tests are Casoni's intradermal test, Weinberg complement fixation test and the indirect hemagglutination test. But these tests have limited value for the exact diagnosis of hydatid disease (2,3). In our case, serological tests assisted to correct diagnosis.

The sputum microscopy and cultures for acid-fast bacilli, ELISA test, TTFNB were performed. Open lung biopsy was performed because histopathological diagnosis was not achieved. Histopathological examination showed pulmonary hydatid cysts and tuberculosis. The clinical manifestations of thoracic tuberculosis are highly varied and unspecific, and can be superimposed on that of any other bacterial infection that affects the same organs.

The treatment of pulmonary hydatid cyst is essentially surgical (11,12). Numerous researchers prefer lung-sparing operations such as enucleation of the cyst or pericystectomy with closing of the bronchial openings with or without capitonnage of the pericystic space as a first choice of treatment (2,6,11). Surgery is essential in most cases, but it must be conservative (2,4). It was advised to use medical treatment postoperatively for complicated hydatidosis and for the treatment of patients with inoperable cysts (2,8). Complicated hydatidosis, disseminated hydatidosis disease, is difficult for surgical treatment (2). In our experience, medical treatment is useful when operation is contraindicated or if there is a risk of dissemination at operation. In our case, albendazol treatment had been given 6 months before the operation. Then, anti-tuberculosis treatment was given in the postoperative course. The patient demonstrated clinical improvement after 8 months of anti-tuberculosis treatment.

Hydatid disease, as well as tuberculosis, is still prevalent in Turkey (11,13). Our case presents that a patient may have pulmonary hydatid cysts with co-

existing tuberculosis. Hydatid cyst with pulmonary tuberculosis increases the risk of morbidity and mortality (14). This case emphasizes the importance of suspicion in concomitant disease in endemic areas for echinococcosis and tuberculosis.

References

1. Chauhan MS, Rajan RS, Gopinathan VP, Jayaswal R. Pulmonary hydatid disease associated with pulmonary tuberculosis. *Indian J Chest Dis Allied Sci* 1986; 28: 88-91.
2. Dakak M, Genc O, Gürkük S, Gözübüyük S, Balkanlı S. Surgical treatment for pulmonary hydatidosis (a review of 422 cases). *J R Coll Edinb* 2002; 47: 689-692.
3. Dogan R, Yuksel M, Cetin G, et al. Surgical treatment of hydatid cysts of the lung: report on 1055 patients. *Thorax* 1998; 44: 192-199.
4. Tarek K, Sadok H. Pulmonary hydatid and other lung parasitic infections. *Curr Opin Pulm Med* 2002; 8: 218-223.
5. Pomerantz BJ, Cleveland JC, Olson HK, Pomerantz M. Pulmonary resection for multi-drug resistant tuberculosis. *J Thorac Cardiovasc Surg* 2001; 121: 448-453.
6. Gozubuyuk A, Savasoz B, Gurkok S, et al. Unusually located thoracic hydatid cysts. *Ann Saudi Med* 2007; 27: 36-39.
7. Hino P, Costa-Júnior ML, Sasaki CM, Oliveira MF, Villa TC, Santos CB. Time series of tuberculosis mortality in Brazil (1980-2001). *Rev Lat Am Enfermagem* 2007; 15: 936-941.
8. Mawhorter S, Temeck B, Chang R, Pass H, Nash T. Nonsurgical therapy for pulmonary hydatid cyst disease. *Chest* 1997; 112: 1432-1436.
9. Dominguez DVF, Fernandez B, Perez LCM, Marin B, Bermejo C. Clinical manifestations and radiology of thoracic tuberculosis. *An Sist Sanit Navar* 2007; 30 (Suppl 2): 33-48.
10. Kuzucu A, Soysal Ö, Özgel M, Yologlu S. Complicated hydatid cysts of the lung: clinical and therapeutic issues. *Ann Thorac Surg* 2004; 77: 1200-1204.
11. Yalcinkaya I, Er M, Ozbay B, Ugras S. Surgical treatment of hydatid cyst of the lung: review of 30 cases. *Eur Respir J* 1999; 13: 441-444.
12. Hijazi MH, Al-Ansari MA. Pulmonary hydatid cyst in a pregnant patient causing acute respiratory failure. *Ann Thorac Med* 2007; 2: 66-68.
13. Akçay A, Özdemir Ö, Gürses D, Ergin H, Kiliç İ, Sarioğlu-Büke A. Üç olgu nedeniyle akciğer kist hidatiğine yeniden bakış. *Düzce Tıp Fakültesi Dergisi* 2003; 3: 29-31.
14. Singh P. Pulmonary hydatid disease associated with pulmonary tuberculosis. *Indian J Chest Dis Allied Sci* 1987; 29: 238.