

The effect of somatostatin in the treatment of neoplastic chylothorax

Orhan Yücel (*), Alper Gözübüyük (*), Sedat Gürkök (*), Ersin Sapmaz (*), Mustafa Öztürk (**), Onur Genç (*)

SUMMARY

Chylothorax is the accumulation of lymphatic fluid within the pleural space. Chylothorax can occur in various clinical settings and arise from diverse causes. The optimal management of the patients with chylothorax is still uncertain. Treatment of chylothorax can be divided into conservative therapy, operative therapy and radiation therapy. Recent reports have suggested that octreotide, by value of its direct action on lymphatic flow, has been useful in resolution of neoplastic chylothorax in the adult population. We herein report prompt cessation of lymphorrhoea in an adult patient with chylothorax using octreotide, a long-acting somatostatin analog.

Key words: Chylothorax, neoplastic chylothorax, octreotide, somatostatin

ÖZET

Neoplastik şilotoraksın tedavisinde somatostatinin etkisi

Şilotoraks lenfoid sıvının plevral boşlukta toplanmasıdır. Şilotoraks çok çeşitli nedenlere bağlı olarak değişik klinik tablolarda ortaya çıkabilir. Şilotorakslı hastaların ideal tedavisi tam olarak belirgin değildir. Şilotoraks tedavisi konservatif tedavi, cerrahi tedavi ve radyoterapi olarak ayrılabilir. Son yıllar oktreotidin, lenfatik akım üzerine olan direkt etkisi yoluyla erişkinlerde malign şilotoraksın rezolüsyonuna yardımcı olduğunu iddia etmektedir. Biz bu yazıda şilotorakslı erişkin bir hastada uzun etkili bir somatostatin analogu olan oktreotid ile lenforenin hızla tedavi edilmesini sunuyoruz.

Anahtar kelimeler: Şilotoraks, neoplastik şilotoraks, oktreotid, somatostatin

Introduction

Chylothorax is the accumulation of lymphatic fluid within the pleural space. Chylothorax can occur in various clinical settings and arise from diverse causes. Tumor has been the most common cause of the series and responsible for approximately one half of the cases (1,2). Chylous leakage can result from either a rupture of the duct secondary to back pressure or direct tumor invasion of the duct (2). Traditionally, lymphoma accounted for approximately three fourth of the tumor group, with bronchogenic carcinoma and other tumors making up the remainder (2).

The ideal management of the patient with chylothorax is still uncertain. Treatment of chylothorax can be divided into conservative therapy, operative therapy, and radiation therapy (1,2). Conservative therapy consists of maintaining; use of a low high protein diet, supplemented with medium chain triglycerides or total parenteral nutrition combined with effective pleural drainage to provide the expansion of the lung (2,3). Recent reports have suggested that octreotide, by value of its direct action on lymphatic flow, has been useful in resolution of neoplastic chylothorax in the adult population (4). We herein report prompt cessation of lymphorrhoea in an adult patient with chylothorax using octreotide, a long-acting somatostatin analog.

Case Report

A 50-year-old woman was diagnosed to have non-Hodgkin lymphoma three years ago by bone marrow examination. First complete remission was achieved after the use of 6 cycles of CHOP (Cyclophosphamide, doxorubicin, vincristine, prednisolone) and radiotherapy to the lumbar region for her multiple vertebral hipodens lesions. Due to high International Prognostic Index (IPI) score, autologous stem cell transplantation (ASCT) was planned. She was given two cycles of ICE (Ifosfamid, carbopla-

* Department of Thoracic Surgery, Gulhane Military Medical Faculty

**Department of Medical Oncology, Gulhane Military Medical Faculty

Reprint request: Dr. Orhan Yücel, Department of Thoracic Surgery, Gulhane Military Medical Faculty, Etlik-06018, Ankara Turkey

E-mail: orhanyuc@gmail.com

Date submitted: February 08, 2008 • **Date accepted:** October 10, 2008

tin and etoposid) and as conditioning regimen BEAM (BCNU, etoposid, cytarabine, and melphelan) was performed. After completion of ASCT she was followed for 3 years without any complaint. She presented with cough, dypnea, weakness, chest and back pain. Physical findings showed the absence of breath sounds and dullness of percussion on the right chest. Thorax computed tomography (CT) revealed pleural effusion in the right hemithorax without significant mass in the pulmonary parenchyma. She admitted to hospital for pleural effusion. Laboratory tests on admission revealed a hemoglobin level of 12.4 gr/dl and a serum albumin level of 3.5 gr/dl. Thoracentesis was performed. Pleural culture revealed no growth of any bacteria. Biochemical analysis of the chest fluid showed levels of cholesterol 44 mg/dl, LDH 165 U/L and triglycerides 159 mg/dl. Cytologic smear of the pleural fluid did not show any malignancy. Because of laboratory and clinical findings diagnosis of pleural chylothorax was made. Chest tube drainage was placed (after two days of admission) and tube drainage was followed (color, characteristics, volume, etc.). Oral intake was withheld from the 2nd to 10th days of hospitalization, and she was given parenteral nutrition. Octreotide (0.1 mg/sc, tid) treatment was started on the postoperative 4th day. The chylous chest drainage decreased with the octreotide treatment on the first day and just a little days later. In addition, talc pleurodesis treatment was performed for recurrent pleural effusion (5th day). Octreotide treatment was continued for a total of five days. Later, chest tube was removed on the postoperative 9th day. The patient was well after the successful period of treatment and the control chest roentgenogram improved. The summary of the treatment stages of malign chylothorax is shown in Figure 1.

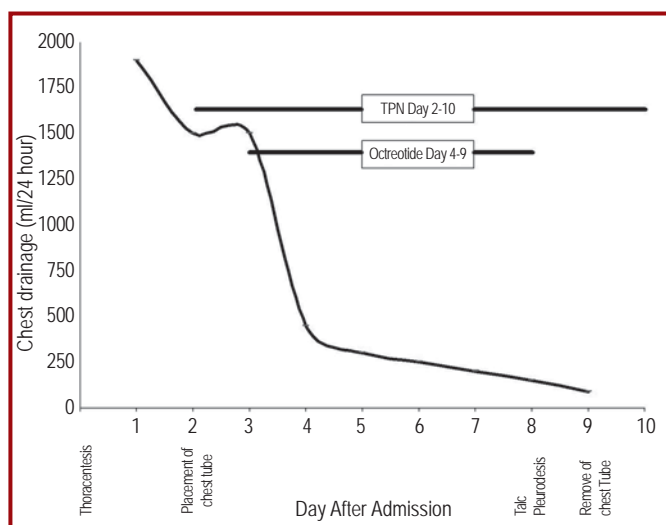


Figure 1. The treatment stages of malign chylothorax

Discussion

Chylothorax, accumulation of a milky white fluid from a pleural space, usually results from either a rupture of the duct secondary to back pressure or direct tumor invasion of the thoracic duct. More than 50% of chylothorax is due to malignancy, and lymphoma accounts for 75%, followed by lung carcinoma (5). Management of chylothorax includes treatment of the underlying disease associated with other conservative measures, such as drainage of pleural effusion, maintenance of nutritional condition, operative therapy and radiation therapy (1). Surgical therapy is proposed in selected cases when conservative treatments fail. Octreotide, which is an analog of somatostatin has been preferred in the treatment of neoplastic chylothorax for 15 years (4). The mechanism of action of somatostatin in chylothorax remains uncertain (6). Somatostatin causes mild vasoconstriction of splanchnic vessels and reduces gastric, pancreatic and intestinal secretions as well as intestinal absorption and hepatic venous flow, which collectively may act in concert to reduce chyle flow. As a result somatostatin reduces the thoracic duct flow and its triglyceride level (6). Octreotide is a long acting somatostatin analogue. Octreotide is similar in action to somatostatin, but selectivity is superior and has longer half life (3,6). The use of octreotide as an adjunct to the conservative management of neoplastic chylothorax is a relatively new concept (1,4). The literature does not specifically address the dose of octreotide in neoplastic chylothorax in the adult. Recently, octreotide has been successfully utilized in the treatment of neoplastic chylothorax and subcutaneous injection of 0.1 mg every 8 hours as advised by Nicholas et al. (4).

We report an adult patient in whom introduction of somatostatin immediately diminished chyle production. The reported side effects of octreotide are arrhythmia, headache, nausea, vomiting, diarrhea, dizziness, thrombocytopenia, hepatotoxicity, and other reactions (4,6). We did not observe any of these side effects.

We believe that the effectiveness of octreotide therapy cannot prove its safety in only a few cases. However, further controlled studies which contain larger series are required for the confirmation of our result for designation of effectiveness of this agent, the definition of the effective dosage, and the long-term effectiveness of octreotide therapy. Additionally somatostatin therapy has a financial advantage due to the avoidance of an operation and the reduction of hospitalization time. Our case and other reported cases showed acceptable efficacy in the management of neoplastic chylothorax. Further reports and studies assessing octreotide efficacy in the management of chylothorax are warranted.

References

1. Dogan R, Demircin M, Dogan OF, Oç M, Kuzgun E. Effectiveness of somatostatin in the conservative management of chylothorax. *Turk J Pediatr* 2004; 46: 262-264.
2. Joseph I, Miller Jr. Anatomy of the thoracic duct and chylothorax. In: Shields TW (ed). *General Thoracic Surgery*. 4th ed. Vol 1. Malvern: Williams&Wilkins, 1994: 714-722.
3. Dixit M, Dubey A, Gan M, et al. Use of Octreotide in the management of chylothorax – After median sternotomy. *IJTCVS* 2005; 21: 285–286.
4. Demos NJ, Kozel J, Scerbo JE. Somatostatin in the treatment of chylothorax. *Chest* 2001; 119: 964-966.
5. Doerr CH, Allen MS, Nichols FS, Ryu JH. Etiology of chylothorax in 203 patients. *Mayo Clin Proc* 2005; 80: 867-870.
6. Buck ML. Octreotide for the management of chylothorax in infants and children. *Pediatr Pharm* 2004; 10.