

Cystic meningiomas: report of three cases

Selçuk Göçmen (*), Ali Kıvanç Topuz (*), Cem Atabey (*), Göksel Güven (*),
Mehmet Nusret Demircan (*), Ufuk Berber (**)

SUMMARY

Cystic meningioma is rare and accounts for 1.6 to 10% of all types of meningioma. Recognition of the diagnostic features of cystic meningiomas is important, because they may be difficult to differentiate from glial or metastatic tumors with cystic or necrotic changes, neuroblastoma, or hemangioblastoma. Different types of cystic meningiomas have been reported by various authors. We detected type 1 cysts in our first and third cases and a type 2 cyst in the second case according to the Nauta classification. Intratumoral cysts may result from cystic degeneration and ischemic necrosis or hemorrhage within the tumor and may be due to a secretory function of the tumor. Here we report three cases of cystic meningiomas and discuss the characteristics of these lesions with the studies found on Pubmed search.

Key words: *Cyst, magnetic resonance imaging, meningioma, surgery*

ÖZET

Kistik menenjiyomlar: üç olgu sunumu

Kistik menenjiyom nadirdir ve tüm menenjiyomların %1.6 ile %10'unu oluşturur. Kistik menenjiyomların tanınal özelliklerinin bilinmesi önemlidir, çünkü kistik ya da nekrotik değişikliklerle olan glial veya metastatik tümörleri, nöroblastom ya da hemanjiyoblastomlardan ayırt etmek zor olabilir. Çeşitli yazarlar kistik menenjiyomların farklı tiplerini tanımlamışlardır. Nauta sınıflandırmasına göre, birinci ve üçüncü olgularımızda tip 1 kist ve ikinci olguda tip 2 kist tespit ettik. İntratümöral kistler, tümör içerisinde kistik dejenerasyon ve iskemik nekroz veya kanama sonucu oluşabilir ve tümörün bir salgı fonksiyonu sonucu da olabilir. Burada kistik menenjiyomlu üç olgu sunulmuş ve bu lezyonların özellikleri Pubmed araması sonucu bulunan araştırmalarla karşılaştırılarak tartışılmıştır.

Anahtar kelimeler: *Kist, manyetik rezonans görüntüleme, menenjiyom, cerrahi*

Introduction

Cystic meningiomas are uncommon and their incidence has been reported to be 1.6 to 10% in all types of meningiomas (1-6). Cysts are frequently associated with glial or metastatic tumors. Thus, it may be difficult to differentiate them from metastatic neoplasms, hemangioblastomas, neuroblastomas, and glial tumors with cystic components, and histopathological examination will define the diagnosis (6-13). We herein report three cases of cystic meningiomas and discuss the characteristics of these lesions comparing to the articles reached by Pubmed research.

Case Reports

Case 1

A 72-year-old woman was admitted to our clinic for focal seizures. In her neurological examination there were left-sided lower extremity paresis and positive Babinski's sign. Computed tomography (CT) scans showed a large low-density mass in the right posterior frontal region surrounded by a hypodense zone of edema. Gadolinium-enhanced T1-weighted magnetic resonance imaging (MRI) demonstrated a cystic tumor in the parasagittal area and right pontocerebellar meningioma (Figure 1A,B). A craniotomy was performed. Peritumoural cyst was containing xanthochromic fluid, which surrounded the tumor mass, and a soft tumor adjacent to the parasagittal region but not attached to the dura was found. The tumor and cystic wall were completely removed (Figure 1C). Histopathological studies revealed the diagnosis of a meningothelial meningioma. The postoperative course was uneventful and the patient was discharged on the 10th postoperative day. There was no residual tumor or cyst in follow-up period.

Case 2

A 62-year-old woman was admitted with a headache and vertigo. In her neurological examination

* Department of Neurosurgery, Gulhane Military Medical Academy Haydarpaşa Training Hospital, Istanbul, Turkey

**Department of Pathology, Gulhane Military Medical Academy Haydarpaşa Training Hospital, Istanbul, Turkey

Reprint request: Dr. Selçuk Göçmen, Department of Neurosurgery, Gulhane Military Medical Academy Haydarpaşa Training Hospital, Istanbul, Turkey
E-mail: s_gocmen@yahoo.com

Date submitted: December 15, 2010 • **Date accepted:** March 03, 2011

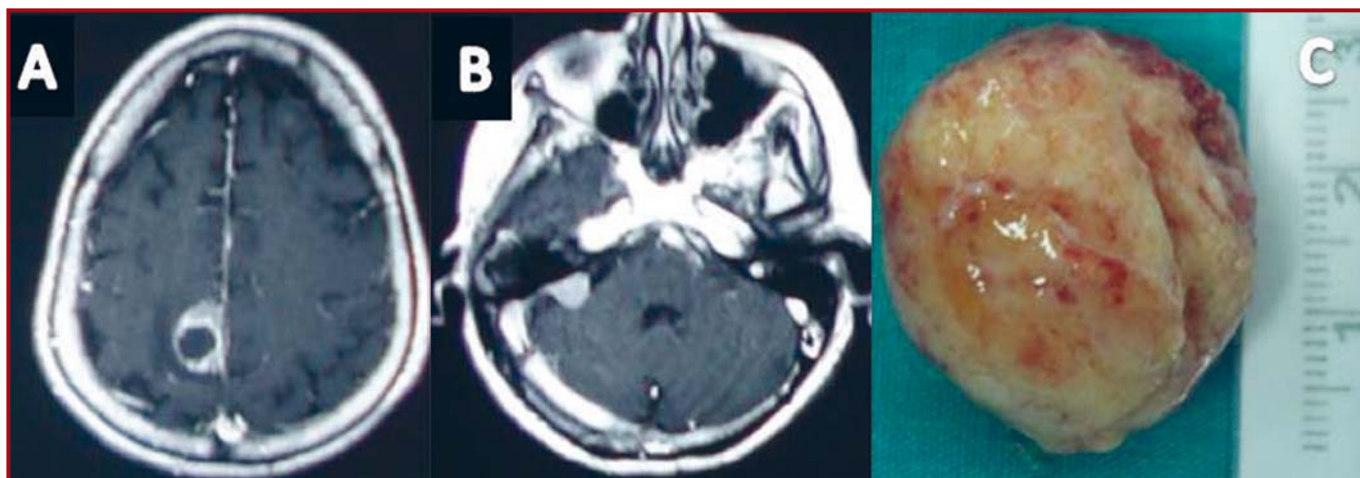


Figure 1. Gadolinium-enhanced T1-weighted magnetic resonance imaging (MRI) of the first case demonstrated a cystic tumor in the parasagittal area (A) and right pontocerebellar meningioma (B). The tumor was seen after completely removed (C)

there was left temporal hemianopsia. CT and MRI studies demonstrated a cystic tumor in the right falx region and left lateral ventricular lesion (Figure 2C). The right occipital lobe was explored with neuronavigation system, and a peritumoral cyst containing xanthochromic fluid, which surrounded the tumor mass was observed. The tumor and the entire cyst wall were completely removed. Histopathological studies revealed the diagnosis of an angiomatous meningioma (Figure 2A,B). After an uneventful post-operative course, the patient was discharged on the 6th post-operative day.

Case 3

The 53-year-old woman presented with a history of headache and dizziness beginning one month before her admission to the hospital. She had previously had a central facial palsy on the right side. The neurologic examination revealed a cerebellar ataxia and sequela of facial palsy. A CT scan demonstrated a cystic tumor in the posterior fossa. MRI showed a homogeneously enhancing solid mass attached to the undersurface of the tentorium with a large cyst with a non-enhancing wall in the cerebellum (Figure 3A,B). This finding strongly suggested a meningioma, but we also considered a malignant tumor. It was attached to the dura and bone, wholly extraaxial, and separated from the surrounding normal cerebellum tissue by a cystic wall. The cyst contained yellowish fluid. The tumor was completely removed with its dural attachment via a suboccipital craniotomy. Histopathological studies showed a meningothelial meningioma. Postoperatively, she made an uneventful recovery. There was no residual tumor or cyst in follow-up contrast enhanced CT scan. The clinical findings are summarized in Table I.

Discussion

Meningiomas are generally solid tumors and the presence of such cystic areas is relatively rare. In fact, so-called cystic meningiomas account for only 2-10% of intracranial meningiomas (1,10,14,15). In 1932, Penfield first described cystic changes in meningioma (16). Fortuna et al. presented the largest series, in which 22 cystic meningiomas out of 1,313 intracranial meningiomas (1.7%) were operated on in a 35-year period (1). Cystic meningiomas are more common in the pediatric age group than in adolescence or adulthood (17). The incidence of cyst formation of meningiomas is especially high in infancy (17). Reports of cystic meningiomas have been more frequent since the advent of CT and MRI scans (18). The use of CT and MRI has greatly improved our ability to locate and identify the tumor with dural attachment, with a histological predictive accuracy approaching 90% (18).

Igaki et al. reported the uncommon late radiation morbidity of cyst formation after stereotactic radiosurgery for meningioma. The rate of this morbidity has been estimated to be 0.7-1.7% in these previous reports. In our cases, none of the cystic meningiomas had previous radiotherapy (19).

Different types of cystic meningiomas have been described. Rengachary et al. recognized two types of cysts within or around the meningioma: intratumoral and extratumoral (20). Subsequently, Nauta et al. classified cystic meningiomas into four types based on location of the cavity and the relationship between the tumor and the surrounding brain: 1) centrally located intratumoral cyst; 2) peripherally located intratumoral cyst, 3) peritumoral cyst in the adjacent parenchyma, and 4) peritumoral cyst between the tumor and the adjacent parenchyma (21). Finally, a fifth type with entrapped cerebrospinal fluid (CSF)

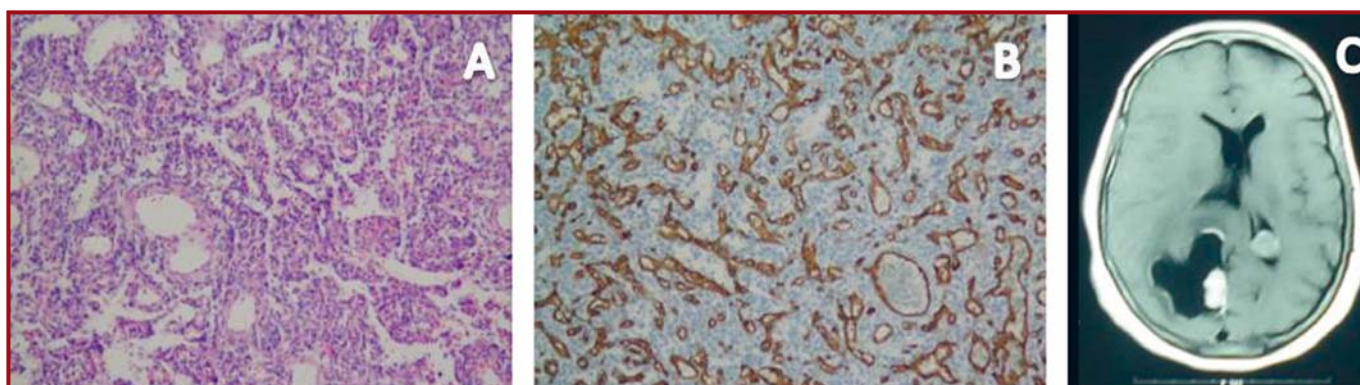


Figure 2. (A) Angiomatous meningioma with abundant stromal hyalinized vessels, HEx20. (B) CD34 immunoreactivity highlights vascular network in angiomatous meningioma, x20. (C) Gadolinium-enhanced T1-weighted MRI showed a cystic tumor in the right falx region and left lateral ventricular lesion in the second case

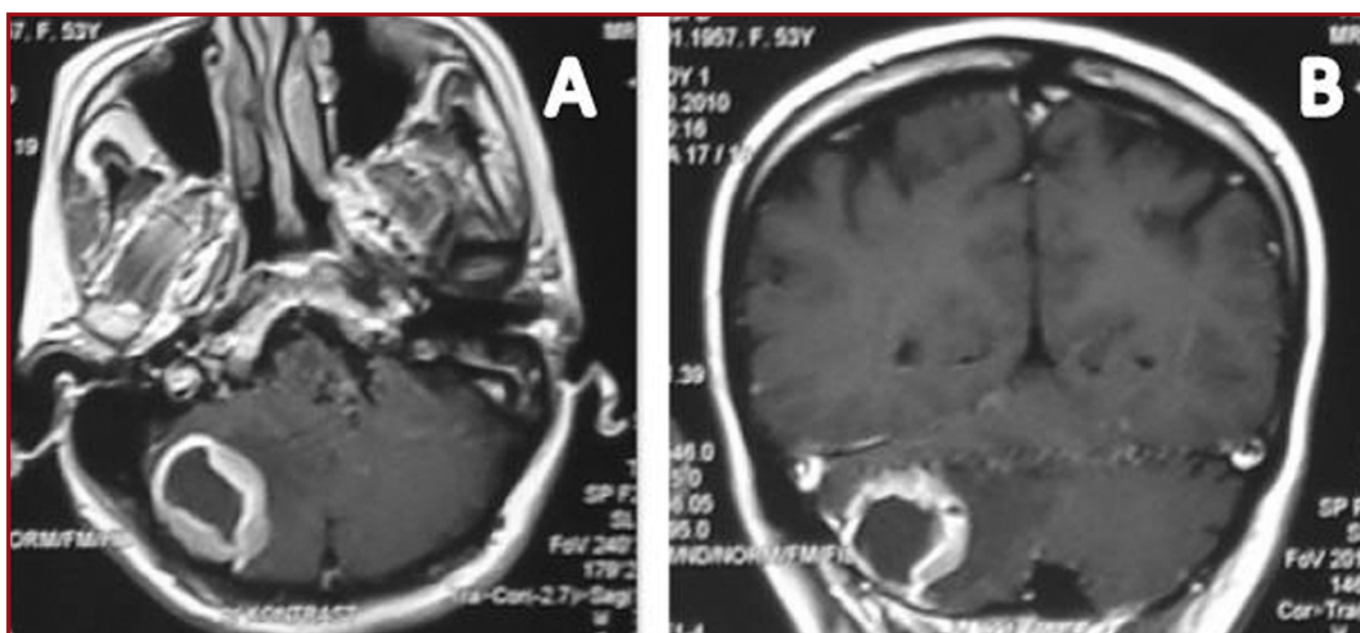


Figure 3. (A,B) Gadolinium-enhanced T1-weighted MRI showed a homogeneously enhancing solid mass attached to the undersurface of the tentorium with a large cyst

was added by Worthington et al. (15). Weber et al. subdivided the peritumoral types: the cyst wall containing tumor cells and without tumor invasion (13). Zee et al. divided cystic meningiomas into three subgroups: intratumoral cysts, peritumoral cysts with the wall enhancing on MRI, and peritumoral cysts with wall not enhancing (6).

Classification of Nauta et al. seem more practical (21). In our series, we detected type 1 cysts in our first and third cases; while a type 2 cyst was detected in the second case according to the Nauta classification.

Pathophysiological mechanisms in the formation of meningioma cysts are discussed by various authors (2,15,16,20,22-24). Penfield et al. have suggested that

Table I. Summary of the characteristics of cystic meningiomas

Case No.	Age (years)/sex	Main complaint	Location	Subtype	Cyst type (21)	Surgery/Fluid	Second lesion
1	72/F	Seizure	Right-parietal/parasagittal	Meningothelial	1	Total removal/xanthochromic	Ponto-cerebellar meningioma
2	62/F	Headache, vertigo	Right occipital/Falx	Angiomatous	2	Total removal/xanthochromic	Lateral ventricular lesion
3	53/F	Headache, dizziness	Right cerebellar	Meningothelial	1	Total removal/xanthochromic	No lesion

cyst formation occurs secondary to central degeneration (16). Cushing has stated that xanthochromic fluid appears to form at the periphery of the tumors where coalescence forms fairly large cavities with no evidence of adjacent tumor degeneration (23). The cyst may produce a mass as large as the meningioma itself (23). In several instances, the expansion of the cyst rather than the tumor is responsible for the increased mass effect and clinical deterioration (23). Fortuna et al. have theorized that intratumoral cysts are the outcome of cystic degeneration or ischemic necrosis or hemorrhage within the tumor and this may be in addition to a secretory function of the tumor (1). The pathophysiological mechanisms in the formation of meningioma cysts are ischemic central necrosis and cystic degeneration, an intratumoral hemorrhage with subsequent cystic/necrotic changes, the active secretion of fluid by functional tumor cells into the tumor, glial proliferation as a response to the presence of a tumor with the elaboration of fluid by glial cells, the evolution of peritumoral edema into a peritumoral cyst, and the loculation of cerebrospinal fluid.

The current World Health Organization (WHO) classifies meningiomas into many different subtypes based on histological parameters. Of these subtypes, transitional, fibroblastic, and meningothelial are the most common ones (27). Most of the meningiomas are benign neoplasms with a WHO grade 1 classification. Approximately 8% of meningiomas are considered "atypical" (WHO grade 2) and tend to have a higher incidence of recurrence (28). Anaplastic meningiomas (WHO grade 3) account for <1% of all meningiomas and have a much shorter mean survival time, with a 5-year-survival rate of approximately 64%, compared with 95% for atypical meningiomas (28). The most frequent location of cystic meningiomas is the cerebral convexity followed by the parasagittal region (2,29). Only 1 to 2% of intracranial meningiomas are located in the lateral ventricles (30).

In our cases, the mean age was 62 years and all patients were female. The presenting clinical symptoms in patients with cystic meningiomas include headaches, seizures, focal neurological deficits, memory loss, dizziness, aphasia, and personality changes. Cerebral angiograms were performed in three patients, particularly for differential diagnosis of hemangioblastoma. Meningotheliomatous meningioma has been reported as the most common histological type, followed by transitional and fibroblastic types. Histopathologically, there were two meningothelial and one angiomatous. One case was in the posterior fossa, one was in the falx region and one was on parasagittal region in our series. The third case is very rare localization of cystic me-

ningioma (31). Second lesions are an extremely rare condition with cystic meningiomas. According to the Pubmed search, all the cystic meningiomas did not have any concomitant lesions.

Recognition of the diagnostic features of cystic meningiomas is important because they may mimic glial or metastatic tumors with cystic or necrotic changes, neuroblastoma, or hemangioblastoma (1,10,11,25). According to Fortuna et al. only 38% of the cases subjected to CT scan were correctly preoperatively diagnosed (1). Coronal CT scans and MRI (sagittal and coronal scans) have proved very useful in displaying the solid enhancing nodule attached to the dura. Multiplanar MRI studies of cystic meningioma have a diagnostic accuracy of 80% (6). Most cystic meningiomas are located at the cerebral convexity, particularly in the frontoparietal region (8). Angiographic findings of meningiomatous vascularization from external carotid arteries can further clarify the preoperative diagnosis (8). MRI scans showed small low signal intensity areas within the mass lesions on T1-weighted images and high signal intensity areas on T2-weighted images. The solid components of the mass lesions showed isointensity, hypointensity, and mixed signal intensity on T1-weighted images and isointensity, hyperintensity, and mixed signal intensity on T2-weighted images. A MRI shows the presence of a dural attachment, extra-axial location, and cerebral edema better than CT. Demonstration of the thickening of the dura (dural tail) with MRI is sometimes a useful clue for the preoperative diagnosis of a cystic meningioma (18). However improved imaging techniques can not eliminate diagnostic confusion between cystic meningiomas and some other intracranial tumors (18).

A total excision of the tumor infiltrating cystic walls is important to prevent a recurrence. Ruelle et al. suggest that tumoral cyst walls are neoplastic but peritumoral cyst walls contain gliotic proliferation (26). Rengachary et al. reported that extratumoral cyst walls consist of brain parenchyma with glial cell proliferation as confirmed by the presence of glial fibrillary acidic protein (20). Umansky et al. recommended total removal of the tumor, including the cyst walls, because complete excision of the cyst walls will minimize the incidence of recurrence of these benign tumors (32). We believe when the solid tumor has no capsule against the cyst, and it is advisable to remove the cyst because it may contain neoplastic cells.

In conclusion, an unusual site, including lateral ventricle, intraparenchymal or in the posterior fossa may be also characteristic of cystic meningiomas. Careful analysis of the imaging studies, primarily MRI, frequently offers additional information, detec-

ting the imaging findings that are suggestive of other disease processes. Cystic meningiomas have a very low incidence and the cyst wall should be completely removed to prevent tumor recurrences.

References

1. Fortuna A, Ferrante L, Acqui M, et al. Cystic meningiomas. *Acta Neurochir (Wien)* 1988; 90: 23-30.
2. De Jesus O, Rifkinson N, Negron B. Cystic meningiomas: a review. *Neurosurgery* 1995; 36: 489-492.
3. Kulah A, Ilcayto R, Fiskeci C. Cystic meningiomas. *Acta Neurochir (Wien)* 1991; 111: 108-113.
4. Russell EJ, George AE, Kricheff II, et al. Atypical computed tomography features of intracranial meningioma: Radiological-pathological correlation in a series of 131 consecutive cases. *Radiology* 1980; 135: 673-682.
5. Sridhar K, Ravi R, Ramamurthi B, et al. Cystic meningiomas. *Surg Neurol* 1995; 43: 235-239.
6. Zee CS, Chen T, Hinton DR, et al. Magnetic resonance imaging of cystic meningiomas and its surgical implications. *Neurosurgery* 1995; 36: 482-488.
7. Demircan MN, Şekerci Z, Buharalı B, et al. Kistik menengioma. *GATA Bülteni* 1987; 29: 419-426.
8. Carvalho GA, Vorkapic P, Biewener G, et al. Cystic meningiomas resembling glial tumors. *Surg Neurol* 1997; 47: 284-290.
9. Chen TY, Lai PH, Ho JT, et al. Magnetic resonance imaging and diffusion-weighted images of cystic meningioma: correlating with histopathology. *Clin Imaging* 2004; 28: 10-19.
10. Otake G. Cystic meningioma: Report of three patients. *Neurosurgery* 1992; 30: 935-939.
11. Parisi G, Tropea R, Giuffrida S, et al. Cystic meningiomas: Report of seven cases. *J Neurosurg* 1986; 64: 35-38.
12. Wasenko JJ, Hochhauser L, Stopa EG, et al. Cystic meningiomas: MR characteristics and surgical correlations. *AJNR Am J Neuroradiol* 1994; 15: 1959-1965.
13. Weber J, Gassel AM, Hoch A, et al. Intraoperative management of cystic meningiomas. *Neurosurg Rev* 2003; 26: 62-66.
14. Claveria L, Sutton D, Tress BM. The radiological diagnosis of meningiomas, the impact of EMI scanning. *Br J Radiol* 1977; 50: 15-22.
15. Worthington C, Caron JL, Melanson D, et al. Meningioma cysts. *Neurology* 1985; 35: 1720-1724.
16. Penfield W. *Cytology and cellular pathology of the nervous system*. New York: Hoeber, 1932: 955-990.
17. Shimizu K, Furuhashi S, Sasai S, et al. Intracerebral cystic meningioma-case report. *Neurol Med Chir (Tokyo)* 1999; 39: 530-533.
18. Tatlı M, Güzel A, Göksel HM. Cystic meningiomas: Report of three cases. *Turk Neurosurg* 2006; 4: 185-188.
19. Igaki H, Maruyama K, Tago M, et al. Cyst formation after stereotactic radiosurgery for intracranial meningioma. *Stereotact Funct Neurosurg* 2008; 86: 231-236.
20. Rengachary S, Batnitzki S, Kepes JJ, et al. Cystic lesions associated with intracranial meningiomas: report of two cases. *Neurosurgery* 1979; 4: 107-114.
21. Nauta HJW, Tucker WS, Horsey WJ, et al. Xanthochromic cysts associated with meningioma. *J Neurol Neurosurg Psychiatry* 1979; 42: 529-535.
22. Buetow MP, Beutow PC, Smirniotopoulos JG. Typical, atypical, and misleading features in meningioma. *Radiographics* 1991; 11: 1087-1106.
23. Cushing H, Eisenhardt L. *Meningiomas: their classification, regional behavior, life history, and surgical end results*. Springfield: Thomas, 1938: 785.
24. Dell S, Ganti SR, Steinberger A, et al. Cystic meningiomas: A clinicoradiological study. *J Neurosurg* 1982; 57: 8-13.
25. Maiuri F, Benvenuti D, De Simone MR, et al. Cystic lesions associated with meningiomas. *Surg Neurol* 1986; 26: 591-597.
26. Ruelle A, Mariotti E, Boccardo M. "True" cystic meningioma. *J Neurol Neurosurg Psychiatry* 1985; 48: 716-718.
27. Louis DN, Ohgaki H, Wiestler OD, et al. The 2007 WHO classification of tumors of the central nervous system. *Acta Neuropathol* 2007; 114: 97-109.
28. Joseph E, Sandhyamani S, Rao MB, et al. Atypical meningioma: a clinicopathological analysis. *Neurol India* 2000; 48: 338-342.
29. Motomochi M, Makita Y, Nabeshima S, et al. Cystic meningioma. Report of a case and review of literature. *Neurol Med Chir (Tokyo)* 1983; 23: 282-288.
30. Criscuolo GR, Symon L. Intraventricular meningioma. *Acta Neurochir (Wien)* 1986; 83: 83-91.
31. Blangy S, Macrez M, Zamet P, et al. Radiological case of the month. Cystic meningioma of the posterior fossa. *Arch Pediatr* 1995; 2: 183-184.
32. Umansky F, Pappo I, Pizov G, Shalit M. Cystic changes in intracranial meningiomas. A review. *Acta Neurochir (Wien)* 1988; 95: 13-18.